

4-2008

Avoiding bowel toxicity in the treatment of the renal surgical bed

Tanya M. Custer

University of Nebraska Medical Center, tcuster@unmc.edu

Lisa A. Bartenhagen

University of Nebraska Medical Center, labarten@unmc.edu

Tell us how you used this information in this [short survey](#).

Follow this and additional works at: https://digitalcommons.unmc.edu/sahp_rste_pres

Recommended Citation

Custer, Tanya M. and Bartenhagen, Lisa A., "Avoiding bowel toxicity in the treatment of the renal surgical bed" (2008). *Posters and Presentations: Radiation Therapy*. 6.

https://digitalcommons.unmc.edu/sahp_rste_pres/6

This Conference Proceeding is brought to you for free and open access by the Radiation Science Technology Education at DigitalCommons@UNMC. It has been accepted for inclusion in Posters and Presentations: Radiation Therapy by an authorized administrator of DigitalCommons@UNMC. For more information, please contact digitalcommons@unmc.edu.

Avoiding Bowel Toxicity in the Treatment of the Renal Surgical Bed

School of Allied Health Professions, Division of Radiation Science Technology Education

Tanya Custer, MS, R.T.(R)(T), Lisa Bartenhagen, MS, R.T.(R)(T)

Introduction

Renal cell carcinoma (RCC) is the most common cancer associated with the kidney. RCC accounts for approximately 3% of all adult malignancies with the incidence increasing by almost 2% per year.^{1,2} Radical nephrectomy is the standard of treatment for patients with localized disease; however approximately 30% of patients present with metastasis.²

The use of radiation therapy is most often limited to post-operative cases when residual tumor is identified or for symptomatic relief of metastatic disease. Definitive radiation treatment is not commonly indicated due to the low tolerance to radiation of surrounding abdominal structures such as the small bowel, ipsilateral kidney, and spinal cord. For patients diagnosed with left-sided RCC, the main dose limiting structure is the small bowel. The following case study will focus on avoiding bowel toxicity with the use of post-operative radiation therapy for the treatment of a Stage III left-sided renal cell carcinoma.

Bowel Toxicity

Normal tissue tolerance doses to radiation often limit the curability of a malignancy. A tumor lethal dose of radiation cannot be delivered when a critical structure, such as the small bowel, is included in the treatment field.

Small bowel radiation toxicity is characterized by mucosal inflammation and breakdown. Chronic injury includes the development of progressive vascular stenosis and intestinal wall fibrosis.³ Acute and chronic toxicities associated with irradiation of the small bowel are listed in Table 1.^{3,4}

The two most important factors influencing radiation toxicity to the small bowel are the total dose of radiation received and the volume of bowel in the field. Complication rates for critical structures are identified in terms of TD_{5/5}. This represents the Tissue Dose associated with a 5% injury rate within 5 years of radiation treatment. The TD_{5/5} doses for the small bowel are 4500cGy for approximately 400cm² of bowel and 5000cGy when 100cm² of bowel is included in the treatment field.⁵ This correlation shows the importance of conformal radiation techniques.

Acute Effects (6-18 months post RT)	Chronic Effects (18 months- 5 years post RT)
Diarrhea	Bowl Obstruction
Colicky Abdominal Pain	Fistula Formation
Nausea	Perforation
Vomiting	Hemorrhage

Table 1.^{3,4} Possible side effects associated with radiation to the abdomen

Case Description

This case involves a 47-year-old white male who presented with left flank pain, hematuria, and a topical abdominal mass. Computed tomography (CT) revealed a large mass in the left kidney. The patient underwent a left sided nephrectomy which demonstrated clear renal cell carcinoma with sarcomatoid and rhabdoid differentiation. Surgical margins were clear with the exception of evidence of cancerous cells within the actual renal vein. The patient was staged as T3b, NX, M0.

Radiation therapy was recommended. The patient initially underwent CT simulation in the supine position (Figure 1). A significant amount of bowel was noted in the proposed treatment plan. The patient was then repositioned and a CT simulation in the right lateral decubitus position was performed (Figure 2).

The prescription dictated a dose of 4500cGy be delivered at 180cGy/fraction for 25 fractions. A boost field was planned to a dose of 900cGy in 5 fractions for a cumulative dose of 5400cGy. Both fields utilized 23 MV photons.

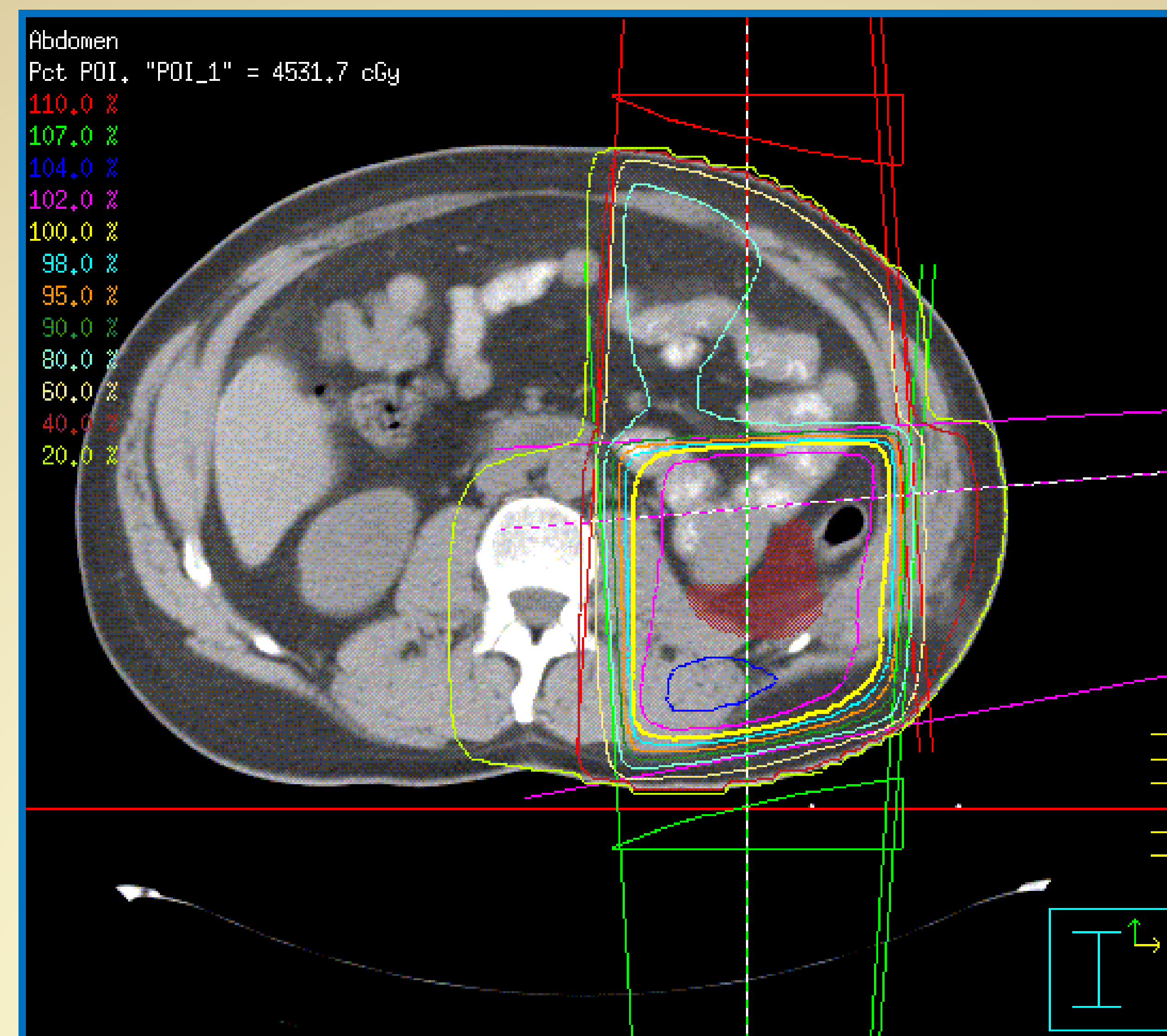


Figure 1. Supine computer plan.

Dose Comparison

On the Supine computer plan, a large volume of small bowel is receiving 80% to 102% of the prescribed dose. This would well exceed the TD_{5/5} limitation.

According to the Decubitus plan, the volume of small bowel included in the field was much less than the supine and the dose was limited to approximately 80% or 4320cGy.

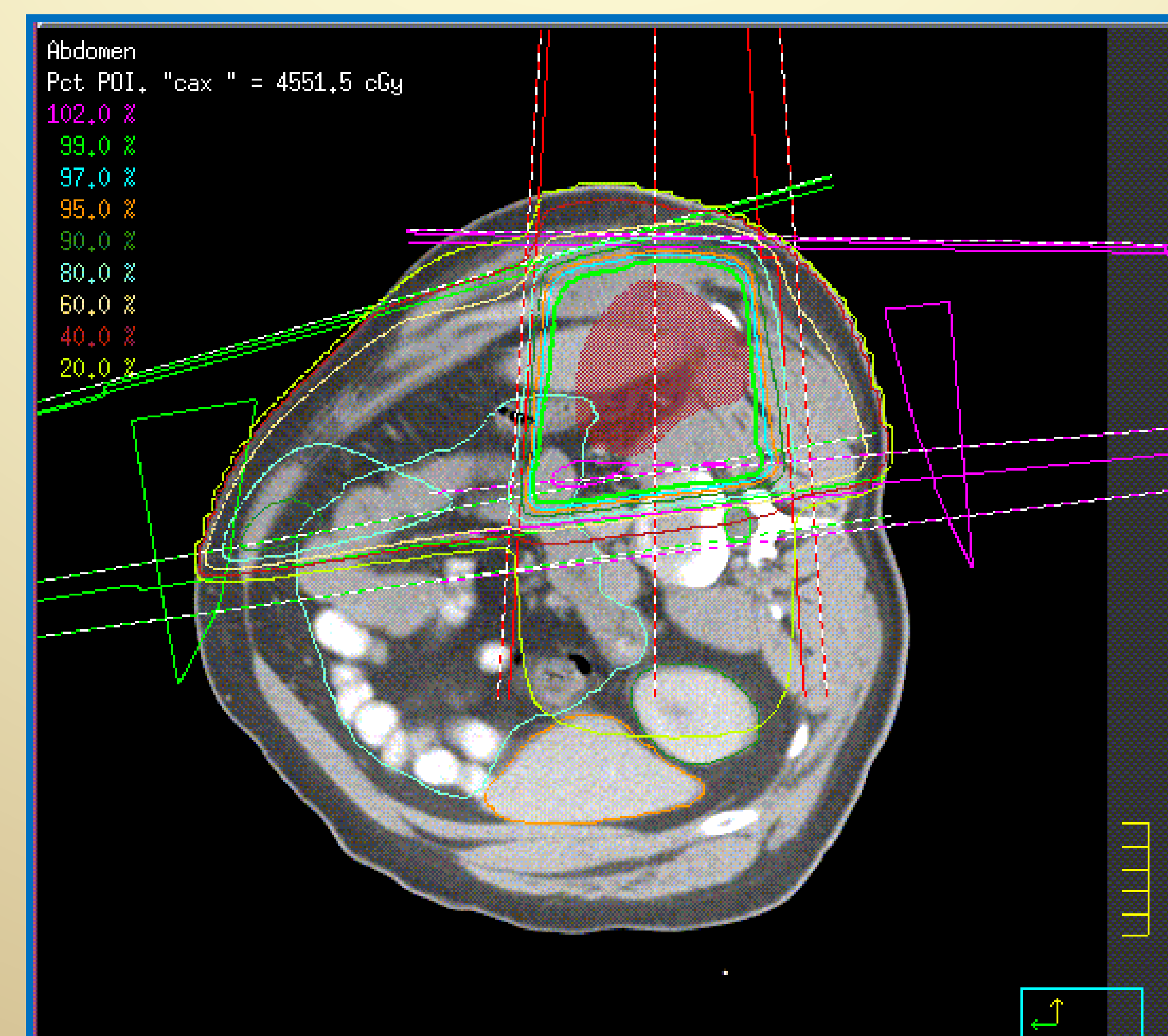


Figure 2. Lt. Lat. Decubitus computer plan.

Conclusion

The standard of care for RCC is surgery; however, with modern treatment techniques and adaptation of dose and treatment volume, complication rates are considerably lower than 5-10% in daily practice and comparable to major abdominal surgery alone.³

Clinical trials including systemic biological agents are underway for the treatment of RCC.¹ These innovative approaches may aid in reducing the need for radiation therapy for advanced RCC and the possible toxicities associated with it to the small bowel.

References

1. Nelson EC, Evans CP, Lara Jr. PN. Renal cell carcinoma: Current status and emerging therapies. *Cancer Treatment Reviews*. 2007;33:299-313.
2. Rathmell WK, Martz CA, Rini BI. Renal cell carcinoma. *Current Opinion in Oncology*. 2007; 19:234-240.
3. Guckenberger M, Jlentje M. Late small bowel toxicity after adjuvant treatment for rectal cancer. *Int J Colorectal Dis*. 2006; 21: 209-220.
4. Andreyev HJN. Gastrointestinal problems after pelvic radiotherapy: The past, the present and the future. *Clinical Oncology*. 2007; 19: 790-799.
5. Hand CM, Ji-Won Kim S, Waldow SM: Overview of radiobiology. In Washington CM, Leaver D, editors: *Principles and Practice of Radiation Therapy*, ed 2, St. Louis, 2004, Mosby.