

Winter 2-11-2014

Prevention of arteriovenous shunt occlusion using microbubble and ultrasound mediated thromboprophylaxis.

Shelby Kutty

University of Nebraska Medical Center, skutty@unmc.edu

Juefei Wu

University of Nebraska Medical Center

James M. Hammel

University of Nebraska Medical Center, jmhammel@unmc.edu

Joseph R. Abraham

University of Nebraska Medical Center

Jeeva Venkataraman

University of Nebraska Medical Center

See next page for additional authors

Tell us how you used this information in this [short survey](#).

Follow this and additional works at: https://digitalcommons.unmc.edu/com_peds_articles



Part of the [Pediatrics Commons](#)

Recommended Citation

Kutty, Shelby; Wu, Juefei; Hammel, James M.; Abraham, Joseph R.; Venkataraman, Jeeva; Abdullah, Ibrahim; Danford, David A.; Radio, Stanley J.; Lof, John; and Porter, Thomas R., "Prevention of arteriovenous shunt occlusion using microbubble and ultrasound mediated thromboprophylaxis." (2014). *Journal Articles: Pediatrics*. 5.

https://digitalcommons.unmc.edu/com_peds_articles/5

This Article is brought to you for free and open access by the Pediatrics at DigitalCommons@UNMC. It has been accepted for inclusion in Journal Articles: Pediatrics by an authorized administrator of DigitalCommons@UNMC. For more information, please contact digitalcommons@unmc.edu.

Authors

Shelby Kutty, Juefei Wu, James M. Hammel, Joseph R. Abraham, Jeeva Venkataraman, Ibrahim Abdullah, David A. Danford, Stanley J. Radio, John Lof, and Thomas R. Porter

Prevention of Arteriovenous Shunt Occlusion Using Microbubble and Ultrasound Mediated Thromboprophylaxis

Shelby Kutty, MD; Juefei Wu, MD, PhD; James M. Hammel, MD; Joseph R. Abraham, BS; Jeeva Venkataraman, BS; Ibrahim Abdullah, MD; David A. Danford, MD; Stanley J. Radio, MD; John Lof, MS; Thomas R. Porter, MD

Background—Palliative shunts in congenital heart disease patients are vulnerable to thrombotic occlusion. High mechanical index (MI) impulses from a modified diagnostic ultrasound (US) transducer during a systemic microbubble (MB) infusion have been used to dissolve intravascular thrombi without anticoagulation, and we sought to determine whether this technique could be used prophylactically to reduce thrombus burden and prevent occlusion of surgically placed extracardiac shunts.

Methods and Results—Heparin-bonded ePTFE tubular vascular shunts of 4 mm×2.5 cm (Propaten; W.L Gore) were surgically placed in 18 pigs: a right-sided side-to-side arteriovenous (AV, carotid-jugular) shunt, and a left-sided arterio-arterial (AA, carotid-carotid) interposition shunt in each animal. After shunt implantation, animals were randomly assigned to one of 3 groups. Transcutaneous, weekly 30-minute treatments (total of 4 treatments) of either guided high MI US+MB (Group 1; n=6) using a 3% MRX-801 MB infusion, or US alone (Group 2; n=6) were given separately to each shunt. The third group of 6 pigs received no treatments. The shunts were explanted after 4 weeks and analyzed by histopathology to quantify luminal thrombus area (mm²) for the length of each shunt. No pigs received antiplatelet agents or anticoagulants during the treatment period. The median overall thrombus burden in the 3 groups for AV shunts was 5.10 mm² compared with 4.05 mm² in AA (*P*=0.199). Group 1 pigs had significantly less thrombus burden in the AV shunts (median 2.5 mm²) compared with Group 2 (median 5.6 mm²) and Group 3 (median 7.5 mm²) pigs (*P*=0.006). No difference in thrombus burden was seen between groups for AA shunts.

Conclusion—Transcutaneous US with intravenous MB is capable of preventing thrombus accumulation in arteriovenous shunts without the need for antiplatelet agents, and may be a method of preventing progressive occlusion of palliative shunts. (*J Am Heart Assoc.* 2014;3:e000689 doi: 10.1161/JAHA.113.000689)

Key Words: pediatric • shunt thrombosis • sonothrombolysis • therapeutic ultrasound

Extracardiac shunts (ECS) are commonly used for the palliation of patients with congenital heart disease (CHD) who are not candidates for early complete repair.^{1–4} There are several forms of CHD where repair must be accomplished in stages.^{2,5} After placement of a palliative ECS, a period of months may be required to achieve sufficient somatic growth, pulmonary artery growth, and fall in pulmonary vascular resistance to allow candidacy for definitive intracardiac repair. During that time, ECS occlusion can cause critical cyanosis

resulting in sudden death.^{6–8} Even partial obstruction of flow is a major cause of mortality and serious morbidity. Clotting factors and platelets used at the time of surgical placement of ECS predispose to early layering of thrombus within the lumen of ECS, which potentially leads to cellular in-growth and a higher propensity toward occlusion. Histopathologic studies have shown that early thrombus deposition may lead to luminal in-growth consisting of fibrous tissue.⁹ In a nonrandomized observational study of infants with systemic to pulmonary ECS, the incidence of shunt compromise was 12% and mortality at 1 year was 26%.⁸ In another study, occlusion >50% was noted in 23% of ECS examined at the time of elective take down.¹⁰ Younger patient age and smaller shunt size are predictors of thrombosis.^{6,11} Efforts to maintain ECS patency have the potential to limit morbidity and mortality in CHD.

Image-guided high mechanical index (MI) impulses from a modified diagnostic ultrasound (US) system during a systemic microbubble (MB) infusion dissolve intravascular thrombi without the need for fibrinolytic therapy.^{12,13} Cavitation and resultant shear forces that lead to a microstreaming phenomenon are proposed mechanisms for sonothrombolysis.^{14,15} Contrast MBs serve as nuclei for cavitation,

From the Division of Pediatric Cardiology, University of Nebraska College of Medicine/Children's Hospital & Medical Center (S.K., J.R.A., J.V., D.A.D.); Division of Cardiovascular Surgery (J.M.H., I.A.), Section of Cardiology, Departments of Internal Medicine (J.W., J.L., T.R.P.), and Pathology and Microbiology (S.J.R.), University of Nebraska Medical Center, Omaha, NE.

Correspondence to: Thomas R. Porter, MD, Division of Cardiology, University of Nebraska Medical Center, 982265 Nebraska Medical Center, Omaha, NE 68198-2265. E-mail: trporter@unmc.edu

Received November 28, 2013; accepted December 20, 2013.

© 2014 The Authors. Published on behalf of the American Heart Association, Inc., by Wiley Blackwell. This is an open access article under the terms of the Creative Commons Attribution-NonCommercial License, which permits use, distribution and reproduction in any medium, provided the original work is properly cited and is not used for commercial purposes.

lowering the peak negative pressure threshold required to induce cavitation, thus enhancing the thrombolytic effects of US. Recently, the effectiveness of MB-enhanced US lysis has been shown in dissolving thrombi that formed on central venous catheters in vivo.^{16,17} However, no studies to date have examined whether this technique could *prevent* thrombus formation in vessels or shunts at higher risk for this. Based on these studies of thrombi dissolution, we hypothesized that the microstreaming induced by MB cavitation may be an effective method to prevent the early thrombus accumulation (thromboprophylaxis) on surgically placed grafts that lead to subsequent intimal hyperplasia within the graft and resultant occlusion. Accordingly, the specific aim of this study was to examine the effectiveness of thromboprophylaxis using US-guided MB treatments in arteriovenous (AV), and arterio-arterial (AA) shunts placed in a porcine model. The success was validated by the examination of histopathology of explanted ECS.

Methods

Porcine Models of Extracardiac Shunts

The study was approved by the Institutional Animal Care and Use Committee of the University of Nebraska Medical Center and was in compliance with the standards in the Guide for the Care and Use of Laboratory Animals. Extracardiac AV and AA shunts were created in the same animal. Each procedure was a survival study and necessitated a sterile field and techniques. The pig was fasted overnight and pre-anesthetized with an intramuscular mixture of telazol (4.4 mg/kg), ketamine (2.2 mg/kg), and xylazine (2.2 mg/kg). Intramuscular atropine (0.05 mg/kg) was used to dry oral-tracheal secretions and prevent bradycardia during intubation. Following placement of a venous line in the lateral or medial auricular vein, the pig was intubated and isoflurane inhalation anesthesia (induction at 4%, maintained at 1.0% to 1.8%) administered. The animal was placed on a ventilator at a volume of 11 cc/kg of air and at a rate of 15 breaths/minute.

Shunt placement was performed via surgical cut-down under full aseptic precautions (JMH). After the pig was placed under anesthesia and after preparation of the surgical site, a midline cervical incision was made. Through the incision, the right and left carotid arteries and jugular veins were circumferentially dissected. Heparin 100 Units/kg was administered and allowed to circulate. Two 4-mm diameter, 2.5 cm long, heparin-bonded expanded polytetrafluoroethylene shunts (Propaten Vascular Graft; Gore Medical) were implanted: one interposition within the left carotid (arterio-arterial, AA), and one side-to-side AV shunt from the right carotid artery to the right internal jugular vein. This shunt type is commonly used in standard of care clinical practice

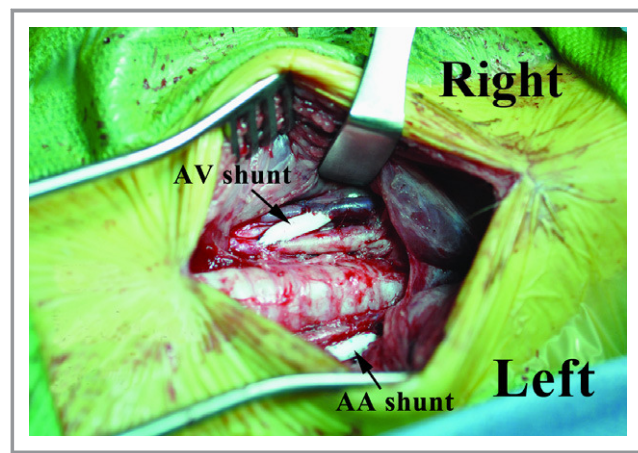


Figure 1. Surgical placement of extracardiac shunts. Representative examples of surgically implanted right-sided arteriovenous (AV) shunt from the right carotid artery to the right internal jugular vein, and left sided arterio-arterial (AA) interposition shunt within the left carotid artery (black arrows).

in humans. For the interposition shunt, each vessel was clamped proximally and distally and a 2.5 cm segment of vessel was excised. Each anastomosis was created with running 6-0 polypropylene suture (Prolene; Ethicon). Both anastomoses were completed before releasing the vessel clamps, ie, the graft was not clamped. For the AV shunt, 4 clamps were applied – to the artery and the vein both proximally and distally – and all were removed when both anastomoses were completed. The grafts were observed until hemostasis, and then the incision was closed with a subcutaneous and a skin suture layer (Figure 1). The animal was recovered from anesthesia with continuous monitoring.

Ultrasound and Microbubble Technology

The lipid-encapsulated MB formulation MRX-801 (NuvOx Pharma) was used. These MB have a diameter of $1.0 \pm 0.1 \mu\text{m}$, and concentration of 1.5 to $3.0 \times 10^{10}/\text{mL}$. The MB infusion was prepared by diluting 2 mL of the MRX-801 in 100 mL of 0.9% saline and infused at a rate of 1.0 mL/min.

A commercially available US system (iE33; Philips Medical Systems) and diagnostic transducer (S5-1; Philips) were used. The US system had low MI contrast sensitive imaging pulse sequences (Power Modulation) that were applied in between high MI impulses to assist in the detection of MB.

Ultrasound and Microbubble Thromboprophylaxis

The 3 randomized groups tested were: (1) 2D intermittent guided high MI with intravenous MB (Group 1); (2) 2D-guided high MI US with intravenous 0.9% saline (Group 2); and (3) controls that received no treatment (Group 3). Randomized transcutaneous treatment Groups (1 or 2) and controls were

assigned immediately after surgical placement of ECS. The first treatment regimen (in Groups 1 and 2) was begun within 2 hours of placement of the ECS, because it is anticipated that this is when significant initial platelet and fibrin deposition occurs. Thirty-minute treatments were given separately to each side (AV shunt on the right side, AA shunt on the left). The MB or 0.9% saline were infused through a peripheral vein. In Group 1, the application of brief high MI impulses (1.1 MI; pulse duration 20 μ s; frame rate 20 Hz) was guided to allow replenishment of MB within the region of interest. Typically, the off time between high MI applications was 2 to 3 seconds. This frequency and pulse duration for therapeutic US application was chosen based on previous in vitro work from our laboratory.¹⁸ Pulmonary hypertension, mediated by the vasoconstrictor thromboxane has been reported in pigs after exposure to intravenous MB.¹⁹ This

reaction is presumed to be secondary to species-related pulmonary intravascular macrophages; the macrophage phagocytotic process resulting in the release of thromboxane causing pulmonary hypertension.²⁰ Ketorolac 60 mg and methylprednisolone 40 mg to prevent pulmonary hypertensive responses to MB were administered intravenously in Groups 1 and 2 prior to each treatment.

The oxygen mixture was kept at 24% during each treatment. Oxygen saturation by pulse oximetry, arterial blood pressure, and 3-lead electrocardiograms were measured before, during, and for 30 minutes after US and MB therapy. The animal was recovered from anesthesia after the treatment and returned to housing. The animal was brought to the laboratory for 3 additional weekly treatments under anesthesia. The shunts were imaged using color Doppler US (4VC1 vascular transducer; Siemens) before and after each treatment (Figure 2).

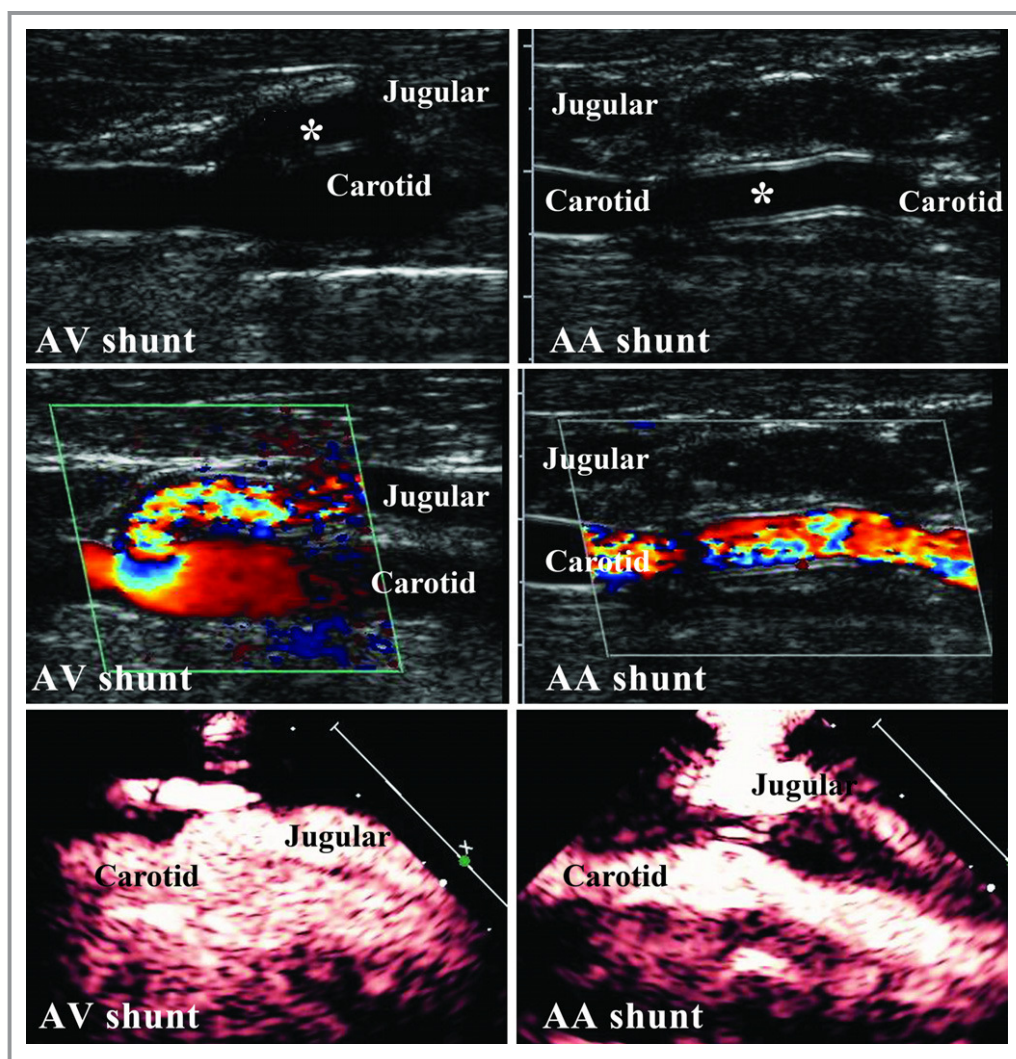


Figure 2. Transcutaneous echocardiographic images of extracardiac shunts. The arteriovenous (left panels) and arterio-arterial (right panels) shunts are demonstrated (asterisks) on 2-dimensional and color Doppler imaging, and during thromboprophylactic application of microbubbles and high mechanical index pulse sequences to insonify each shunt. AA indicates arterio-arterial; AV, arteriovenous.

A single experienced echocardiographer (JW) recorded Doppler data as good, reduced, or absent based on color Doppler information obtained from within the shunt. Settings of low 2-dimensional gain, high color gain, small color overlay, zoom mode, and a single focal zone were used to maximize the sampling rate. As the Doppler angles were inconsistent between the implanted shunts, spectral Doppler velocity data was not obtained.

Explantation of Shunts and Analysis of Thrombus Burden

Each animal was sacrificed at the completion of 4 treatments in Groups 1 and 2, and at a similar time point in Group 3. Each ECS was removed and placed in 10% neutral buffered formalin immediately, and processed according to standard tissue processing techniques. The shunts were embedded in paraffin wax, sectioned, stained with hematoxylin and eosin for microscopy and reviewed by a pathologist (SJR). The separated section of each ECS was cut into 4-micron thick slices. Digital images of each section were taken through the iScan Coreo slide scanner (Ventana Medical Systems Inc) at $\times 20$ magnification. Images of histopathologic sections from the explanted ECS were reviewed by the pathologist (SJR), and under the pathologist's direction, a blinded experienced observer (JRA) performed quantitation of the in-lumen residue in each shunt using Ventana image viewer 3.1 software. The area inside the endothelial cell lining of the tunica intima was included in the measurement. Blood clots, significant vacuoles, and components outside the intima were excluded. Areas calculated for each shunt section were added up to quantify thrombus accumulation (Figure 3).

Statistical Analysis

Mean, standard deviation, median, and ranges were determined for continuous variables. Sample sizes were small and data could not be presumed to have normal distribution. Therefore, median thrombus burden was reported for US with MB, US with saline, and control groups, and the Kruskal-Wallis test was applied to assess differences among these groups. The Student's *t* test was used for comparison of hemodynamic measurements in treatment Groups 1 and 2. To assess the interobserver agreement, histopathologic thrombus burden measurements were repeated in 10 randomly chosen AA and AV shunts by a second blinded observer. Bland-Altman plots were derived to identify possible bias (mean divergence) and the limits of agreement (2 standard deviation of the divergence). A *P* value <0.05 was considered significant. Statistical analysis was performed using commercially available software (Minitab version 16.1; Minitab Inc).

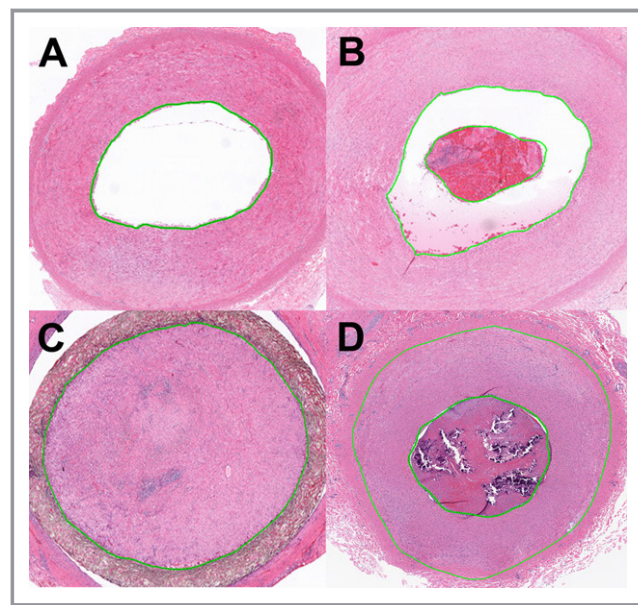


Figure 3. Representative examples of residual thrombi within AV shunt. A, Section of an AV shunt in a Group 1 animal with minimal intimal thickening and no luminal thrombus. B, Section of an AV shunt with a mixture of blood, platelets and fibrin partially occluding its lumen. C and D, Sections of completely occluded AV shunts. The luminal composition was a mixture of platelets and fibrin with some endothelial cell ingrowth. In addition, mononuclear cells, collagen and areas of calcification were seen in some of the sections that were occluded. Green lines indicate software measurement tools for lumen and thrombus. AV indicates arteriovenous.

Results

A total of 18 pigs had a placement of 36 ECS (12 pigs for thromboprophylaxis protocols and 6 controls). The mean animal weight at the time of ECS placement was 37.4 ± 3.4 kg. Table 1 shows the hemodynamic measurements in all animals prior to, during, and after the treatments summarized for all 4 treatments. There were no significant differences in hemodynamic parameters between Groups 1 and 2 with any of the randomized therapies. Color Doppler assessments of the shunts showed reduced or absent color Doppler flow during 5 of 24 treatments in 2 Group 1 pigs: absent flow was noted during 2 treatments in 1 and reduced flow was seen for 3 treatments in the second pig. Among the Group 2 pigs, absent or reduced flow was noted on color Doppler during 8 treatments in 3 animals. These included 6 instances of absent flow in 2 pigs and 2 instances of reduced flow in a third pig. These color Doppler flow changes in both groups were mostly observed during the third and fourth treatments.

Thrombus Accumulation in the Different Treatment Groups

In the untreated animals (Group 3), the median thrombus burden in AV shunts was 5.10 mm^2 compared with 4.05 mm^2

Table 1. Hemodynamic Indices Compared Between Groups 1 and 2 for All Treatments

	Parameter	Group 1: 2D US+MB (n=6 Pigs, 24 Treatments)	Group 2: 2D US (n=6 Pigs, 24 Treatments)	P Value
Before treatments	HR, bpm	86±19	93±19	0.26
	SBP, mm Hg	104±15	101±12	0.56
	DBP, mm Hg	50±12	48±10	0.63
	ACT, s	119±7	115±7	0.16
	SpO ₂ , %	99±2	98±2	0.08
During treatments	HR, bpm	83±15	89±15	0.18
	SBP, mm Hg	108±12	102±13	0.10
	DBP, mm Hg	57±13	52±10	0.17
	SpO ₂ , %	95±3	96±3	0.68
After treatments	HR, bpm	83±16	88±15	0.29
	SBP, mm Hg	113±10	107±10	0.11
	DBP, mm Hg	63±14	57±8	0.19
	ACT, s	117±6	113±7	0.17
	SpO ₂ , %	98±2	99±2	0.46

ACT indicates activated clotting time; DBP, diastolic blood pressure; HR, heart rate; MB, microbubble; SBP, systolic blood pressure; SpO₂, systemic oxygen saturation; US indicates ultrasound.

in AA shunts ($P=0.199$). In the AV shunts, Group 1 had less median thrombus burden (2.5 mm^2) in the AV shunts compared with Group 2 (5.6 mm^2) and Group 3 (7.5 mm^2) pigs ($P=0.006$; Table 2). Among the explanted AV shunts, no total lumen occlusions were observed in Group 1, whereas one AV shunt total occlusion was seen in Groups 2 and 3.

Histopathology of the shunts demonstrated variable degrees of intimal thickening. The luminal composition was predominantly a mixture of organized blood, platelets, and

fibrin; collagen, mononuclear cells, and areas of calcification were also seen in the sections that were occluded (Figure 3). Sections of AV shunt histology in pigs treated with guided US with MBs showed reductions in thrombus formation along the entire circumference of the vessel. No difference in median thrombus burden was seen among the 3 groups for AA shunts (4.05 mm^2 in Group 1, 4.25 mm^2 in Group 2, 4.50 mm^2 in Group 3, $P=0.895$). Bland-Altman analysis showed good interobserver agreement for thrombus burden measurements as represented in Figure 4.

Discussion

Venous and arterial thrombosis is a common complication in patients after repair of CHD. The clinical implications of thrombosis after surgical procedures in CHD, including systemic to pulmonary shunts, bidirectional cavopulmonary shunts, and Fontan palliation are significant.²¹ Thrombotic lumen occlusion is the usual cause for ECS failure²²; this development leads to significant acute mortality and morbidity in CHD.^{6–8} No published randomized controlled trials are available to guide the thromboprophylactic management of patients with ECS,²¹ so use of anticoagulation is a subject of debate. Although antiplatelet therapy has been studied extensively in adults, evidence for its benefit in infants and young children is limited.¹⁰ While the use of aspirin was associated with a reduction in ECS thrombosis in some studies,^{8,23} others have failed to demonstrate a beneficial effect.²⁴ In theory, aspirin alone may be insufficient to prevent arterial thrombosis because it inhibits only one pathway (cyclo-oxygenase) of platelet activation, and would have minimal effect in treating thrombi that would be expected in ECS. Moreover, the optimal pediatric dose of aspirin for inhibition of platelet aggregation is unknown. Aspirin is associated with Reye syndrome in infants and children,²⁵ and

Table 2. Differences in Thrombus Burden for Explanted Shunts Compared Between Groups

Group 1 (n=6) US+MB			Group 2 (n=6) US Alone			Group 3 (n=6) Control		
Thrombus burden in each pig	AA (mm ²)	AV (mm ²)	Thrombus burden in each pig	AA (mm ²)	AV (mm ²)	Thrombus burden in each pig	AA (mm ²)	AV (mm ²)
1	5.0	2.5	1	3.7	5.5	1	3.1	10.2
2	1.4	0.9	2	2.1	2.5	2	5.8	6.9
3	3.4	1.9	3	2.3	8.2	3	3.2	4.4
4	4.4	3.7	4	5.2	4.7	4	2.0	7.1
5	3.7	2.8	5	4.8	5.7	5	12.1	7.9
6	6.2	2.5	6	6.2	10.1	6	8.7	9.5
Median	4.05	2.50	Median	4.25	5.60	Median	4.50	7.50

AA indicates arterio-arterial; AV, arteriovenous; MB, microbubble; US indicates ultrasound.

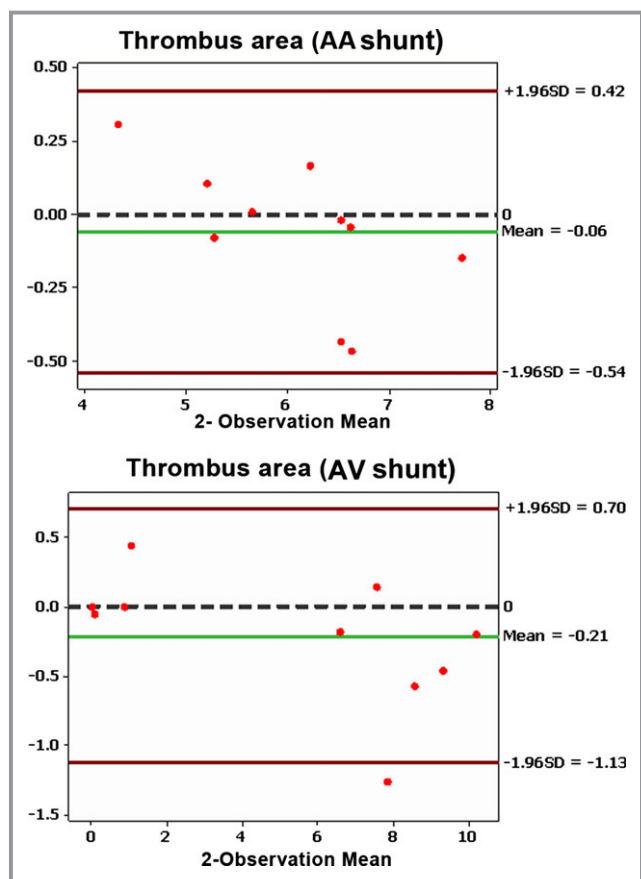


Figure 4. Bland-Altman analysis of interobserver agreement of residual thrombus burden in 10 randomly chosen AA and AV shunts. AA indicates arterio-arterial; AV, arteriovenous.

may cause bleeding complications, particularly in the presence of an underlying hemostatic defect or with concurrent thrombolytic therapy.²¹ The use of fibrinolytic drugs has not been established in children, and carries significant risk of major hemorrhage.

Attempted recanalization of acutely thrombosed ECS by catheter-mediated thrombus disruption or rheolytic thrombectomy²⁶ has been met with some success. Sub-acute ECS occlusion develops from neointimal proliferation in addition to thrombus formation within the shunt, so recanalization is more difficult in such cases. Therefore, treatments designed to locally prevent thrombus formation/reduce thrombus burden and maintain ECS patency would be ideal, and avoid these systemic complications. MBs coupled with US have been used to dissolve thrombi without thrombolytic agents, and also have been shown to enhance the effectiveness of exogenous tissue plasminogen activator.^{13,27} In *in vivo* models, successful dissolution of arterial and venous thrombi is achievable with guided high MI impulses delivered from a diagnostic US transducer. The advantage of this approach is that it permits simultaneous low MI MB sensitive imaging

pulse sequence schemes to detect the MB with the same transducer, and allows one to control the region in which therapy is desired.^{12,13,16,17,27}

The present study describes the application of this treatment for thromboprophylaxis of ECS *in vivo*. An image-guided approach ensured the presence of MB near the shunt when the high MI impulses were applied. Successful thromboprophylaxis evidenced by low thrombus burden was seen in the AV shunts. The arteriovenous connection generates an intravascular pressure differential, similar to the Blalock-Thomas-Taussig shunt or Sano shunt used for CHD palliation. These shunts are subject to intimal proliferation due to shear forces of turbulent blood flow, and subsequent thrombus deposition on the irregular surface where blood flow slows.

No statistically significant reduction in thrombus burden was demonstrated in AA shunts. This was presumably because of the (1) higher baseline flow rates and consequently lower predisposition for stasis-related thrombus formation, and (2) the relatively short duration (4 weeks) of placement. We speculate that the interposition shunts within the carotid artery (AA) had improved flow compared to the side-side connected AV shunts. For the AV shunts, there is the possibility of narrowing at the side-to-side anastomoses and turbulence of flow due to pressure differences between the vessels, which may have led to increased thrombogenesis.

The safety and success of this noninvasive thromboprophylactic application in our porcine model increase the potential for translation to AV shunts in the human. Besides CHD, a potential therapeutic application of AV shunt thromboprophylaxis is in patients with end-stage renal disease where the use of such shunts is very common. The application may also be particularly advantageous in infants and children because of the proximity of vascular structures to allow improved penetration of transcutaneously applied US impulses. Moreover, recent clinical trials have indicated that US contrast agents are safe and effective in children and young adults.²⁸ Comparisons of efficacy between US-MB thromboprophylaxis and pharmacologic (antiplatelet or anticoagulant) prophylaxis require further study.

Study Limitations

The number of animals studied was relatively small and the duration of placement of shunts prior to explantation and histopathologic examination was 4 weeks. Considering that AV shunts in the human are placed for substantially longer periods of time, whether the same results could be extrapolated for longer durations/older shunts is unknown. The purpose of this study was to explore the feasibility of ultrasound and microbubble prophylaxis, but further work is needed to explore this treatment approach in shunts placed for longer periods of time.

Evaluation for the possibility of soft tissue injury due to bioeffects associated with high-MI impulses from the transducer requires further investigation. There is potential for unwanted US mechanical bioeffects at MI>1.0, however, these are likely to be minimal because the US application used in the study was with a commercially available diagnostic transducer, and the high-MI therapeutic pulses were significantly lower than the Food and Drug Administration recommended MI limit for clinical use. The MBs used in this study have been successfully used in human trials as adjuvant for arterial sonothrombolysis.²⁹ Although these MBs are not yet commercially available, they are similar in shell composition and MB size to commercially available lipid encapsulated MBs. Finally, these results would only be applicable to AV shunts. Other palliative connections in CHD are also subject to thrombotic occlusion, and the role of thromboprophylaxis with US and MB must be explored in such settings, where attenuation of the US beam may play a role in achieving adequate inertial cavitation of the MB.

Conclusions

Transcutaneous US and intravenous MB are capable of decreasing thrombus burden in arteriovenous shunts without the need for antiplatelet agents, and may be a method of preventing progressive occlusion of a high-flow, small diameter expanded polytetrafluoroethylene tube graft such as the modified Blalock shunt or the Sano shunt.

Acknowledgments

We appreciate the expert technical assistance of Elizabeth Stolze, Lucas Drvol, and Gretchen Fry of the Joint Cardiovascular Research Laboratory of the University of Nebraska Medical Center.

Sources of Funding

This study was funded by the American Heart Association grant 12SDG9260001. The funding source was not involved in data collection, data analysis, or manuscript drafting.

Disclosure

None.

References

- Lamberti JJ, Carlisle J, Waldman JD, Lodge FA, Kirkpatrick SE, George L, Mathewson JW, Turner SW, Pappelbaum SJ. Systemic-pulmonary shunts in infants and children. Early and late results. *J Thorac Cardiovasc Surg.* 1984;88:76–81.
- Sano S, Huang SC, Kasahara S, Yoshizumi K, Kotani Y, Ishino K. Risk factors for mortality after the Norwood procedure using right ventricle to pulmonary artery shunt. *Ann Thorac Surg.* 2009;87:178–185; discussion 185–176.
- Fermanis GG, Ekganki AK, Salmon AP, Keeton BR, Shore DF, Lamb RK, Monro JL. Twelve year experience with the modified Blalock-Taussig shunt in neonates. *Eur J Cardiothorac Surg.* 1992;6:586–589.
- Al Jubair KA, Al Fagih MR, Al Jarallah AS, Al Yousef S, Ali Khan MA, Ashmeg A, Al Faraidi Y, Sawyer W. Results of 546 Blalock-Taussig shunts performed in 478 patients. *Cardiol Young.* 1998;8:486–490.
- Gladman G, McCrindle BW, Williams WG, Freedom RM, Benson LN. The modified Blalock-Taussig shunt: clinical impact and morbidity in Fallot's tetralogy in the current era. *J Thorac Cardiovasc Surg.* 1997;114:25–30.
- Fenton KN, Siewers RD, Rebovich B, Pigula FA. Interim mortality in infants with systemic-to-pulmonary artery shunts. *Ann Thorac Surg.* 2003;76:152–156; discussion 156–157.
- O'Connor MJ, Ravishankar C, Ballweg JA, Gillespie MJ, Gaynor JW, Tabbutt S, Dominguez TE. Early systemic-to-pulmonary artery shunt intervention in neonates with congenital heart disease. *J Thorac Cardiovasc Surg.* 2011;142:106–112.
- Li JS, Yow E, Berezny KY, Rhodes JF, Bokesch PM, Charpie JR, Forbus GA, Mahony L, Boshkov L, Lambert V, Bonnet D, Michel-Behnke I, Graham TP, Takahashi M, Jagers J, Califf RM, Rakhit A, Fontecave S, Sanders SP. Clinical outcomes of palliative surgery including a systemic-to-pulmonary artery shunt in infants with cyanotic congenital heart disease: does aspirin make a difference? *Circulation.* 2007;116:293–297.
- Tomizawa Y, Takahashi Y, Noishiki Y, Nishida H, Endo M, Koyanagi H. Evaluation of small caliber vascular prostheses implanted in small children: activated angiogenesis and accelerated calcification. *ASAIO J.* 1998;44:M496–M500.
- Wells WJ, Yu RJ, Batra AS, Monforte H, Sintek C, Starnes VA. Obstruction in modified Blalock shunts: a quantitative analysis with clinical correlation. *Ann Thorac Surg.* 2005;79:2072–2076.
- Tsai KT, Chang CH, Lin PJ. Modified Blalock-Taussig shunt: statistical analysis of potential factors influencing shunt outcome. *J Cardiovasc Surg (Torino).* 1996;37:149–152.
- Xie F, Lof J, Everbach C, He A, Bennett RM, Matsunaga T, Johanning J, Porter TR. Treatment of acute intravascular thrombi with diagnostic ultrasound and intravenous microbubbles. *JACC Cardiovasc Imaging.* 2009;2:511–518.
- Porter TR. The utilization of ultrasound and microbubbles for therapy in acute coronary syndromes. *Cardiovasc Res.* 2009;83:636–642.
- Prokop AF, Soltani A, Roy RA. Cavitation mechanisms in ultrasound-accelerated fibrinolysis. *Ultrasound Med Biol.* 2007;33:924–933.
- Everbach EC, Francis CW. Cavitation mechanisms in ultrasound-accelerated thrombolysis at 1 MHz. *Ultrasound Med Biol.* 2000;26:1153–1160.
- Kutty S, Xie F, Gao S, Drvol LK, Lof J, Fletcher SE, Radio SJ, Danford DA, Hammel JM, Porter TR. Sonothrombolysis of intra-catheter aged venous thrombi using microbubble enhancement and guided three-dimensional ultrasound pulses. *J Am Soc Echocardiogr.* 2010;23:1001–1006.
- Kutty S, Wu J, Hammel JM, Xie F, Gao S, Drvol LK, Lof J, Radio SJ, Therrien SL, Danford DA, Porter TR. Microbubble mediated thrombus dissolution with diagnostic ultrasound for the treatment of chronic venous thrombi. *PLoS ONE.* 2012;7:e51453.
- Xie F, Everbach EC, Gao S, Drvol LK, Shi WT, Vignon F, Powers JE, Lof J, Porter TR. Effects of attenuation and thrombus age on the success of ultrasound and microbubble-mediated thrombus dissolution. *Ultrasound Med Biol.* 2011;37:280–288.
- Ostensen J, Hede R, Myreng Y, Ege T, Holtz E. Intravenous injection of Albunex microspheres causes thromboxane mediated pulmonary hypertension in pigs, but not in monkeys or rabbits. *Acta Physiol Scand.* 1992;144:307–315.
- Geny B, Mettauer B, Muan B, Bischoff P, Epailly E, Piquard F, Eisenmann B, Haberey P. Safety and efficacy of a new transpulmonary echo contrast agent in echocardiographic studies in patients. *J Am Coll Cardiol.* 1993;22:1193–1198.
- Monagle P, Chalmers E, Chan A, DeVeber G, Kirkham F, Massicotte P, Michelson AD. Antithrombotic therapy in neonates and children: American college of chest physicians evidence-based clinical practice guidelines (8th edition). *Chest.* 2008;133:887S–968S.
- Moszura T, Zubrzycka M, Michalak KW, Rewers B, Dryzek P, Moll JJ, Sysa A, Burczynski P. Acute and late obstruction of a modified Blalock-Taussig shunt: a two-center experience in different catheter-based methods of treatment. *Interact Cardiovasc Thorac Surg.* 2010;10:727–731.
- Motz R, Wessel A, Ruschewski W, Bursch J. Reduced frequency of occlusion of aorto-pulmonary shunts in infants receiving aspirin. *Cardiol Young.* 1999;9:474–477.

24. Mohammadi S, Benhameid O, Campbell A, Potts J, Joza J, Al-Habib H, Sett S, Le Blanc J. Could we still improve early and interim outcome after prosthetic systemic-pulmonary shunt? A risk factors analysis. *Eur J Cardiothorac Surg*. 2008;34:545–549; discussion 549.
25. Barrett MJ, Hurwitz ES, Schonberger LB, Rogers MF. Changing epidemiology of Reye syndrome in the United States. *Pediatrics*. 1986;77:598–602.
26. Kogon B, Villari C, Shah N, Kirshbom P, Kanter K, Kim D, Raviele A, Vincent R. Occlusion of the modified Blalock-Taussig shunt: unique methods of treatment and review of catheter-based intervention. *Congenit Heart Dis*. 2007;2:185–190.
27. Porter TR, Kricsfeld D, Lof J, Everbach EC, Xie F. Effectiveness of transcranial and transthoracic ultrasound and microbubbles in dissolving intravascular thrombi. *J Ultrasound Med*. 2001;20:1313–1325; quiz 1326.
28. Kutty S, Olson J, Danford CJ, Sandene EK, Xie F, Fletcher SE, Erickson CC, Kugler JD, Danford DA, Porter TR. Ultrasound contrast and real-time perfusion in conjunction with supine bicycle stress echocardiography for comprehensive evaluation of surgically corrected congenital heart disease. *Eur Heart J Cardiovasc Imaging*. 2012;13:500–509.
29. Alexandrov AV, Mikulik R, Ribo M, Sharma VK, Lao AY, Tsivgoulis G, Sugg RM, Barreto A, Sierzenski P, Malkoff MD, Grotta JC. A pilot randomized clinical safety study of sonothrombolysis augmentation with ultrasound-activated perflutren-lipid microspheres for acute ischemic stroke. *Stroke*. 2008;39:1464–1469.



Prevention of Arteriovenous Shunt Occlusion Using Microbubble and Ultrasound Mediated Thromboprophylaxis

Shelby Kutty, Juefei Wu, James M. Hammel, Joseph R. Abraham, Jeeva Venkataraman, Ibrahim Abdullah, David A. Danford, Stanley J. Radio, John Lof and Thomas R. Porter

J Am Heart Assoc. 2014;3:e000689; originally published February 11, 2014;
doi: 10.1161/JAHA.113.000689

The *Journal of the American Heart Association* is published by the American Heart Association, 7272 Greenville Avenue, Dallas, TX 75231
Online ISSN: 2047-9980

The online version of this article, along with updated information and services, is located on the World Wide Web at:

<http://jaha.ahajournals.org/content/3/1/e000689>

Subscriptions, Permissions, and Reprints: The *Journal of the American Heart Association* is an online only Open Access publication. Visit the Journal at <http://jaha.ahajournals.org> for more information.