

Winter 11-1-2009

SOX11 expression is highly specific for mantle cell lymphoma and identifies the cyclin D1-negative subtype.

Ana Mozos
University of Barcelona

Cristina Royo
University of Barcelona

Elena Hartmann
University of Würzburg

Daphne De Jong
The Netherlands Cancer Institute/Antoni von Leeuwenhoek Hospital

Cristina Baró
Hospital del Mar, Barcelona

Tell us how you used this information in this [short survey](#).

Follow this and additional works at: https://digitalcommons.unmc.edu/com_pathmicro_articles

See next page for additional authors



Part of the [Medical Microbiology Commons](#), and the [Pathology Commons](#)

Recommended Citation

Mozos, Ana; Royo, Cristina; Hartmann, Elena; De Jong, Daphne; Baró, Cristina; Valera, Alexandra; Fu, Kai; Weisenburger, Dennis D.; Delabie, Jan; Chuang, Shih-Sung; Jaffe, Elaine S.; Ruiz-Marcellan, Carmen; Dave, Sandeep; Rimsza, Lisa; Braziel, Rita; Gascoyne, Randy D.; Solé, Francisco; López-Guillermo, Armando; Colomer, Dolors; Staudt, Louis M.; Rosenwald, Andreas; Ott, German; Jares, Pedro; and Campo, Elias, "SOX11 expression is highly specific for mantle cell lymphoma and identifies the cyclin D1-negative subtype." (2009). *Journal Articles: Pathology and Microbiology*. 30.
https://digitalcommons.unmc.edu/com_pathmicro_articles/30

This Article is brought to you for free and open access by the Pathology and Microbiology at DigitalCommons@UNMC. It has been accepted for inclusion in Journal Articles: Pathology and Microbiology by an authorized administrator of DigitalCommons@UNMC. For more information, please contact digitalcommons@unmc.edu.

Authors

Ana Mozos, Cristina Royo, Elena Hartmann, Daphne De Jong, Cristina Baró, Alexandra Valera, Kai Fu, Dennis D. Weisenburger, Jan Delabie, Shih-Sung Chuang, Elaine S. Jaffe, Carmen Ruiz-Marcellan, Sandeep Dave, Lisa Rimsza, Rita Braziel, Randy D. Gascoyne, Francisco Solé, Armando López-Guillermo, Dolors Colomer, Louis M. Staudt, Andreas Rosenwald, German Ott, Pedro Jares, and Elias Campo

SOX11 expression is highly specific for mantle cell lymphoma and identifies the cyclin D1-negative subtype

Ana Mozos,¹ Cristina Royo,¹ Elena Hartmann,² Daphne De Jong,³ Cristina Baró,⁴ Alexandra Valera,¹ Kai Fu,⁵ Dennis D. Weisenburger,⁵ Jan Delabie,⁶ Shih-Sung Chuang,⁷ Elaine S. Jaffe,⁸ Carmen Ruiz-Marcellan,⁹ Sandeep Dave,¹⁰ Lisa Rimsza,¹¹ Rita Braziel,¹² Randy D. Gascoyne,¹³ Francisco Solé,⁴ Armando López-Guillermo,¹ Dolores Colomer,¹ Louis M. Staudt,⁸ Andreas Rosenwald,¹⁴ German Ott,¹⁴ Pedro Jares,¹ and Elias Campo¹

¹Hematopathology Section, Department of Pathology and Hematology, Hospital Clinic, Institut d'Investigacions Biomèdiques August Pi i Sunyer (IDIBAPS), University of Barcelona, Spain; ²Institute of Pathology, University of Würzburg, Würzburg, Germany; ³Department of Pathology, The Netherlands Cancer Institute/Antoni van Leeuwenhoek Hospital, Amsterdam, The Netherlands; ⁴Laboratory of Molecular Cytogenetics, Department of Pathology, Hospital del Mar, Barcelona, Spain; ⁵Department of Pathology and Microbiology, University of Nebraska Medical Center, Omaha; ⁶Department of Pathology, Norwegian Radium Hospital, Oslo, Norway; ⁷Department of Pathology, Chi-Mei Medical Center, Tainan, Taiwan; ⁸Section of Hematopathology and Lymphoma Clinical Research, Center for Cancer Research, Division of Cancer Treatment and Diagnosis, National Cancer Institute, National Institutes of Health, Bethesda, USA; ⁹Department of Pathology, Vall d'Hebron University Hospital, Autonomous University of Barcelona, Spain; ¹⁰Duke Institute for Genome Sciences and Policy, Duke University, Durham, North Carolina, USA; ¹¹Department of Pathology, The University of Arizona College of Medicine, Tucson, Arizona, USA; ¹²Department of Pathology, Oregon Health and Science University, USA; ¹³Department of Pathology & Laboratory Medicine, University of British Columbia, Vancouver, Canada, and ¹⁴Institut für Klinische Pathologie, Robert-Bosch-Krankenhaus, Stuttgart, Germany

Acknowledgments: the authors would like to thank Wing C. Chan and Manisha Bahl for their comments and suggestions during the development of the project.

Funding: this study was supported by the Spanish Ministry of Science and Innovation SAF 2008-03630, Instituto de Salud Carlos III "Red Temática de Investigación Cooperativa de Cáncer" (2006RET2039) and Acción Transversal (V-2008-ISCIII01) and the National of Health (5U01CA114778-03). AR and EMH are supported by the Interdisciplinary Center for Clinical Research (IZKF), University of Würzburg, Germany.

Manuscript received April on 16, 2009. Revised version arrived on May 15, 2009. Manuscript accepted on May 19, 2009.

Correspondence: Elias Campo, MD, PhD. Department of Pathology, Hospital Clinic, Villarroel 170, Barcelona 08036, Spain. E-mail: ecampo@clinic.ub.es

ABSTRACT

Background

Cyclin D1-negative mantle cell lymphoma is difficult to distinguish from other small B-cell lymphomas. The clinical and pathological characteristics of patients with this form of lymphoma have not been well defined. Overexpression of the transcription factor *SOX11* has been observed in conventional mantle cell lymphoma. The aim of this study was to determine whether this gene is expressed in cyclin D1-negative mantle cell lymphoma and whether its detection may be useful to identify these tumors.

Design and Methods

The microarray database of 238 mature B-cell neoplasms was re-examined. *SOX11* protein expression was investigated immunohistochemically in 12 cases of cyclin D1-negative mantle cell lymphoma, 54 cases of conventional mantle cell lymphoma, and 209 additional lymphoid neoplasms.

Results

SOX11 mRNA was highly expressed in conventional and cyclin D1-negative mantle cell lymphoma and in 33% of the cases of Burkitt's lymphoma but not in any other mature lymphoid neoplasm. *SOX11* nuclear protein was detected in 50 cases (93%) of conventional mantle cell lymphoma and also in the 12 cyclin D1-negative cases of mantle cell lymphoma, the six cases of lymphoblastic lymphomas, in two of eight cases of Burkitt's lymphoma, and in two of three T-prolymphocytic leukemias but was negative in the remaining lymphoid neoplasms. Cyclin D2 and D3 mRNA levels were significantly higher in cyclin D1-negative mantle cell lymphoma than in conventional mantle cell lymphoma but the protein expression was not discriminative. The clinico-pathological features and outcomes of the patients with cyclin D1-negative mantle cell lymphoma identified by *SOX11* expression were similar to those of patients with conventional mantle cell lymphoma.

Conclusions

SOX11 mRNA and nuclear protein expression is a highly specific marker for both cyclin D1-positive and negative mantle cell lymphoma.

Key words: mantle cell lymphoma, cyclin D1, *SOX11*.

Citation: Mozos A, Royo C, Hartmann E, De Jong D, Baró C, Valera A, Fu K, Weisenburger DD, Delabie J, Chuang S-S, Jaffe ES, Ruiz-Marcellan C, Dave S, Rimsza L, Braziel R, Gascoyne RD, Solé F, López-Guillermo A, Colomer D, Staudt LM, Rosenwald A, Ott G, Jares P, and Campo E. SOX11 expression is highly specific for mantle cell lymphoma and identifies the cyclin D1-negative subtype. Haematologica 2009; 94:1555-1562. doi:10.3324/haematol.2009.010264

©2009 Ferrata Storti Foundation. This is an open-access paper.

Introduction

Mantle cell lymphoma (MCL) is an aggressive lymphoid neoplasm genetically characterized by the presence of the t(11;14)(q13;q32) translocation that activates constitutive expression of cyclin D1, an important regulator of the G₁/S phase of the cell cycle.^{1,2} In addition to this primary genetic alteration, MCL also has a relatively specific profile of secondary genetic aberrations that include frequent losses, gains and recurrent chromosomal breakpoints.³⁻⁷ In spite of the constant overexpression of cyclin D1 in MCL, some studies reported tumors with similar morphological and phenotypic characteristics but lacking the t(11;14) translocation and cyclin D1 expression.⁸ However, it was controversial whether the apparent lack of cyclin D1 was a real biological phenomenon or was due to technical limitations in its detection. Fu *et al.*⁹ described six cases of MCL that were negative for cyclin D1 and the t(11;14) translocation but had the same gene expression profile as conventional MCL. These cases also had the same profile of secondary genetic aberrations as conventional MCL and different from that of other B-cell neoplasms supporting the idea that cyclin D1-negative MCL is a real biological variant of this tumor.^{10,11}

The recognition of cyclin D1-negative MCL is difficult because it may resemble other small B-cell lymphomas morphologically and phenotypically. However, this distinction is clinically very relevant. Although the clinical information on cyclin D1-negative MCL is limited, published data indicate that the behavior of the variant is as aggressive as that of conventional MCL.¹² On the other hand, patients with small B-cell lymphomas mimicking MCL have a significantly better outcome than those with real MCL.⁹ It is, therefore, important to find reliable biomarkers that may allow the identification of cyclin D1-negative MCL in clinical practice.

Cyclin D1-negative MCL seem to express high levels of cyclin D2 or D3 which, in some cases, are associated with translocations of these genes.¹²⁻¹⁴ These cyclins are also expressed at lower levels in other B-cell lymphomas. *SOX11*, a neural transcription factor, was found to be expressed at higher levels in leukemic MCL cells than in naïve B cells and other B-cell lymphomas.^{15,16} Nuclear expression of the protein has been identified in conventional MCL but not in other lymphoid neoplasms.^{16,17} Thus, the presence of *SOX11* may be a useful identifier of cyclin D1-negative MCL. However, the spectrum of lymphoid neoplasms in previous studies was limited and no real cases of MCL negative for cyclin D1 and 11q13 rearrangements were included. The goal of our study was, therefore, to confirm the specific expression of *SOX11* in MCL and define its value as a biomarker to identify cyclin D1-negative MCL.

Design and Methods

Case selection

The six initial cases of cyclin D1-negative MCL⁹ and one case described by Chuang *et al.*¹⁸ were included in

this study. In addition, we identified five new cases that had the morphological and phenotypic features of MCL but were negative for the t(11;14) translocation and cyclin D1 expression. At least three hematopathologists reviewed these cases and confirmed the diagnosis. The clinical follow-up of five of the six patients who were alive at the time of the previous respective reports^{9,18} was updated and the clinical charts of the new patients were revised. Lymph node biopsies from these 12 cyclin D1-negative MCL cases were available for the study. For comparison, we included in the study a large series of 209 patients with other lymphomas (Table 1). The local medical ethical committee approved the study.

Microarray gene expression profiling

To evaluate the mRNA expression of *SOX11*, cyclin D1, D2, and D3 in MCL and other non-Hodgkin's lymphomas we reviewed the gene expression data generated in different studies of the Leukemia Lymphoma Molecular Profiling Project (LLMPP). The CEL files of 258 lymphomas derived from different GeneChip types were combined. One set contained 163 CEL files obtained from HU133plus 2.0 GeneChip arrays (Affimetrix, Santa Clara, USA) representing 33 cases of Burkitt's lymphoma (BL), 46 cases of diffuse large B-cell lymphoma (DLBCL), 20 primary mediastinal B-cell lymphomas (PMBL), and 64 MCL. The second set included 75 CEL files generated with HU133A GeneChip arrays representing 44 follicular lymphomas (FL) and 31 MCL, including six cyclin D1-negative MCL. To study both sets of different chip types together, we used the function combineAffyBatch described in the Matchprobes

Table 1. *SOX11* nuclear protein expression in lymphoid neoplasms.

	n	Sox11-positive (%)
Cyclin D1-negative MCL	12	12 (100%)
Mantle cell lymphoma	54	50 (93%)
Chronic lymphocytic leukemia	12	0 (0%)
Splenic marginal zone lymphoma	9	0 (0%)
Nodal marginal zone lymphoma	11	0 (0%)
Follicular lymphoma	22	0 (0%)
Diffuse large B-cell lymphoma	63	0 (0%)
Burkitt's lymphoma	8	2 (25%)*
Classical Hodgkin's lymphoma	36	1 (3%)**
NLPHL	5	0 (0%)
Multiple myeloma (cyclinD1-positive)	2	0 (0%)
B-cell lymphoblastic lymphoma/leukemia	1	1 (100%)
T-cell lymphoblastic lymphoma/leukemia	5	5 (100%)
Peripheral T-cell lymphoma, NOS	15	0 (0%)
Angioimmunoblastic T-cell lymphoma	5	0 (0%)
Hepatosplenic T-cell lymphoma	3	0 (0%)
Anaplastic large cell lymphoma (ALK+)	3	0 (0%)
Anaplastic large cell lymphoma (ALK-)	3	0 (0%)
T-cell prolymphocytic leukemia	3	2 (66%)
Extranodal NK/T-cell lymphoma, nasal type	3	0 (0%)

MCL: mantle cell lymphoma; NLPHL: nodular lymphocytic predominant Hodgkin's lymphoma; NOS: not otherwise specified; *three additional cases showed weak immunostaining. **the staining intensity was weak.

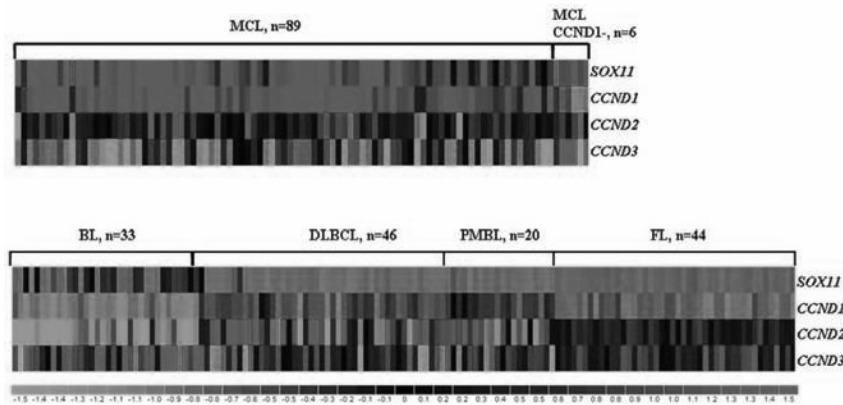


Figure 1. Heat map representing gene expression values for SOX11, CYCLIN D1 (CCND1), CYCLIN D2 (CCND2) AND CYCLIN D3 (CCND3). Cases of MCL, including CCND1-negative MCL are shown in the top half whereas other lymphoid neoplasms are displayed in the bottom half.

MCL: mantle cell lymphoma; BL: Burkitt's lymphoma; DLBCL: diffuse large B-cell lymphoma; PMBL: primary mediastinal B-cell lymphoma; FL: follicular lymphoma.

package from Bioconductor (<http://www.bioconductor.org>), which enables data from different Affymetrix genechip types to be combined into one single set merging the intensities from the matching probes. Afterwards, a single set of 238 arrays was normalized using the robust microarray analysis method. The signal value for all the probe sets corresponding to cyclin D1, cyclin D2, cyclin D3, and SOX11 were extracted from the normalized set, and the mean of all the probe sets representing the different genes was used as the final gene level expression for each gene. These data were represented in a heat map using the DNA-Chip analyzer software v1.3 (dChip, Boston, MA, USA).

Immunohistochemistry

SOX11 protein expression was studied in tissue microarrays and whole tissue sections. Formalin-fixed paraffin-embedded tissue sections were stained for SOX11 (1:100; Atlas Antibodies, Stockholm, Sweden), cyclin D1 (1:100; Thermo Fisher Scientific, Runcorn, UK), cyclin D2 (1:100) and cyclin D3 (1:50) (Cell Signaling Technology, Beverly, MA, USA) in the automated platform BondMax (VisionBiosystems, Mount Waverley, Victoria, Australia). We used heat-induced retrieval with ER2 BondMax buffer solution for 15 min and detected positivity with a horseradish-peroxidase-linked polymer for 8 min (Define; Vision Biosystems) and 5'-3'diaminobenzidine for 10 min.

Quantitative polymerase chain reaction

SOX11, cyclin D1, D2, and D3 mRNA expression was investigated by quantitative reverse transcriptase-polymerase chain reaction (RT-PCR) in cases not included in previous microarray expression profiling studies. Total RNA was extracted from frozen tissue samples and formalin-fixed paraffin-embedded tissue blocks using the RNeasy minikit and FFPE RNeasy minikit, respectively (Qiagen, Germantown, MA, USA). The potential residual DNA was removed using the TURBO DNA-free™ kit from Ambion (Applied Biosystems) according to the manufacturer's protocol. Complementary DNA synthesis was carried out from 1 µg of total RNA and the product was amplified and quantified using TaqMan®

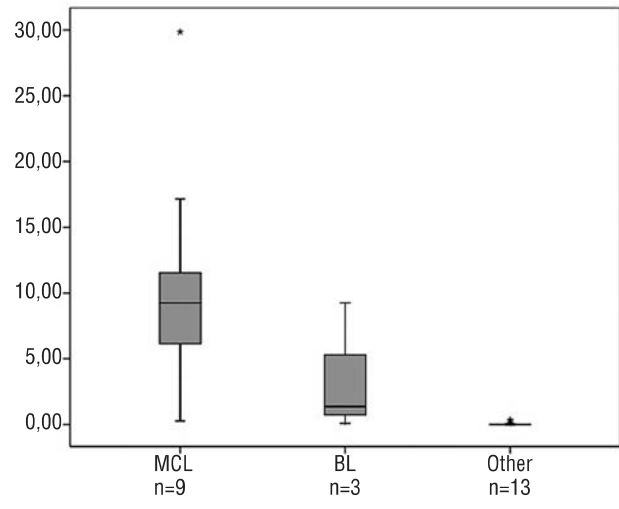


Figure 2. Quantitative RT-PCR analysis of SOX11 mRNA expression in mantle cell lymphoma (MCL), Burkitt's lymphoma (BL) and other lymphoid neoplasms (Other).

Universal PCR Master Mix (Applied Biosystems, Foster City, CA, USA) and TaqMan® Gene Expression Assays for SOX11 (Hs00846583_s1), CCND1 (Hs00765553_m1), CCND2 (Hs00153380_m1) and CCND3 (Hs00236949_m1) in an ABI Prism 7900HT Fast Sequence Detection System (Applied Biosystems). Relative quantification of gene expression was performed as described in the Taqman® user's manual and the expression levels were analyzed with the $2^{-\Delta\Delta Ct}$ method using human β -glucuronidase (*GUS*) as the endogenous control and universal human reference RNA (Stratagene, Agilent Technologies, Santa Clara, CA, USA) as the mathematical calibrator.

Using quantitative PCR, we analyzed frozen tissue obtained from nine patients with MCL, five with DLBCL, two with chronic lymphocytic leukemia, one with FL, two with splenic marginal zone lymphoma (MZL), two with nodal MZL, one with MALT MZL and three with BL. Moreover, we studied ten cyclin D1-positive and five cyclin D1-negative MCL using formalin-fixed paraffin-embedded tissue.

Fluorescence in situ hybridization

Interphase fluorescence *in situ* hybridization (FISH) analysis was performed on formalin-fixed, paraffin-embedded tissue sections. The *CCND1* rearrangement was studied using a dual color break-apart probe (DAKO, Denmark code Y5414). *CCND2* and *CCND3* rearrangements were studied using dual color break-apart non-commercial translocation probes. The *CCND2* probe consisted of two bacterial artificial chromosome (BAC) clones directly labeled using nick translation. BAC RP11-578L13 located at the 5' end of the gene was labeled in green and BAC RP11-388F6 located at the 3' end of the gene was labeled in red.⁹

The *CCND3* locus was investigated using the previously described probes¹⁹ consisting of one BAC clone RP11-288J23 and three plasmid artificial chromosomes (PAC): RP5-973N23, RP1-139D8 and RP1-321B9. The BAC clones were obtained from the CHORI library (www.chori.org) available in our center and the PAC clones were provided by Dr. Gesk (Institute of Human Genetics, University Hospital Kiel, Germany). At least 200 nuclei were examined. Five tonsil samples from healthy donors were used as negative controls for paraffin-embedded tissues. The cut-off value was calculated as the mean percentage of cells with a false-positive signal constellation plus three standard deviations.

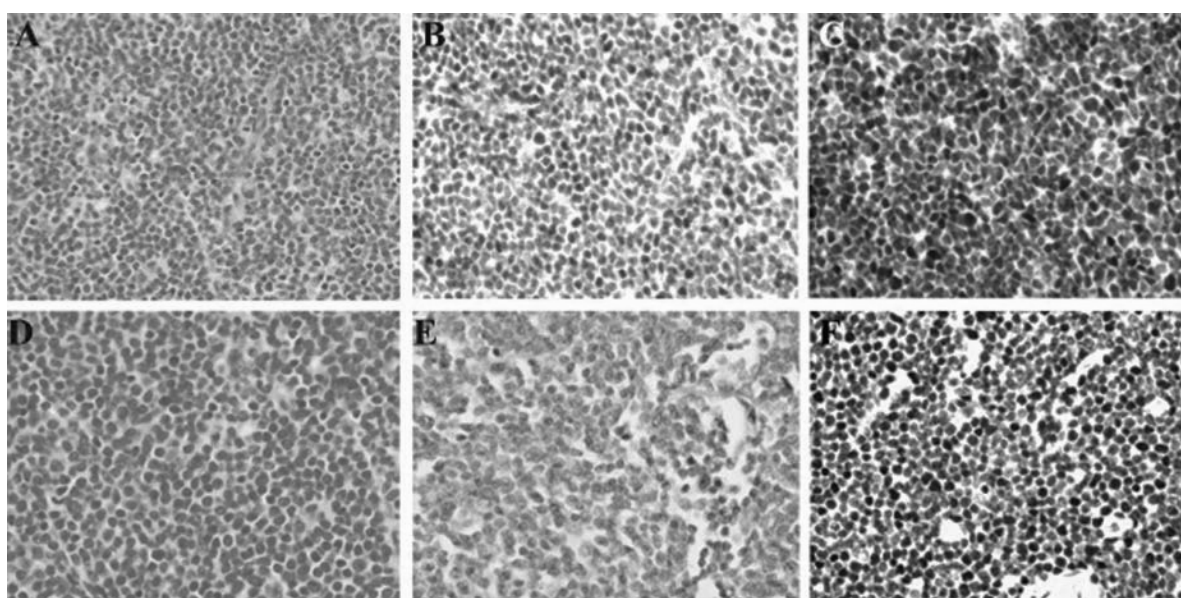


Figure 3. SOX11 protein expression in conventional and cyclin D1-negative MCL. (A, D) Conventional and cyclin D1-negative MCL, respectively (Hematoxylin & Eosin; x400); (B, E) Cyclin D1 and (C, F) SOX11 expression in conventional and cyclin D1-negative MCL, respectively (immunohistochemistry; x200);

Table 2. Clinical features of 12 patients with cyclin D1-negative MCL.

	Age/Sex	B symptoms	Extranodal	LDH	Stage	IPI	Therapy	Response	OS (months)	Status
1	54/F	No	No	Normal	IIIA	1	CHOP	CR*	60	AWD
2	61/M	Yes	PB, BM	High	IV	3	R-CHOP	PR	11	DOD
3	61/M	No	BM	Normal	IV	2	CHOP	PR	88	DOD
4	60/M	Yes	PB, BM, spleen	High	IV	3	COP+FCR	PR	26	DOD
5	54/M	No	BM	Normal	IV	2	CHOP	PR	101	DOD
6	77/M	No	BM,	Normal	IV	3	CTX (KNOSPE)	PR	30	AWD
7	56/M	Yes	BM, Liver	High	IVB	2	CEOP	N/A	25	DOD
8	60/M	N/A	Colorectal tumor	N/A	IIAE		R-CHOP	N/A	39	AWD
9	52/F	No	BM	Normal	IVA		R-CHOP	PR	37	AWD
10	70/F	Yes	Tonsil	Normal	IIIE		R-CHOP	PR	37	DOD
11	39/M	Yes	PB, BM	High	IV	2	R-CHVmP/BO	PR	24	DOD
12	68/M	No	No	Normal	IA	1	R-CHOP+RDT	CR*	71	DOD

LDH: lactate dehydrogenase; IPI: International Prognostic Index; OS: overall survival; PB: peripheral blood; BM: bone marrow; C: cyclophosphamide; H: adriamycin; O: vincristine; P: prednisone; R: rituximab; E: etoposide; F: fludarabine; Vm: teniposide; B: bleomycin; RDT: radiotherapy; CR: complete remission; PR, partial response; AWD: alive with disease; DOD: died of disease; N/A: not available. * Relapsed (see text).

Statistical analysis

The χ^2 test was used to evaluate the different levels of SOX11 expression. The quantitative RT-PCR results of SOX11, cyclin D1, D2 and D3 expression levels were compared using the Mann-Whitney test. *p* values less than 0.05 were considered statistically significant. Statistical tests were performed using SPSS v14 software (SPSS, Chicago, IL, USA).

Results

SOX11 mRNA expression in B-cell lymphomas

To confirm the specificity of SOX11 mRNA expression in MCL we assembled multiple microarray datasets derived from previous LLMPP studies (Figure 1). Most of the MCL showed higher levels of SOX11 (mean=1122.9; SD=754.6) compared to BL (n=33; mean=122.5; SD=136.3), DLBCL (n=46; mean=26.951; SD=14.4), PMBL (n=20; mean=24.2; SD=2.8) and FL (n=44; mean=26.3; SD=1.8). However, 33% of the cases of BL (11 of 33) showed similar SOX11 expression to that displayed by the MCL with the lower levels (3-22%), indicating that SOX11 overexpression is not completely restricted to MCL.

The mRNA expression of SOX11 was further investigated by quantitative RT-PCR in frozen samples from an additional series of MCL and a range of B-cell lymphomas (Figure 2). SOX11 was highly expressed in eight out of nine MCL (88%) (mean=8.9; SD=9.4). Concordantly with microarray expression data, two of the three cases of BL showed similar mRNA levels to those observed in MCL (mean= 3.5; SD= 4.9) while expression was undetectable or very low in other types of lymphomas (mean= 0.05; SD= 0.1) (Figure 2).

SOX11 protein expression in mantle cell lymphoma and other non-Hodgkin's lymphoma

To confirm the specific detection of SOX11 in MCL we investigated protein expression by immunohistochemistry in a series of 54 cyclin D1-positive MCL, and 209 other lymphoid neoplasms (Table 1). Interestingly, virtually all MCL were strongly positive for SOX11 (50/54, 93%), with a nuclear pattern (Figure 3). The staining was intense and relatively homogeneous in most of the cells. Compared to cyclin D1 staining, SOX11 reactivity was stronger and more homogeneous.

Interestingly, the five T-cell and the B-cell lymphoblastic leukemia/lymphomas showed strong SOX11 nuclear expression. Notably, one case of classic Hodgkin's lymphoma, two of eight BL and two of the three T-cell prolymphocytic leukemias were also positive. The remaining Hodgkin's lymphoma, T and B-cell lymphomas, including two multiple myeloma with t(11;14) and cyclin D1 expression were negative or showed only a cytoplasmic dot-like staining (Table 1, Figure 4).

We also examined the expression of SOX11 in reactive tonsil lymph node and spleen specimens. No nuclear expression was observed in any lymphocyte compartment. Only cytoplasmic staining was seen in cells from reactive germinal centers.

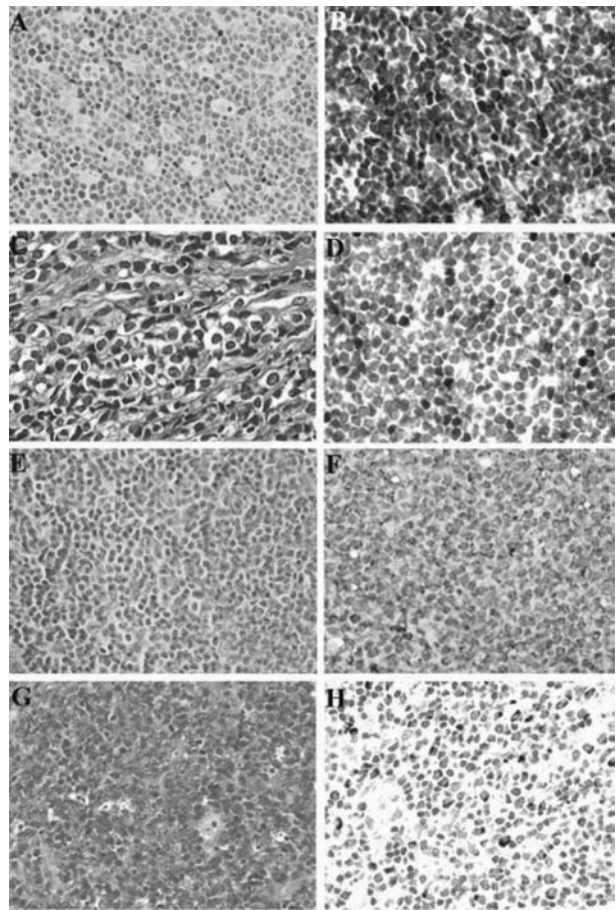


Figure 4. Nuclear SOX11 staining is observed in Burkitt's lymphoma and T-cell prolymphocytic lymphoma but staining is only cytoplasmic in follicular lymphoma and diffuse large B-cell lymphoma. (A,B) Burkitt's lymphoma; (C,D) T-cell prolymphocytic lymphoma; (E,F) follicular lymphoma; (G,H) diffuse large B-cell lymphoma.

SOX11 expression in cyclin D1-negative mantle cell lymphoma

To determine whether SOX11 expression could be a reliable marker for cyclin D1-negative MCL we analyzed SOX11 expression in 12 cases of cyclin D1-negative MCL. Five of the six initial cases examined by microarrays showed very high levels, similar to the remaining cyclin D1-positive MCL (Figure 1).⁸ SOX11 mRNA expression was then investigated in five additional cases of cyclin D1-negative MCL by quantitative RT-PCR using RNA extracted from formalin-fixed paraffin embedded tissues. The five cases showed high levels (mean=4.28; SD=4.38), similar to those observed in conventional cyclin D1-positive MCL obtained from equivalent tissue (mean=12.9; SD=19.46) (*p*=0.39). SOX11 protein expression was examined by immunohistochemistry in the 12 cyclin D1-negative MCL, and all of them showed strong nuclear positive staining similar to that occurring in conventional cyclin D1-positive MCL (Figure 3).

Clinical and pathological characteristics of cyclin D1-negative mantle cell lymphoma

The clinical characteristics of the 12 patients with cyclin D1-negative MCL are summarized in Table 2. Nine patients were males and the median age of the 12 patients was 60 years (range, 39-70 years). B-symptoms were observed in five patients (46%). Generalized lymphadenopathy was the most common form of presentation and extranodal sites were involved in ten patients (83%), bone marrow being the most common site (67%). Serum levels of lactate dehydrogenase were elevated in four patients (36%). All patients received different chemotherapeutic treatments. Case 1 relapsed with peripheral blood, bone marrow and colorectal involvement 26 months after the initial diagnosis and case 12 relapsed with prostate involvement 12 months after the initial diagnosis. After a median follow-up for surviving patients of 38 months (range, 37-60 months), eight patients had died of progressive lymphoma and four patients were alive with disease.

The median overall survival was 71 months. All cases had a diffuse growth pattern, 11 with classical and one with pleomorphic cytology. All tumors expressed mature B-cell markers and CD5. Cyclin D1 was nega-

tive in the tumor cells but staining was detected in occasional endothelial cells or histiocytes. The absence of the t(11;14) translocation was confirmed by FISH analysis in all cases (Figure 5).

We studied mRNA levels of cyclin D1, D2 and D3 in five of the six new cases. We confirmed absence or virtually negative levels of cyclin D1 by quantitative RT-PCR. Notably, high mRNA levels of cyclin D2 (3 cases) or cyclin D3 (1 case) were found in four of the five cases studied, whereas the remaining case showed similar cyclin D2 levels as the cyclin D1-positive tumors.

To determine the potential use of cyclin D2 or D3 protein expression to identify cyclin D1-negative MCL we stained the 12 cyclin D1-negative MCL, 4 conventional MCL and 21 other B-cell lymphomas. Most of the tumors showed nuclear positivity for both cyclins

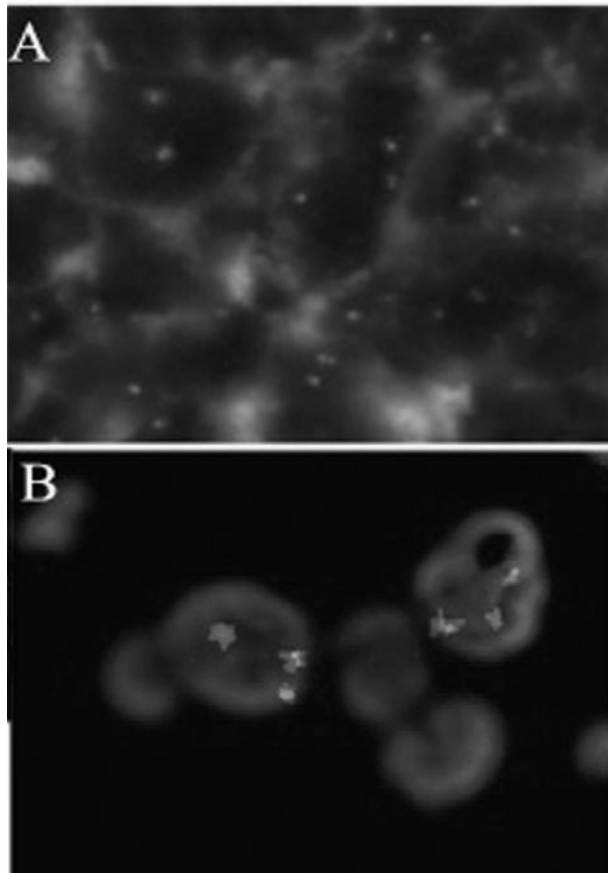


Figure 5. FISH analysis on cyclin D1-negative MCL. (A) *CCND1* break-apart probe showing two fusion signals in each cell; (B) *CCND2* probe showing a split signal pattern suggesting a rearrangement of the gene.

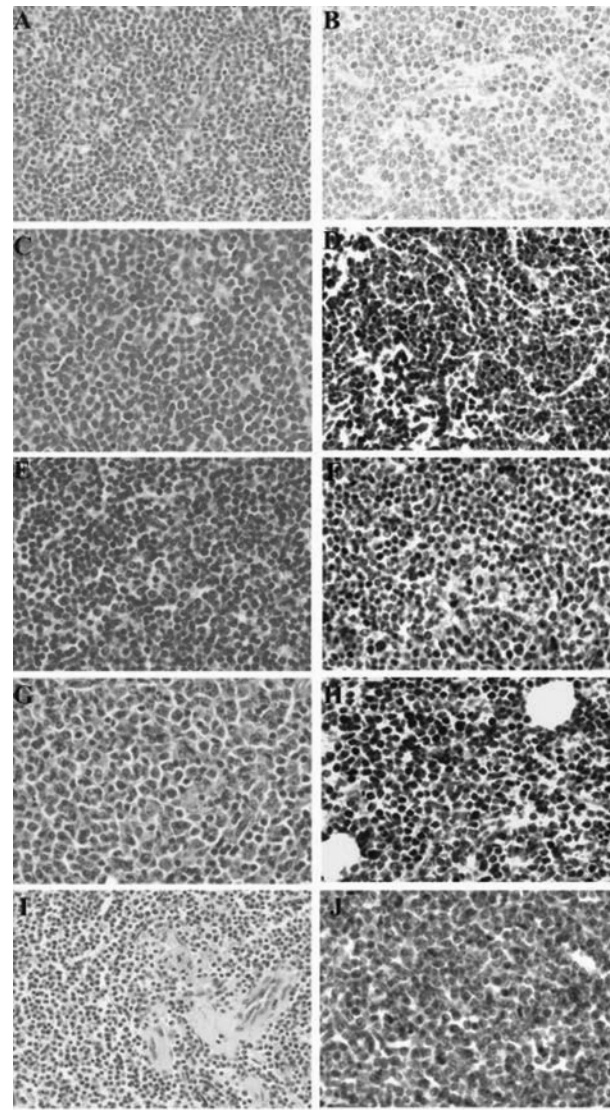


Figure 6. Cyclin D2 protein expression in conventional and cyclin D1-negative MCL and in various lymphoid neoplasms. (A,B) conventional MCL; (C,D) cyclin D1-negative MCL; (E,F) small lymphocytic lymphoma; (G,H) follicular lymphoma; (I,J) splenic marginal zone lymphoma.

or predominantly one of them without clear differences between the cyclin D1-positive or negative MCL and other B-cell lymphomas (Figure 6). We investigated the possible presence of *CCND2* or *CCND3* translocations in the six new cyclin D1-negative tumors by FISH. Only one case (case 10) showed a split signal pattern of *CCND2* in 21% of the cells, suggesting a rearrangement of this gene (Figure 5).

Discussion

Cyclin D1-negative MCL were initially identified by expression profiling studies as small B-cell neoplasms with the morphological, immunophenotypic, and gene expression features of conventional MCL but lacking both cyclin D1 expression and the 11q13 translocation and expressing high levels of cyclin D2 or D3.^{9,20} Subsequent genetic studies demonstrated that cyclin D1-negative MCL may carry chromosomal translocations fusing these two other cyclins to the heavy or light chains of the immunoglobulin genes and that they also exhibit the same secondary genetic aberrations as conventional MCL.^{10,12-14} These observations indicated that cyclin D1-negative and positive MCL share similar genetic features suggesting that they are part of the same biological entity. The number of cases reported is still limited and the clinical characteristics of the patients are not well defined.¹² We have now expanded these observations including five new cases and updating the follow-up of the previously reported patients. We found that most of the 12 cyclin D1-negative cases of MCL occurred in elderly males; typically the patients presented in advanced stage with frequent peripheral blood and extranodal involvement. The clinical behavior was also aggressive with poor response to therapy and an overall survival rate not substantially different from that in patients with cyclin D1-positive MCL.

The aggressive clinical evolution of these lymphomas highlights the need for reliable markers to identify such malignancies and to distinguish them from other small B-cell lymphomas because a different therapeutic management is advocated. Indeed, Yatabe *et al.* observed a significantly better outcome in patients with small B-cell lymphomas resembling MCL than in patients with true MCL.⁸

The differential diagnosis between cyclin D1-negative MCL and other small B-cell lymphomas may be difficult. Morphologically the irregular nuclei characteristic of MCL may be observed in some cases of chronic lymphocytic leukemia (CLL)²¹ or marginal zone lymphoma (MZL).²² CD23 is expressed in CLL but also in occasional cases of MCL.²³ On the other hand, CD5 and CD43 expression, a common feature of MCL and CLL may also occur in MZL.²⁴ Finally, although CD10 or BCL-6 have not been detected in cyclin D1-negative MCL some conventional MCL may express these germinal center markers.^{25,26} On this background, new and reliable biomarkers are of paramount importance.

In this study, we investigated the potential value of

SOX11 expression as a marker for cyclin D1-negative MCL. Two recent studies^{16,17} reported overexpression of this transcription factor as highly specific to MCL because it was detected in around 90% of the MCL examined but in none of the CLL or FL and only weakly in two of 30 DLBCL. To confirm these findings and expand the number of lymphoid neoplasms investigated we first reviewed the expression profile database of the cases examined in the LLMPP consortium. SOX11 was highly expressed in virtually all conventional MCL (98%) but the levels were undetectable in all FL, DLBCL, and PMBL examined. Interestingly, moderate levels of expression were observed in 33% of the BL. We further confirmed these observations by quantitative RT-PCR and immunohistochemistry in additional MCL cases and other lymphoid neoplasms. Thus, nuclear expression of the SOX11 protein was detected in 93% of all MCL examined but in none of the large series of CLL, FL, nodal and splenic MZL, DLBCL T-cell lymphomas and in only one classical Hodgkin's lymphoma. In concordance with the gene expression array studies, we detected variable SOX11 expression in BL. In addition, two of the three T-PLL and all LBL were also positive. However, these tumors are not usually mistaken for MCL.

Like Ek *et al.*¹⁶ we observed immunohistochemical reactivity with a dot-like pattern in the cytoplasm of lymphoid cells in reactive germinal centers and in some lymphomas but notably this pattern was not observed in MCL. The significance of this pattern is not clear but most probably does not correspond to the presence of SOX11 since it was only detected in non-MCL and reactive tissues that do not have detectable *SOX11* mRNA by microarray gene expression profiling or quantitative RT-PCR. Altogether, these findings confirm that high *SOX11* mRNA levels and detection of the nuclear protein are reliable markers of MCL.

These results prompted us to investigate SOX11 expression in our cyclin D1-negative MCL. Interestingly, all of them showed strong SOX11 nuclear protein expression indicating that this may indeed be a useful marker to identify these tumors. Ek *et al.*¹⁶ included a case of apparently cyclin D1-negative MCL in their series. However, this case had a t(11;14) translocation and, therefore, the lack of detection of cyclin D1 was most probably the consequence of a technical problem. This observation suggests that SOX11 may also be a reliable marker for diagnosing conventional MCL when cyclin D1 detection fails for technical reasons.

Gene expression array studies showed that cyclin D1-negative MCL overexpressed cyclin D2 or D3, and some cases carried chromosomal translocations of these genes.^{9,12,13,20} We confirmed the high levels of these two cyclins in the newly studied cyclin D1-negative MCL cases and in one case we demonstrated a cyclin D2 rearrangement by FISH. Cyclin D2 and D3 were detected immunohistochemically in the cyclin D1-negative tumors but also in most non-MCL without marked differences in the intensity of the staining,

probably due to the lower discriminatory power of this technique which would, therefore, be of limited value in the differential diagnosis of these tumors.

In conclusion, we have confirmed the high specificity of *SOX11* mRNA and nuclear protein expression as markers of MCL. The detection of this transcription factor is a useful biomarker for identifying true cyclin D1-negative MCL. Although *SOX11* can also be detected in some BL, LBL and T-PLL, the different morphological and phenotypic features of these malignancies allow easy recognition of the cases of cyclin D1-negative MCL.

Authorship and Disclosures

AM and CR performed research, collected, analyzed and interpreted data and drafted the manuscript, contributed equally to it; EH, DJ, DW, JD, S-SC, ESJ, CR-M, KF, AR, DC and AL-G collected and interpreted data. CB, AV, FS, SD, LR, RB, RDG and LMS performed research and interpreted data; GO, PJ and EC designed research, analyzed and interpreted data, drafted the manuscript and are co-senior authors.

The authors reported no potential conflicts of interest.

References

- Salaverria I, Perez-Galan P, Colomer D, Campo E. Mantle cell lymphoma: from pathology and molecular pathogenesis to new therapeutic perspectives. *Haematologica* 2006;91: 11-6.
- Jares P, Colomer D, Campo E. Genetic and molecular pathogenesis of mantle cell lymphoma: perspectives for new targeted therapeutics. *Nat Rev Cancer* 2007;7:750-62.
- Beà S, Ribas M, Hernández JM, Bosch F, Pinyol M, Hernández L, et al. Increased number of chromosomal imbalances and high-level DNA amplifications in mantle cell lymphoma are associated with blastoid variants. *Blood* 1999;93:4365-74.
- Katzenberger T, Kienle D, Stilgenbauer S, Höller S, Schilling C, Mäder U, et al. Delineation of distinct tumour profiles in mantle cell lymphoma by detailed cytogenetic, interphase genetic and morphological analysis. *Br J Haematol* 2008;142: 533-50.
- Mestre-Escorihuela C, Rubio-Moscardo F, Richter JA, Siebert R, Climent J, Fresquet V, et al. Homozygous deletions localize novel tumor suppressor genes in B-cell lymphomas. *Blood* 2007;109: 271-80.
- Salaverria I, Espinet B, Carrió A, Costa D, Astier L, Slotta-Huspenina J, et al. Multiple recurrent chromosomal breakpoints in mantle cell lymphoma revealed by a combination of molecular cytogenetic techniques. *Genes Chromosomes Cancer* 2008; 47:1086-97.
- Sander S, Bullinger L, Leupolt E, Benner A, Kienle D, Katzenberger T, et al. Genomic aberrations in mantle cell lymphoma detected by interphase fluorescence in situ hybridization. Incidence and clinicopathological correlations. *Haematologica* 2008;93: 680-7.
- Yatabe Y, Suzuki R, Tobinai K, Matsuno Y, Ichinohasama R, Okamoto M, et al. Significance of cyclin D1 overexpression for the diagnosis of mantle cell lymphoma: a clinicopathological comparison of cyclin D1-positive MCL and cyclin D1-negative MCL-like B-cell lymphoma. *Blood* 2000;95:2253-61.
- Fu K, Weisenburger DD, Greiner TC, Dave S, Wright G, Rosenwald A, et al. Cyclin D1-negative mantle cell lymphoma: a clinicopathologic study based on gene expression profiling. *Blood* 2005;106:4315-21.
- Salaverria I, Zettl A, Beà S, Moreno V, Valls J, Hartmann E, et al. Specific secondary genetic alterations in mantle cell lymphoma provide prognostic information independent of the gene expression-based proliferation signature. *J Clin Oncol* 2007;25: 1216-22.
- Bea S, Campo E. Secondary genomic alterations in non-Hodgkin's lymphomas: tumor-specific profiles with impact on clinical behavior. *Haematologica* 2008;93:641-5.
- Wlodarska I, Dierickx D, Vanhentenrijk V, Van Roosbroeck K, Pospisilová H, Minnei F, et al. Translocations targeting *CCND2*, *CCND3*, and *MYCN* do occur in t(11;14)-negative mantle cell lymphomas. *Blood* 2008;111:5683-90.
- Gesk S, Klapper W, Martin-Subero JJ, Nagel I, Harder L, Fu K, et al. A chromosomal translocation in cyclin D1-negative/cyclin D2-positive mantle cell lymphoma fuses the *CCND2* gene to the *IGK* locus. *Blood* 2006; 108:1109-10.
- Herens C, Lambert F, Quintanilla-Martinez L, Bisig B, Deusings C, de Leval L. Cyclin D1-negative mantle cell lymphoma with cryptic t(12;14)(p13;q32) and cyclin D2 overexpression. *Blood* 2008;111:1745-6.
- Rizzatti EG, Falcão RP, Panepucci RA, Proto-Siqueira R, Anselmo-Lima WT, Okamoto OK, et al. Gene expression profiling of mantle cell lymphoma cells reveals aberrant expression of genes from the PI3K-AKT, WNT and TGFβ signalling pathways. *Br J Haematol* 2005;130: 516-26.
- Ek S, Dictor M, Jerkeman M, Jirstrom K, Borrebaeck CA. Nuclear expression of the non B-cell lineage *Sox11* transcription factor identifies mantle cell lymphoma. *Blood* 2008;111:800-5.
- Wang X, Asplund AC, Porwit A, Flygare J, Smith CI, Christensson B, et al. The subcellular *Sox11* distribution pattern identifies subsets of mantle cell lymphoma: correlation to overall survival. *Br J Haematol* 2008; 143:248-52.
- Chuang SS, Huang WT, Hsieh PP, Tseng HH, Campo E, Colomer D, et al. Mantle cell lymphoma in Taiwan: clinicopathological and molecular study of 21 cases including one cyclin D1-negative tumor expressing cyclin D2. *Pathol Int* 2006;56:440-8.
- Sonoki T, Harder L, Horsman DE, Karran L, Taniguchi I, Willis TG, et al. Cyclin D3 is a target gene of t(6;14)(p21.1;q32.3) of mature B-cell malignancies. *Blood* 2001;98:2837-44.
- Rosenwald A, Wright G, Wiestner A, Chan WC, Connors JM, Campo E, et al. The proliferation gene expression signature is a quantitative integrator of oncogenic events that predicts survival in mantle cell lymphoma. *Cancer Cell* 2003;3:185-97.
- De Oliveira MS, Jaffe ES, Catovsky D. Leukaemic phase of mantle zone (intermediate) lymphoma: its characterisation in 11 cases. *J Clin Pathol* 1989;42:962-72.
- Isaacson PG, Wotherspoon AC, Diss T, Pan LX. Follicular colonization in B-cell lymphoma of mucosa-associated lymphoid tissue. *Am J Surg Pathol* 1991;15:819-28.
- Schlette E, Fu K, Medeiros LJ. CD23 expression in mantle cell lymphoma: clinicopathologic features of 18 cases. *Am J Clin Pathol* 2003;120: 760-6.
- Campo E, Miquel R, Krenacs L, Sorbara L, Raffeld M, Jaffe ES. Primary nodal marginal zone lymphomas of splenic and MALT type. *Am J Surg Pathol* 1999;23:59-68.
- Camacho FI, García JF, Cigudosa JC, Mollejo M, Algara P, Ruiz-Ballesteros E, et al. Aberrant *Bcl6* protein expression in mantle cell lymphoma. *Am J Surg Pathol* 2004;28:1051-6.
- Zanetto U, Dong H, Huang Y, Zhang K, Narbaitz M, Sapia S, et al. Mantle cell lymphoma with aberrant expression of CD10. *Histopathology* 2008; 53:20-9.