

1931

## Infections of the hand

Ernest A. Weymuller  
*University of Nebraska Medical Center*

This manuscript is historical in nature and may not reflect current medical research and practice. Search [PubMed](#) for current research.

Follow this and additional works at: <https://digitalcommons.unmc.edu/mdtheses>



Part of the [Medical Education Commons](#)

---

### Recommended Citation

Weymuller, Ernest A., "Infections of the hand" (1931). *MD Theses*. 185.  
<https://digitalcommons.unmc.edu/mdtheses/185>

This Thesis is brought to you for free and open access by the Special Collections at DigitalCommons@UNMC. It has been accepted for inclusion in MD Theses by an authorized administrator of DigitalCommons@UNMC. For more information, please contact [digitalcommons@unmc.edu](mailto:digitalcommons@unmc.edu).

Hand - Diseases  
Ernest A. Weymuller  
1931  
Infections of the  
hand

62


It is quite important that some consideration of the anatomy of the hand in relation to the fascial spaces, be taken up before one can well understand the manner in which infection may traverse from one region to another, which in turn aids greatly in knowing how to adequately treat such infections. Prior to the work of Kanavel, little had been done in the way of scientific study of the anatomy of the hand, particularly of the spaces and synovial sheaths. Following Kanavel's work others have been stimulated to the study of hand infections. By injections, the spaces are dissected easily and their relationship to surrounding structures demonstrated.

ANATOMY AND RELATIONSHIP:-

It is known that five spaces may be found in the hand. On the palmar surface there are three distinct chambers, not communicating in any way with each other, and to these are given the names thenar, hypothenar, and middle palmar spaces. Certain channels will also be found, which may lead directly into them, and certain structures along which pus may pass will be found lying next to these spaces. Upon the dorsum two areas are present which may or may not communicate with each other, one being the dorsal subcutaneous space, while the other is the dorsal subaponeurotic space.

The thenar space, which is on the radial side of the hand, lies upon the adductor muscles of the thumb. The adductor muscles of the thumb are two in number; the adductor obliquus pollicis, and the adductor transversus pollicis. These muscles in general arise from the metacarpal bone of the middle finger and run lateralward to be inserted into the inner side of the base of the first phalanx of the thumb. The thenar space is partially covered by the short

muscles of the thenar eminence. Immediately over the space are the flexor tendons of the index finger, and lumbrical muscles, along with accompanying digital vessels and nerves. The space extends ulnarward to the metacarpal bone of the middle finger, and radialward to about the level of the palmar surface of the bones where it is limited. It is important that this limitation




(Fig. 1.) Diagram demonstrating the thenar and middle palmar spaces. (After Kock.)

is present, for it prevents spread from the thenar space to the dorsum of the hand and also vice versa. The thenar space does not extend into the arm. Drawings demonstrate its extent as being distally to about a thumb's breadth of the web of the fingers, and proximally to about two thumb's breadth of the wrist flexion crease. It is important to know the surface anatomy of these fascial spaces in order to ascertain the location of entering the spaces surgically.

The middle palmar space lies on the ulnar side of the hand

on its palmar side. This space lies deep in the palm upon the interosseous muscles and anterior interosseous membrane. Superficial to the space are the flexor tendons of the middle and ring fingers, and the lumbrical muscles. A thin fibrous sheath is found to lie between these structures and the space. The middle palmar space extends from the middle metacarpal bone to the radial side of the metacarpal bone of the little finger, and is found to extend distally and proximally to about the same levels as the



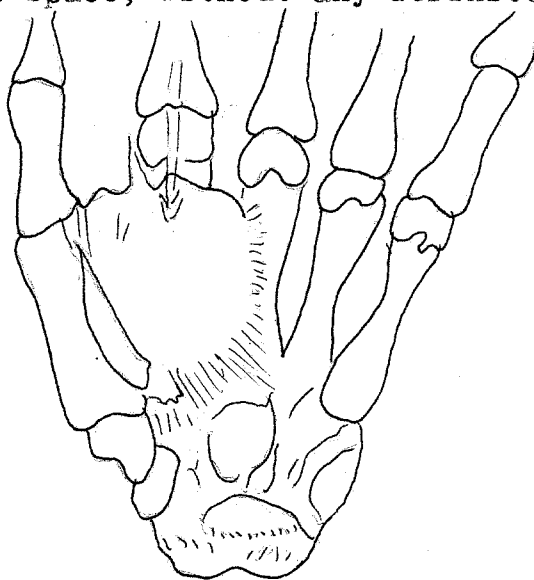
(Fig. 2.) The relation of the flexor tendon sheaths and the radial and ulnar bursae to the superficial markings of the hand. (After Kock) The small diagram shows the communication between the ulnar and radial bursae, which is present in about sixty percent of the cases (After Best)

thenar space. The space is partially covered by the overlying distal end of the ulnar bursa. The middle palmar space is probably the most important space in the hand and its relation to the thenar space as well as the other spaces is of extreme importance.

The middle palmar and thenar spaces are separated from each other at the middle metacarpal bone by a firm septa so that neither

one communicates with the other, nor does either overlap to the other side of this line formed by the metacarpal bone of the middle finger. It has been explained above, that the two spaces are found to lie on similar floors and are covered superficially by similar structures.

The hypothenar area is a distinctly localized space which does not communicate with any other space or tendon-sheath. The dorsal subcutaneous space, without any definite boundaries is

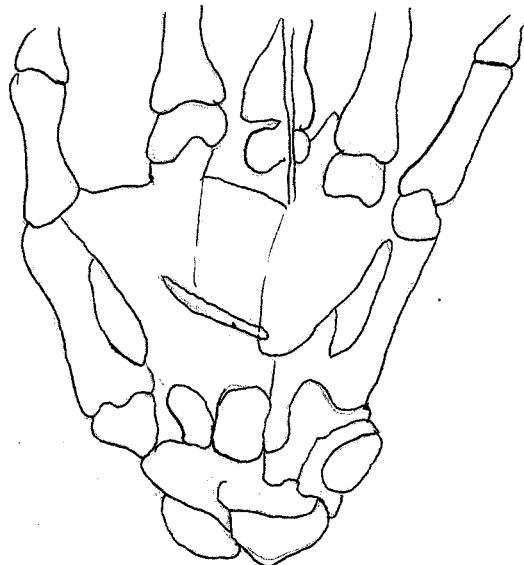


(Fig. 3.) This schematic drawing demonstrates the usual path of infections in the tendon-sheath of the index finger. (After Kanavel)

found to lie dorsally and pus traveling from here may spread over the entire dorsum of the hand. The dorsal subaponeurotic space is found to lie upon the metacarpal bones, being covered superficially or dorsally by a dense tendinous aponeurosis of the extensor tendons. This space is the shape of a truncated cone, with the smaller end at the wrist and the broader end at the knuckles. These three spaces are of lesser clinical importance.

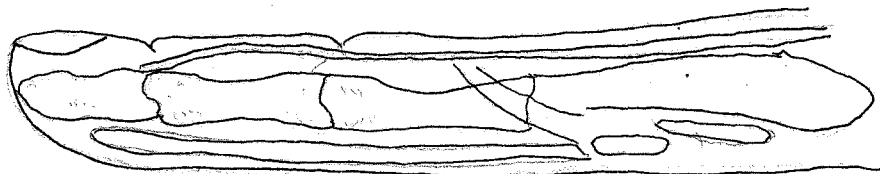
The tendon-sheaths upon the flexor surfaces of the fingers are most important from a clinical as well as a surgical standpoint. The sheaths of the index, middle, and ring fingers extend,

from a point just distal to the distal flexion crease of the fingers, into the palm, approximately a thumb's breadth proximal to the web. At the distal portion of the palm there is a sheet of dense tissue enclosing the ends of the sheaths with the lumbrical muscles. To each side of the palmar ends of the tendon-sheaths are the lumbrical spaces. The tendons lie in close apposition to the palmar



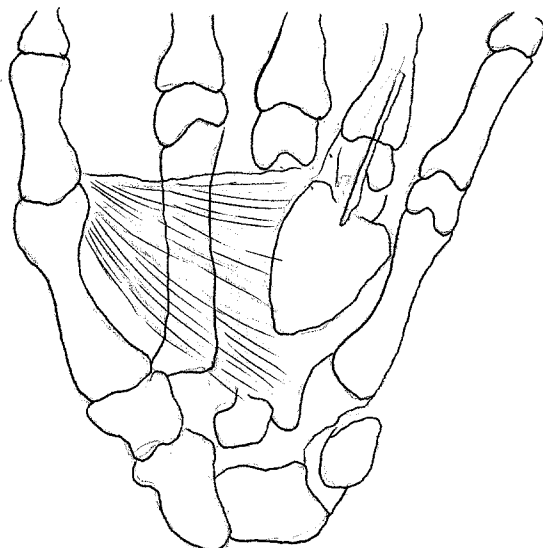
(Fig. 4.) This schematic drawing demonstrates the usual path of infections in the tendon-sheath of the middle finger. (After Kanavel)

surface of the phalanges and are only separated from the bone by a thin layer of connective tissue.



(Fig. 5.) Illustration in general of the anatomical relations of the tendon-sheaths to surrounding structures as well as to the fascial spaces of the palm. (After Best)

The tendon-sheath of the long flexor of the thumb begins at a point just distal to the base of the distal phalanx and accompanies the flexor pollicis longus through the palm to end approximately one thumb's breadth above the anterior annular ligament in an expansion known as the radial bursa. About five



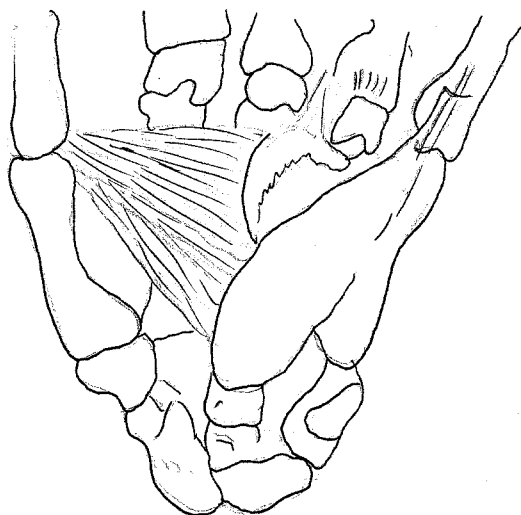
(Fig. 6.) This schematic drawing demonstrates the usual path of infections in the tendon-sheath of the ring finger. (After Kanavel)

per cent of the cases show that there is a separation of the sheath into two parts at about the middle of the metacarpal bone. (Kanavel). Over the first metacarpal bone the bursa lies between the flexor pollicis brevis and the adductor obliquus. Here it also is found to lie superficial to the proximal end of the thenar space. The bursa ends in a blind pouch under the tendons and upon the pronator quadratus which separates it from the radio-ulnar joint.

The tendon-sheath of the flexors of the little finger begins just distal to the distal flexion crease of that finger and extends proximally to become continuous, in the greater part of the cases, with the ulnar bursa. The ulnar bursa which is a sac



spreading out over the metacarpal bone of the ring finger and the base of the middle metacarpal, passes under the anterior annular ligament and extends about a thumb's breadth above this ligament, lying, in relation to the lower end of the ulna and radio-ulnar joint, on the pronator quadratus muscle. The ulnar bursa does not completely envelop the tendon sheaths of the flexor tendons, for it is pushed radialward, as it were, forming three indistinct pockets. This fact is found to be inconstant. The exact arrangement of the tendon-sheaths in the wrist region is



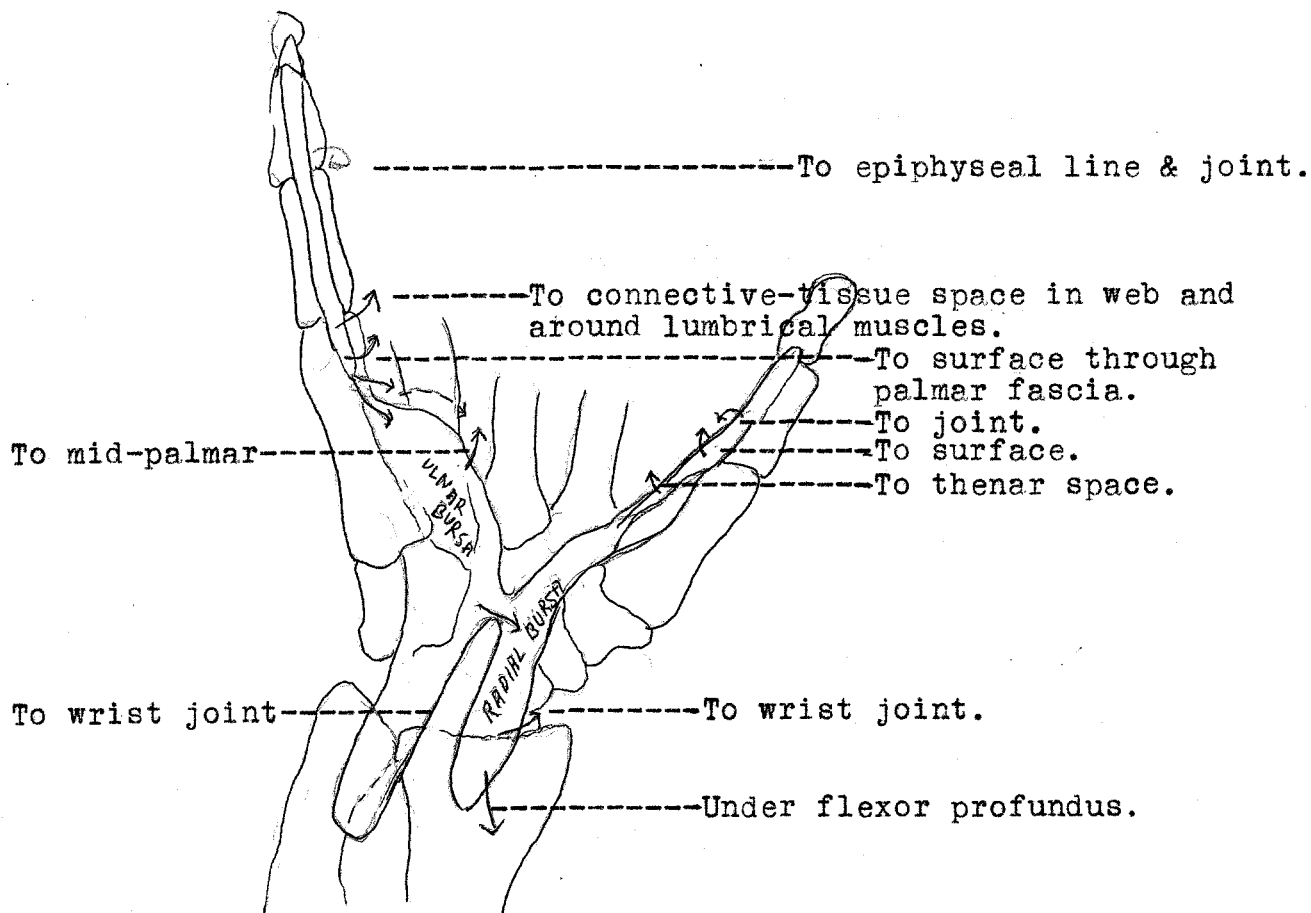
(Fig. 7.) This schematic drawing demonstrates that infection in the tendon-sheath of the little finger may pass to the middle palmar space or the ulnar bursa, or that infection in the ulnar bursa may pass to the middle palmar space. (After Kanavel)

a subject of considerable variation. About fifty to sixty per cent of the cases show that the radial and ulnar bursae communicate by way of an intermediary sheath. This may permit infection to travel from thumb to the little finger and vice versa.

There are six flexor sheaths on the dorsum of the hand, one for each of the tunnels under the posterior annular ligament, which extend about three centimeters distal to the ligament.

These spaces are relatively unimportant from a surgical standpoint.

The lymphatics of the hand are small and numerous, covering the hand like a fine meshwork. Of particular interest is the fact that the lymphatic channels take the shortest course to the back of the hand and from here the lymphatics are drained through



(Fig. 8.) Schematic drawing, showing probable extensions from infection of the tendon-sheaths of the thumb and little fingers. (After Kanavel)

several large channels that pass upward to the axilla. It is found that the lymphatics of the little and ring fingers pass first to the glands in the antecubital and epitrochlear regions, and from here to the axillary glands, so that infection involving the ulnar side of the hand may show adenopathy in these regions. The lymphatics of the thumb and index finger most usu-

ally drain directly upward into the axillary glands.

The knowledge of the relationship of the different spaces of the hands is of extreme importance, for it aids the physician to ascertain where a given primary infection may travel and consequently affords information which is essential for adequate early diagnosis and prognosis. The middle palmar space is most often involved secondary to tendon-sheath infection of the middle, ring, and little fingers. Occasionally, tendon-sheath infections of the middle finger rupture first into the lumbrical space between the index and middle finger, and then by secondary rupture may involve the thenar space. Primary infections in the index finger tendon-sheath rupture into the thenar space. The thenar space may be involved by a rupture of the tendon-sheath of the flexor pollicis longus, but here the pus is more likely to come to the surface at the web. Ordinarily infections in the sheath of the flexor pollicis longus tendon pass up the radial bursa into the forearm, as is the case when infection is found in the ulnar bursa. Middle palmar space infections under great pressure are found to rupture into the forearm, the pus being found to lie over the pronator quadratus muscle beneath the deep flexor tendons. This is not true in case of thenar space infections, for these remain localized even under extreme pressure. Extension from the thenar to the middle palmar space is not at all common. Drawings help to demonstrate some of these facts.

#### SYMPTOMATOLOGY AND DIAGNOSIS:-

By reason of their frequency and severity, lymphatic infections and infections of the tendon-sheaths and fascial spaces will be dealt with most exclusively in dealing with the diagnosis and treatment given here in this paper.

In lymphatic infections, the hand rapidly becomes swollen, with redness, and tenderness upon the dorsum. Some red lines of lymphatic channel infection may be seen running up the arm to the axilla or elbow regions. The fingers may be moved freely without pain and there is not tenderness over the tendon sheaths or fascial spaces. If the lymphangitis is of a more superficial type, there is less swelling. Preceding such symptoms the patient gives a history of slight abrasion or injury to the hand, and following this such systemic symptoms as headache, thirst, sleeplessness, restlessness, and fever occur.

It is often difficult to differentiate a beginning lymphangitis from a tenosynovitis, and this must be kept in mind, for it is most important that a diagnosis be made before much time has passed by, allowing more serious damage to result. The cardinal symptoms and signs of acute tenosynovitis are briefly as follows:- (1) Excessive tenderness over the course of the sheaths, this being the most important single sign; (2) the finger is held in the position of a rigid flexion; (3) excruciating pain on passive extension, which is most marked at the proximal end of the tendon-sheath. Here also systemic symptoms such as malaise, slight chills and fever show themselves.

Extension to the radial bursa is shown by increased swelling and tenderness in the thenar eminence and along the sheath of the flexor pollicis longus. Involvement of the ulnar bursa is shown by great edema, especially on the dorsum, with fullness in the palm, but the normal palmar concavity still remains. Great tenderness is noted over the bursa and the wrist becomes fixed. The radial bursa may become involved and would then show radial tenderness. Involvement of the forearm is characterized by a brawny induration of the tissues. Pus may come to lie superficially.

In lumbrical space involvement, swelling is found to be present over the sheath in the web of the finger. These infections do not remain localized long, but spread into the thenar or mid-palmar spaces as has been described previously.

Infections or abscesses in the spaces may occur simultaneously with tendon-sheath infections, or are occasionally found to occur by direct inoculation. Pain over the spaces is not so limited as to area as in tenosynovitis. This pain may become less in several days, due to pressure on the nerves. We are often aided in a diagnosis here by a known previous tendon-sheath infection. Obliteration of the normal palmar concavity, with an actual bulging is found in middle palmar involvement. In thenar space involvement, a bulging from the adduction crease of the thumb is characteristic.

#### PROGNOSIS:-

In lymphatic infections, the final outcome is predicted only by watching the blood picture. If there is an immediate increase of the mononuclear neutrophilic cells with a slow decrease after eight hours, and an increase of polynuclear cells after eight hours, the physician should feel safe in giving a good prognosis. On the other hand if there is a continuous decrease in numbers of these cells, a bad prognosis should be given.

In tendon-sheath and fascial space infections, it is very nearly impossible to state from a study of the literature, what proportion of cases may hope for a satisfactory local outcome. A complete functioning hand can be promised in those acute infections of the hand, which do not involve the tendon-sheath, unless necrosis of the tissue has taken place or joint involvement has occurred. In tendon-sheath infection, however, the results are not nearly so good. In the thumb, even though the function of the

flexor longus pollicis is lost, the finger will not be seriously impaired, since the smaller muscles of the thumb will afford great range of movement. The patient must be warned that, in many cases, the course may be long and that the ultimate restoration of function depends much upon continued and faithful application of after-treatment.

TREATMENT:-

Preliminary treatment of minor as well as major injuries is of extreme importance. Every patient injured should apply iodine or some other suitable antiseptic and a sterile bandage to the wound until the abrasion has healed. This procedure would prevent many serious hand infections from developing. This system could be instituted in all factories with little difficulty.

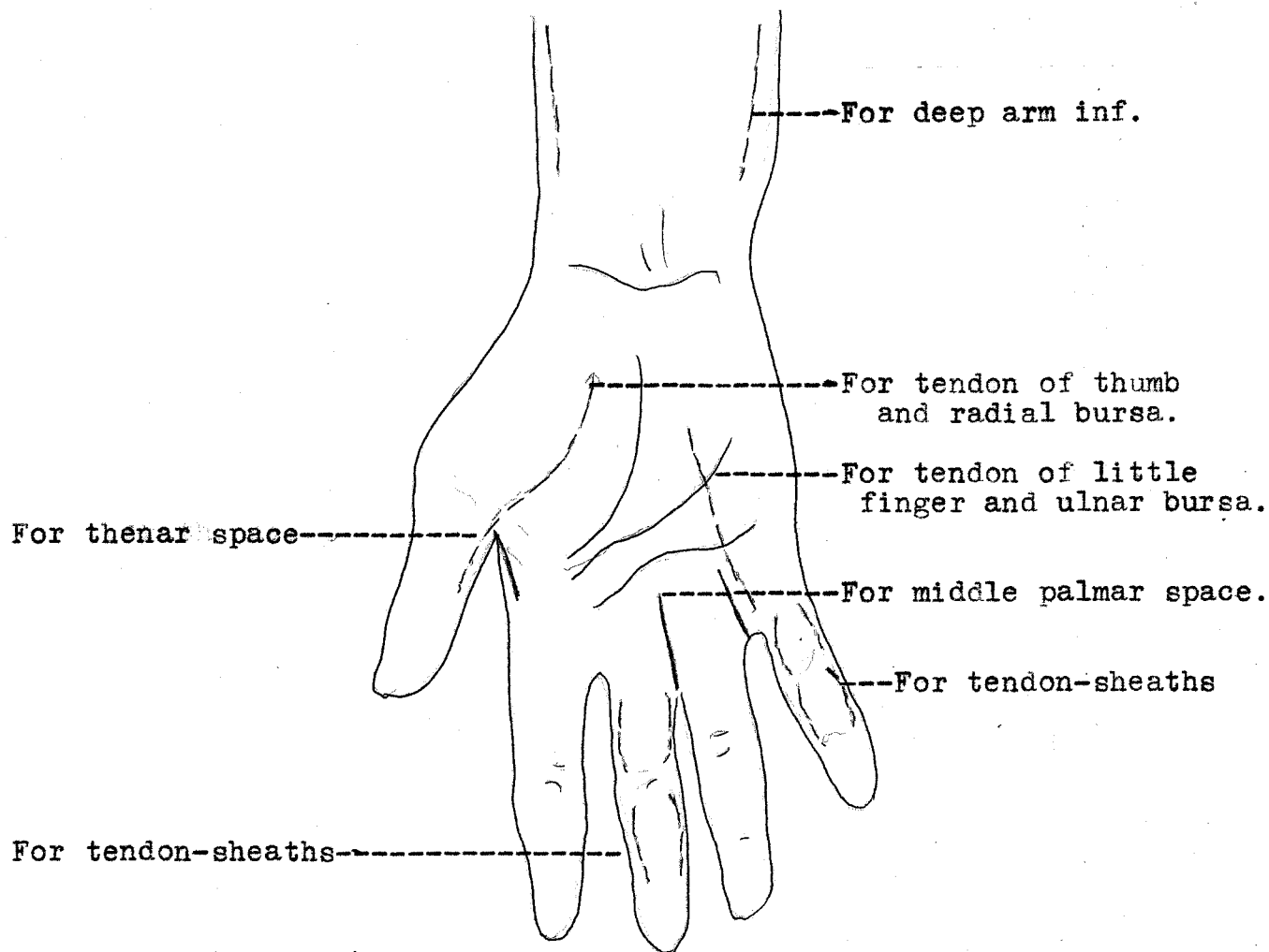
It is well known that muscular action aids in the travel of lymphatic vessel contents, and therefore it is essential that the infected part be put to complete rest. This is also advisable, because of the great relief from throbbing pain that results when the hand is elevated and emobilized. The systemic use of drugs is of little or no value. The question of passive hyperemia is one of debate, being most strongly supported by German surgeons. It is most effective in those cases where toxic absorption is evident. Klapp has emphasized the value of suction cups used over a localized infection, but it is a question whether or not any great benefit can be derived from such a procedure.

The application of hot moist dressings is in common use and is most beneficial in a large percentage of the cases. Most attendants use hot boric acid in dressings in preference to potassium permanganate, alcohol, or bechloride. The results obtained from hot boric acid dressings is mostly due to the moist heat given off to the tissues rather than to any chemical action of the boric

acid itself. The application of hot boric acid dressings is useless and harmful to the tissues after the process is under control, since it tends to favor congestion, which if long continued produces a soggy, infiltrated hand, in which absorption is slow favoring chronic infection and consequently a much deformed and functionless hand. After the infective process has subsided and the tissues show evidence of congestion, it is well that a dressing saturated with a weak solution of alcohol or equal parts of alcohol and glycerin be applied. This procedure aids in dehydration. If there is a foul discharge, a 1 to 2000 potassium permanganate dressing is advisable. Wright has suggested the use of a five per cent solution of sodium chloride in suppurating wounds. To prevent clogging of the meshes of the gauze with coagulated serum, a 0.5 per cent solution of sodium citrate may be added to the hypertonic salt solution dressing. In wounds where there is much necrotic tissue, Dakin's solution, properly applied is of material benefit. This solution must not be applied over non-necrotic tendons since it may favor their destruction.

When the diagnosis has been made, immediate incision, if made in the proper location is the method of choice of all means of treatment. This is always the case in tenosynovitis. The operation should be done in a bloodless field, which may be obtained by the use of a Martin bandage. This bandage may be loosened slowly thus preventing rapid absorption and aiding in producing a passive hyperemia. General anesthesia is much preferred for it permits adequate complete surgical opening. Hypodermic injection, in local anesthesia, may cause spread of the infection and, therefore, of course, is not advisable. To establish drainage of the tendon-sheaths of the fingers the incision should be made well to the side, so as to

avoid the digital nerves and blood vessels, and, also, to prevent herniation of the tendon from its sheath. If the flexor sheaths of the thumb or little finger are involved, it is well that the incision be extended upward into the bursae.

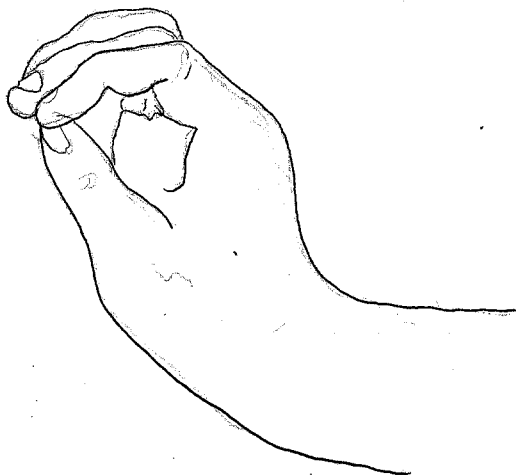


(Fig. 9.) Schematic drawing illustrating the proper locations for incision in draining the tendon-sheath, bursae, and space infections.

One should avoid cutting through the muscles of the thenar eminence and, therefore, should curve the incision inside the eminence as shown in fig. 9. Incisions are often necessary in the forearm in these cases of bursae infection. The incision is always made at the sides, (through and through incision occasionally) for the pus lies beneath the flexor tendons.



Drainage of the middle palmar space is accomplished by retracting the blood vessels of the middle finger to the radial side, and the corresponding structures of the ring finger to the ulnar side, thus exposing the space into which a direct incision may be made. It is often better to use blunt dissection by means of forceps, to prevent unnecessary damage to the vessels. To enter the thenar space the incision is made lengthwise with the web between the thumb and index-finger. With infections of the dorsum of the hand, adequate drainage should be instituted directly over the site of infection.



(Fig. 10.) The position of function. (After Kanavel)

To establish drainage, after the incision has been made, vaseline gauze may be inserted into the opening. These strips of gauze should not be left in the wound more than forty-eight hours. The common habit of squeezing wounds in order to force out pus should be condemned. After the first few days, the application of dry heat is often helpful and gives the patient much comfort.

During the course of the treatment it is most important that the hand, wrist and fingers should be placed in the position of function. (See Fig. 10.) The fingers should be slightly flexed,

the thumb abducted and the hand extended in the "cock-up" position. Such a position always gives the best final results, and leave the patient with a good functioning, or nearly so, hand. Too much care cannot be taken in the after and follow-up treatment of hand infections. Massage, exercise and dry heat are of great help in obtaining a satisfactory after-treatment result.

It is seen that knowledge of hand infections is very important to a physician, since often their severity results in functionless hands, which, of course, is a great handicap, especially to a working man. Every physician should devote his extreme attention to this subject.

#### BIBLIOGRAPHY:-

- "Diagnosis and Treatment" (S.L.Kock) Journal of Indiana M.A.  
21: 137-145. 1928.
- "Preventing Contractures after Infection" (S.L.Kock) J.A.M.A.  
88: 1214-1217. 1927
- "Clinical Infections of the Hand" (A.B.Kanavel) J. Iowa M. Soc.  
17: 4-8 1927.
- "Surgical Anatomy" (J.B.Deaver)
- "Anatomy and Clinical Study" (R.R.Best) Ann. Surg.  
89: 359-78 1928.
- "Diagnosis and After-Treatment" (S.L.Kock) J. Kansas M.Soc.  
28: 10-16. Jan. 1928.
- "Important Cellular Spaces" (M. Iselin) Ann. Anat. Path.  
4: 603-613. 1927.
- "Tenosynovitis and fascial space abscesses" (R.T.Scott)  
Northwest Med. 28: 317-322. 1929.
- "Management" (H.H.LeSeur) Am. J. Surg. 2:38-42. 1927.
- "Anatomy" (Gray)
- "Diagnosis and Treatment" (S.L.Kock) J. Med. 9: 116-124. '28

**RECEIVED**  
**UNIVERSITY OF NEBRASKA**

APR 1931

**OFFICE OF THE DEAN**  
**COLLEGE OF MEDICINE**