

1938

Nyctalopia and its relation to hypovitaminosis

Franklyn H. Johnson
University of Nebraska Medical Center

This manuscript is historical in nature and may not reflect current medical research and practice. Search [PubMed](#) for current research.

Follow this and additional works at: <https://digitalcommons.unmc.edu/mdtheses>



Part of the [Medical Education Commons](#)

Recommended Citation

Johnson, Franklyn H., "Nyctalopia and its relation to hypovitaminosis" (1938). *MD Theses*. 668.
<https://digitalcommons.unmc.edu/mdtheses/668>

This Thesis is brought to you for free and open access by the Special Collections at DigitalCommons@UNMC. It has been accepted for inclusion in MD Theses by an authorized administrator of DigitalCommons@UNMC. For more information, please contact digitalcommons@unmc.edu.

**Nyctalopia
and its Relation to
Hypovitaminosis A**

Franklyn H. Johnson

**Announcement
Senior Thesis Presented to the
College of Medicine
Omaha, 1938**

Table of Contents

I. Introduction -----	Page 1
II. Definition & History-----	3
III. Incidence-----	8
IV. Etiology & Physiology -----	10
1. Congenital	
2. Symptomatic	
3. Idiopathic	
a. Physiology of retina	
b. History of vitamin A	
c. Physiology of vitamin A	
V. Pathology-----	30
VI. Symptoms -----	35
VII. Diagnosis-----	37
VIII. Treatment-----	43
IX. Significance-----	48

480946

Nyctalopia, and its Relation to Hypovitaminosis A.

Introduction:

In preparing this brochure, I find that night blindness has undergone an interesting process of evolution. The early literature dealing with this subject considers it a definite clinical entity. Numerous etiological factors are ascribed to it, and the methods of treatment are probably even more numerous.

With the recognition of the deficiency states and the discovery of vitamins, night blindness ceases to be a clinical entity and is considered a symptom.

After it was discovered that vitamin A was the precursor of visual purple and that this latter substance functions in scotopic vision (56), then the symptom night blindness assumes a new and different role and one of considerably more significance.

The degree of night blindness is apparently dependent upon the degree of vitamin A deficiency and this symptom now serves as a very delicate test for determining the latent forms of this deficiency (31). With the aid of special apparatus this "retarded dark adaptation" may be accurately measured. Workers employing this method of diagnosis have reported an incidence of vitamin A deficiency varying from 21% to 79% (32)(34). This has served as a new impetus to the study of vitamin deficiency states as is apparent and well shown by the recent publications.

Thus a review of the history, chemistry, and physiology of

vitamin A; the clinical and pathological aspects of vitamin A deficiency; the history, mechanism, and significance of night blindness has been attempted.

This review has not exhausted the literature and therefore is not complete. Foreign authors have contributed extensively to this particular field, but only a small portion of this literature has been reviewed, due to my inability to read it. However, translations have been used when found and the original article recorded when possible.

Definition and History

Nyctalopia is a form of visual affection in which the sensibility of the retina to light is diminished. (1).

Hippocrates is thought to be the first to use and define the term, which appears five times in the Hippocratic collection(2). However, the curative effect of liver upon this affection was well known to antiquity, as it is mentioned in Eber's Papyrus about 1500 B. C. (3)

Hippocrate's interpretation of Nyctalopia was, "Those who see at night." (2) Since then much confusion has resulted from confounding the term "Hemeralopia" with "Nyctalopia."

The cause of the confusion would seem to lie in the fact that the word possesses a two-fold etymology: according to one derivation meaning "night-eye" and according to another derivation meaning "night blind eye." (1) However, the references dealing with the etymology are not exactly consistent. There is a choice of two views. These views coincide in that the word is derived from two Greek words: the one meaning "the night" and the other meaning "the eye." The letter which is the connecting link between the two words is the rho on which the authorities differ. One group contends that it is intended as a privative, the other that it is inserted simply for euphony. (2)

Greenhill studying the etymology of the word contends that it is quite clear that the connecting letter is meant as a privative. (4)

Galen, defining Hippocrate's meaning of the word, tells us

that nyctalopia means "night blindness" (4) and numerous other authors agree with this latter interpretation. (5) (6)

All the ancient Greek medical writers, except Hippocrates, and nearly all the Latin medical authorities down to the end of the fourteenth century, and other authors down to the middle of the seventeenth century define nyctalopia in the sense of night-blindness. In the eighteenth century the term hemeralopia was frequently used. The explanation for this extraordinary alteration is that before the sixteenth century the works of Hippocrates were not accessible and thus rarely consulted. Although Hippocrates was held in high esteem by Greek and Latin physicians, he was not studied a great deal in the middle ages. Galen's definition of nyctalopia (night Blindness) was unquestioned until Mercurialis, 1588, and Foesuis, 1595, published their edition of the Hippocratic writings. From this time on more attention was given the Hippocratic writings, and in the seventeenth and eighteenth centuries, medical authorities appealed to them in the original. (7)

Greenhill further states, "Hemeralopia is found only once in the ancient Greek and Latin Literature and it is impossible to decide the sense in which it is used in that passage." (40

Guthrie, honorary secretary of nomenclature states, "Indeed there seems no need to retain the term 'hemeralopia'...." (8)

Dorland's medical dictionary (seventeenth edition) defines nyctalopia as night blindness and hemeralopia as day blindness (9) In view of the evidence set forth for the former definition it is

interesting to find that by far the greater portion of the literature dealing with night blindness refers to it as hemeralopia, including the Quarterly Cumulative Index Medicus.

It is interesting to find that the knowledge of the cure of night blindness is almost as old as medicine. The following curious passage, which occurs in Eber's Papyrus (about 1500 B.C.), was unearthed by Van Leersum in 1924: "Because the unknown disease was cured by the roast liver of an ox, the disease was supposed to be night blindness" (10) Hippocrates perscribed ox liver in the raw form dipped in honey. (11) Thus, by comparison, Hippocrates comes late in the history of the disease.

The relation of night blindness to malnutrition was early recognized. It appeared under conditions of poor nourishment among prisoners, slaves in Brazil, and sailors on long voyages. It is also recorded in epidemic form in Russia during the long Lenten fasts. (12)

Night blindness is also designated by the terms: "moon blindness" and "nocturnal amaurosis." It was considered to have the same causative factor as snow blindness. (13) It was also thought to be due to paresis of the muscles of accommodation, (14) color of the eye, (6) eating hot rice, (15) sleeping with the face exposed to the sunshine or to the moonlight, (15), (16), (17) and miasmatic influences. (18) It was noted to be associated with nephritis and pregnancy, (19) and scurvy. (15) In the last condition it was thought that, due to the blood changes, the humors

of the eye were clouded and became, "ill adapted to the transmission of weak streams or pencils of light." (15)

In 1863 Bitot described the whitish gray spots on the scleral conjunctiva, which now bear his name. It was observed that they often disappeared when the night blindness disappeared, so he felt that there must be some relationship between the two conditions. He felt that these xerotic coverings of the eye reduced the transparency of the cornea to such an extent that diminished illumination could not penetrate. (20) Netter, a Frenchman, did not agree with this interpretation. He explained that this could not be correct because he had several patients who suffered from night blindness but who did not have xerosis. In the course of time ophthalmologists concluded that all three conditions; xerophthalmia, xerosis, and night blindness were different degrees of the same disease. This is still the point of view generally accepted. (12)

The congenital and hereditary forms of nyctalopia were also recognized and classified by Zimmerman in 1883. (18)

The prognosis in idiopathic type was usually favorable, the duration of the disease averaging two to three months. (21) The tendencies toward recurrence and spontaneous cure were well known and it was observed that the general health of the individual did not suffer in the idiopathic cases. The appearance of the eye did not always indicate the state of the disease. Cases of long duration usually had widely dilated pupils, which were often immobile. (15) It was observed that ophthalmoscopic examination

was negative. (21)

Treatments were as varied as were the supposed etiological factors. In treating night blindness associated with scurvy lime juice was squirted in the eyes. Some employed water or urine lavage, eye poultices made of part of the bullocks liver, (21) tonics of iron and quinine, (18) blue colored glasses, and abundance of animal food and cod liver oil in the diet. (22) Camphor was considered specific for a time. (13) Still others employed blisters to the temples, and cathartics, the former procedure repeated twelve times if necessary. (23) (24). It was observed that in some cases in which the scurvy was treated with lime juice, the night blindness cleared spontaneously. (15)

Incidence

Forbes in 1811 is the first to give any definite figures on the incidence of this condition. He found it in the proportion of one to twenty among seamen. (21)

Night blindness was considered a disease of seamen, especially of tropical seamen. It was reported as being common in the East and West Indies and all tropical countries. It was also known to occur in soldiers. (15) (25) (26)

Featherstonhaugh in 1887 considered essential nyctalopia as rare. (27)

Bloch in 1917 was of the opinion that xerosis and night blindness had a high incidence in Denmark, as much as their dairy products are exported and people resort to synthetic substitutes. (28)

Smith in 1921 reports an incidence of night blindness of 8% in France and 10% in Germany. (29)

With the advent of the deficiency diseases we find night blindness to be intimately associated with avitaminosis-A, and the increase of incidence seems somewhat proportionate to the improvement of diagnostic methods.

Moore in 1932, attempted to determine the incidence of vitamin A deficiency in the United States by determining the vitamin A content of livers of accident cases. He found 24% of the cases to be deficient. (30) A year later the questionnaire was sent to fifty of the leading ophthalmologists of this country and only eight cases of night blindness had been reported. (31)

Jeans and Zentmire in 1934 examined a small group of children using the Birch Hirschfeld photometer and found 21% to have subnormal readings. (32)

Park in 1935 studied 275 cases using the photometer and concluded that a large percentage of the population were deficient in vitamin A. (33)

Perhaps the most representative study is that of Jeans and Zentmire in 1936 on a group of 404 Iowa children. Using the photometer they found subnormal readings in 26% of the rural group and 53% of village group; 56%, 63%, and 79% in the upper, middle, and lower economic levels of the urban group. (34)

Jeghers in 1937 also employing the photometer found 28% to 41% to have subnormal readings. (35)

According to Spence night blindness appears to have no definite seasonal incidence, but seems more prevalent in the spring and summer months. This he explains by the extra strain of bright sunshine during these months. (36)

Jeghers again somewhat later in 1937, using the biophotometer examined a group of 162 medical students at Boston University and found 35% to have subnormal photometer readings, and 12% showed clinical evidence of vitamin A deficiency. (37)

Jeans and associates in their second study in 1937 also employed the biophotometer and reported 24% to 34% of the children studied to have subnormal readings. (38)

Etiology and Physiology

The etiology and physiology of essential night blindness are so intimately associated that I have chosen to discuss them simultaneously and under one heading.

We are primarily concerned with the idiopathic type of night blindness in this paper. The symptomatic and congenital types of night blindness will be considered only very briefly.

Congenital:

True congenital night blindness is a congenital, hereditary, non progressive condition, affecting both males and females. (39)

Retinitis pigmentosa sine pigmento may simulate congenital night blindness and some confusion is found in the literature due to this simulation. This is illustrated by Bordley who describes a family of nyctalopes who manifested a congenital, hereditary, progressive type of night blindness. (2)

Retinitis pigmentosa sine pigmento presents a gradual attenuation of the retinal vessels, progressive optic atrophy, night blindness, and finally total blindness, just as found in retinitis pigmentosa, except that the migration of the pigment into the retina is absent. This sine pigmento type further resembles the congenital type in that it frequently occurs in several members of the same family. The distinction between the true congenital night blindness and retinitis pigmentosa sine pigmento, is that in the former condition, the fundus shows no evidence of retinal or optic atrophy and it is non progressive, while the latter condition

does show evidence of atrophy and is slowly but surely progressive.

(19)

Morton in 1893 reported two cases of congenital night blindness. In this instance he was able to trace the condition back several generations. It affected only the males and they were all light complexioned. There were no fundic changes and no color blindness. However, they were myopic and the visual fields were found contracted. (40)

In 1898 Symonds reported two cases of congenital nyctalopia, again affecting only the males of the family. It was hereditary and there was a history of consanguinity in the family. There were no pigmentary changes, but, even though the characteristic signs were absent, he made a diagnosis of retinitis pigmentosa (41). These cases have probably been confused with retinitis pigmentosa sine pigmento as described by Fuchs.

Sinclair in 1903 reported a family of five generations who had congenital non progressive night blindness. He attempted to explain the condition as an inherited diminution in the photochemical activity of the retina. (42)

In 1906 Nettleship reported a family of nine consecutive generations that suffered from night blindness. This report consists of a pedigree of 2,121 persons. Of that group seventy-two males and sixty-two females were night blind. This was of the non-progressive type and there were no fundic changes. (43) In 1912 he published another article on congenital night blindness.

Here he gives a classification of two types: One is transmissible from generation to generation, without a break, to children of either sex. This he calls the ambisexual type. The other type is confined to males, but transmitted only by mothers of normal sight. This group is always associated with myopia. (39)

Tagari and associates measured the dark adaptation in several cases of hereditary night blindness and found that after two hours in the dark these individuals showed no change in the threshold. So rod adaptation seems to have been mainly lost or at least greatly retarded in speed. (44)

Symptomatic:

Night blindness is frequently found as a symptom of numerous diseases. Therefore, its occurrence is not due to one, but to many factors. (45). These pathological states may be divided into ocular and extraocular groups. In the ocular group night blindness is found associated with glaucoma (46), choroideremia (47), syphilitic retinitis (45), spastic disorders of retinal arteries (48), in monocular patients (49), detached retina, retinitis pigmentosa, optic atrophy, optic neuritis, choroiditis (50), and opacities of the media and cornea (51). Under the extraocular group are nephritis, diabetes, anemia, cachexia, cirrhosis and cancer of the liver, salvarsan intoxication with jaundice (3), malaria fever (2), gastro-colic fistula (52), alcoholism (53), scurvy (45), in poisoning with quinine, nicotine, carbon bisulphide, and in Oguthi's Disease. (3)

Idiopathic

Prehistoric man satisfied his hunger with natural foods largely in their fresh or unpreserved states. However, with the development of civilization, man has been obliged to change his living conditions and to eat food prepared to satisfy his tastes and conveniences rather than his body needs. This state of affairs has given rise to the so-called deficiency diseases. With these changes of living conditions, there have evolved methods of preserving, refining, and improving the tastes of foods, without due regard to their adequacy in the nutritional sense. (54)

The preparation of cereals, for instance, involves numerous processes, such as cleaning and bleaching. In the commercial manufacture of flour from cereal grains, the outer coating is often disposed of and the remaining part of the kernel milled for flour. This remaining part is then bleached to remove all color and as much of the natural oil as possible. The resultant product is then clean, white, and quite sterile. It tastes good, chews easily, and is almost free of the vital food elements, known as fat soluble vitamins. (54)

Diet is the factor of prime importance in the etiology of idiopathic night blindness. If there is insufficient utilization by whatever cause, over such a period of time as to deplete the body stores of vitamin A, then the disease becomes manifest. (54)

According to Blegvad this may be brought about as follows:

"I Reduced doses of vitamin A.

(a) food poor in vitamin A

(b) deficient absorption of vitamin A

II Increased consumption of vitamin A

(a) rapid growth

(b) severe disease" (55)

To truly appreciate the clinical manifestations of vitamin A deficiency, we shall consider briefly the physiology of the retina, as concerns us, and the history and physiology of vitamin A.

Adams describes the duplicity theory of vision, "The eye has two distinct mechanisms for sight. Photopic vision occurs only with light of moderate or high intensity and is essentially a function of the cones. Vision in faint illumination (scotopic vision) is mostly peripheral and primarily a function of the rods. If a spectrum of low intensity is viewed with the dark adapted eye, it appears as a gray band differing in brightness in different parts. In other words, with dim vision, objects are only seen as different intensities of gray. Rod function or scotopic vision depends upon the metabolism of the phototropic substance known as visual purple of the retinal rod cells..... As visual purple is formed from vitamin A, it follows that scotopic vision is intimately associated with the available supply of this vitamin."

(56)

There are clinical symptoms to be found in night blind persons that lend support to the duplicity theory of vision. Aykroyd states

that he has had numerous night blind patients remark that they are able to see a little of what is directly ahead of them by looking down at their feet. Thus, in essential nyctalopia in which the light threshold for the whole retina is raised, the periphery containing the rods and visual purple, retains its relative greater sensibility. (10) It is estimated that the periphery of human retinae is sixty times as sensitive to light as the central parts. (35) Similarly, astronomers observed long ago that stars of small magnitude were seen better if viewed somewhat eccentrically. (51) Further evidence is found in the study of comparative anatomy. Birds and animals possessing rods only see best at night while those who possess only cones see best in daylight. (35)

We are also concerned with color vision as will be seen when we discuss symptoms. So a brief review of Young's color vision theory seems indicated. Edmund has given the fundamentals of this theory very aptly. "One imagines that the normal, has, as it were, three organs of vision, which for convenience sake, may be called red eye, green eye, and violet eye. Each of these eyes has the power of adopting itself and each of them has its threshold of visual sensation, the lowest of which is that of the violet eye."

"Thus if the illumination is changed our conception of color changes too. Experimentally, one finds that if the brightness is reduced, the conception of green changes first. Next one loses

power to distinguish red, whereas, violet, one sees almost in the same shade as long as the field is visible."

"It is natural before hand to suppose that night blindness is due to an affection of violet eye. As it is, this eye that functions at lower illumination. Let us try to imagine what will happen if the violet eye is put out of function."

- (1) "One would attain a high threshold for visual sensation and hence be night blind."
- (2) "One would not be able to perceive blue and violet shades."
- (3) "One would perceive white as a mixture of red and green, that is to say, yellow."
- (4) "By a reduction (in illumination) the yellow would approach the red, because the sensibility of the green eye begins to diminish perceptibly at a higher brightness than that of the red eye." (57)

Thus we have an explanation for the erythropsia (red vision) and xanthopsia (yellow vision) sometimes found in night blind persons.

Edmunds reported a case of night blindness in 1927 who suffered yellow vision in good daylight, and red vision at dusk. (57)

Henderson in 1922 has reported the only case that I find of night blindness in a one eyed person. Night blindness was common during the war in those who had lost one eye in action. Examination of the good eye was negative and these individuals were perfectly fit to carry out their day duties. He thus felt that perhaps

they were malingering. However, Henderson was finally forced to join the one eyed ranks when he developed a carbuncle on the supra orbital margin. After having it excised one evening, he was unable to find his way to his quarters. But by lifting up the bandage and looking with both eyes, his night blindness disappeared. He explains this as being due to the loss of stereoscopic vision. He further reiterates that in the absence of artificial illumination, there is complete loss of stereoscopic vision, producing a perfectly flat monochromatic picture, in which one is unable to distinguish any object because of the absence of relief. (49)

History of Vitamin A.

Vitamin A, though not yet isolated in pure form and entirely unknown until the last few decades, has attracted the attention of clinicians by way of its deficiencies since the earliest times. (20)

The term "vitamin" was introduced in 1912 by Funk. He was severely criticized by some of his contemporaries for his choice of the word. He was working with vitamin B and his analysis showed it to contain nitrogen. This, he felt, was an "amine" and, being essential to life he named it "Vitamin." It was shown later that his crystalline substance was the active principle contaminated by other substances. (58)

As stated before the first description of xerosis conjunctiva was given by Bitot in 1863. (20) The first complete description of keratomalacia was given by da Gama Labo in 1864 (59) and Von Graefe in 1866. (60)

In 1912 Hopkins was the first to experimentally prove the presence of a "growth substance". He found that rats fed on purified material and no milk failed to grow, while the addition of only 4% milk to the diet induced normal growth. (61) Osborne and Mendel in 1913 demonstrated by feeding experiments that the growth substance of milk was found in the butter fat fraction. They also were the first to experimentally produce xerophthalmia in rats. (62) In the same year McCollum and Davis showed that ether extracts of butter fat and eggs also contained the growth promoting substances. (63) In 1914 Osborne and Mendel demonstrated the growth substance in cod liver oil. (64)

Block in 1921 was the first to apply the experimental knowledge directly to man. Thus he treated xerophthalmia cases that he had with a diet rich in butter fat and cod liver oil. (28)

McCollum and his associates in 1922, oxidized the vitamin A fraction of cod liver oil, as Hopkins said was possible, by passing air through it for a period of twelve to twenty hours. Cod liver oil treated as such failed to cure the xerophthalmia in rats, but was effective in curing rickets. Previous to this experiment some critics felt that the vitamin A fraction of cod liver oil was responsible for promoting the cure of rickets, but now vitamin A and vitamin D were separated. (65)

Our next important milestone is by Halm in 1925, when he showed that night blindness was an early symptom of avitaminosis A. This he demonstrated by a series of jumping experiments with

rats in diminished illumination. He also demonstrated that vitamin A deficiency alone was not the causative factor for night blindness, but it was necessary that the animals be first exposed to light. He thus discovered that the condition was one of delayed adaptation, not a lack of adaptation. (66)

This observation of exposure to light as an etiological factor was borne out clinically, also. Aykroyd made some interesting observations in Newfoundland and Laborador in the summer of 1929. Here he found several cases of night blindness among the numerous fishermen. Their diets consisted mainly of white bread, molasses, fresh cod muscle, salted meats, beans, peas, and potatoes. Their diet contained no milk, butter, eggs or green vegetables. Cod liver oil, being an export product, was not a part of the dietary. Some of the patients with night blindness had learned that if they protected their eyes from the glare of the sun by wearing dark colored glasses, their night blindness was somewhat improved. Others had discovered that if they kept one eye bandaged during the day, that that eye was then useful for night vision. Strong sunlight is thus an etiological factor. Men who are exposed for long periods of time in open boats were the chief sufferers. Women and children were very seldomly attacked. It was also observed that night blindness did not occur in well fed individuals no matter how long the exposure to bright sunlight. (10)

H. de Govuea made a similar observation on the poorly nourished

slaves of Brazil. He relates how they were unable to see when returning from work after sunset. Still they experienced no deficiency in seeing in the morning before sunrise, even though it was darker in the morning than in the evening. (67)

Yudkin and associates in 1931 prepared extracts from the retinae of hog's eyes and fed this extract to the vitamin A starved rats. Fifty mgm. of this extract daily cured the xerophthalmia in three to seven days. They state that none of the abnormalities usually attributed to vitamin A deficiency were detected at autopsy. They further state that the retina is a decidedly richer source of vitamin A than ordinary butter fat. However, the choroidal tissue is either entirely devoid of vitamin A or extremely poor in this factor. (68) (69)

Physiology of vitamin A.

The vitamin A of our diet is derived from two sources; namely, alpha, beta, and gamma carotene, crytoxanthin from the plant kingdom, and pure vitamin A from animal tissues. The plant kingdom variety is usually referred to as carotene or caratenoid substances. (35)

Man and animals are not capable of synthesizing either carotene or vitamin A in their bodies; thus, they are forced to depend upon exogenous sources. Carotene is synthesized by the plants, and from them both land and water animals get their supply directly or indirectly by preying on other animals. (35)

Vitamin A can readily be destroyed by oxidizing agents especially at high temperatures. However, it seems the form in which it is found in the natural sources is somewhat more resistant to destruction. In the most common foods in which it is found, it is sufficiently stable that it will not be destroyed by the modern processes of preservation, such as commercial canning operations. (70)

Vitamin A is found in yellow foods: carrots, cream, butter, and yellow corn (not white corn). This relationship to yellow substances is not absolute, as cod liver oil is not yellow in color, but is a rich source of vitamin A. (70) Carrots are considered as a very potent source of vitamin A. Moore found that 100 mgm of fresh carrot root, representing 10 mgm dry matter, were effective in curing xerophthalmia and restoring growth in vitamin A starved rats. (71)

Carotene and vitamin A, of course, are not identical substances. Carotene is yellow while vitamin A is practically colorless. Vitamin A exhibits an absorption band of 328 milli microns while carotene does not. Both substances, however, give a blue color with antimony trichloride. Carotene is a crystallizable hydrocarbon with a cyclic structure, related to the terpens. Vitamin A is probably a primary alcohol derivative of one half the carotene molecule. (72)

Both carotene and vitamin A, being fat soluble substances, are absorbed by the lacteals of the intestine, become mixed with

the chyle, and, via the thoracic duct enters the general circulation.

(73) Carotene is converted to vitamin A in the liver by the enzyme carotenase, one molecule of carotene giving rise to two molecules of vitamin A. Vitamin A is stored in the liver (74), and the body fats of some animals (75), and then used by the body as needed. Moore demonstrated rather conclusively that vitamin A is stored in the liver. The antimony trichloride test was negative when applied to the livers of vitamin A starved rats and was found positive after giving carotene. (76)

A study has been made of the absorption of carotene and vitamin A, in a patient suffering from a condition in which part of the contents of the thoracic duct was diverted into the pleural cavities. Analysis of the fluid removed at intervals from the chest cavities enabled an approximate estimate to be made of the amounts of vitamin A and carotene absorbed by way of the chyle. It was found that a relatively small portion of the carotene administered orally could be accounted for in the chylous fluid, but in the case of vitamin A, the amount recovered was such as would indicate almost complete absorption. The product administered to the patient contained the vitamin as a free alcohol, but judging from the properties of the material isolated from the chylous fluid, esterification had taken place during the process of absorption. These workers felt that the esterification of the vitamin, explained the fact that the vitamin was absorbed in a much larger proportion than was the carotene after oral adminis-

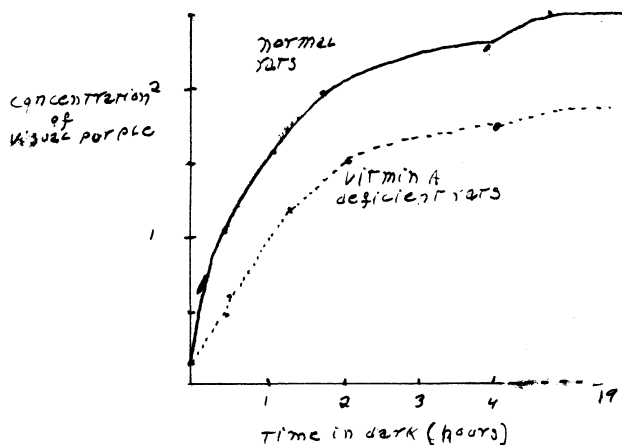
tration. They further state that there is evidence to show that carotene is more satisfactorily absorbed when given in natural foods or in oil solution, than when administered in highly concentrated form. (73)

Rountree has attacked this problem in a slightly different manner. His study involved the removal, by fat solvents, of the vitamin A from the urine and feces of children that were receiving a high vitamin A intake, and then feeding these extracts to vitamin A starved rats. All the avitaminotic rats fed on urinary extracts failed to show even the slightest improvement. So he concluded that it is certain that no vitamin A is lost in the urine. However, when the depleted rats were placed on a diet containing 6% fecal extract, they responded with a normal gain in weight. By determining the vitamin A content of the food ingested by the children, calculations showed that the children were losing 2% to 12% of the vitamins via the feces. The largest loss occurred with the largest intake. Since fecal fat is normally within this range, it seems that the loss of vitamins parallels the loss of fat. (77)

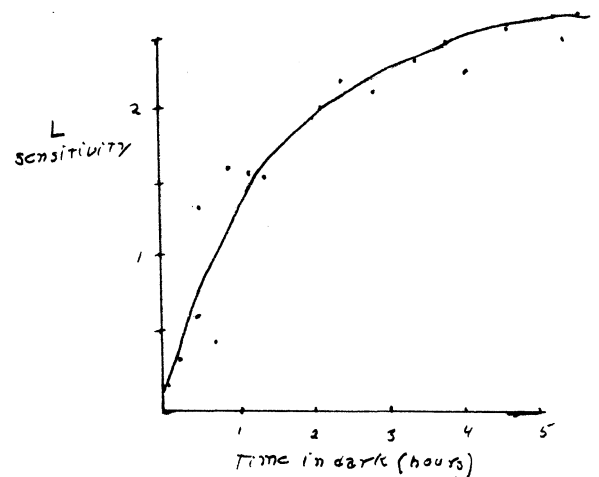
Sandler found that the placenta, colostrum, and milk of the human female contain carotene in important amounts (78) Wolff found the vitamin A content of the livers of infants to be less than that of adults. (79) Dann working on the transmission of vitamin A from parents to young has disclosed some interesting facts. Dann found vitamin A to be present in small amounts in

small amounts in the livers of rats and rabbits at birth and that it cannot be increased by feeding the mother a diet rich in vitamin A during gestation. He also found the vitamin A content of the liver to increase rapidly during suckling, and this may be made even greater when the lactating parent receives a diet rich in carotene. He feels this is applicable to man, because man and rats have a placenta of the hemochorial type. In those species of animals having the more highly developed placentas, the colostrum is less important and resembles more the later milk. He thus feels that the colostrum of humans is of no special significance as a source of vitamin A. (80) (81)

Tansley, employing digitonin, extracted the visual purple from the eyes of rats, the operations being carried out in a dark room with a red light to prevent the bleaching of the visual purple by white light. He found the sensitivity of the eye to light to be proportional to the amount of visual purple present. A curve showing the change in sensitivity of the retina during a period in the dark is comparable to a curve showing the changes in the amount of visual purple present under the same conditions. (82)



REGENERATION OF VISUAL PURPLE (RATS)



L = Least illumination visible at different times after going into dark
 DARK ADAPTATION HUMAN EYE.
 [ACHMATOV A.S.]

Light bleaches visual purple, splitting off carotene in the process; and visual purple is constantly being regenerated when the eye is at rest in the dark. It is stored in the posterior portion of the cells of the pigment epithelium and, after light exposure, the pigment granules push their way inward into the processes that extend between the rods and cones, and the latter contract and shorten. These terminal organs of the optic nerve receive the waves of light falling upon the retina converting these vibrations into impulses which are carried by the optic nerves and tracts to the brain where they produce the sensation of light. (48)

Exposure to light causes a disturbance in the metabolism of the visual purple. The more prolonged the exposure to bright light, the more rapid the depletion of this pigment. In some manner not yet clearly understood the retinal rods synthesize, utilize, or absorb vitamin A. It is the important factor in the regeneration of this visual purple. (48) Wold attempts an explanation of this process. He found that the light adapted retinae contained more vitamin A than dark adapted retinae. Light liberates from the retinal visual purple, a carotenoid, retinene (visual yellow), which is converted by a thermal reaction to vitamin A. Vitamin A and retinene are thus the precursors of visual purple which they form by combining with a colloidal component, probably protein. The visual process is thus a cycle. (83)

Deficient absorption of vitamin A was illustrated by Blegvod. In 1924 he reported a case of carcinoma of the liver associated with jaundice who had severe night blindness. He felt that due to the lack of bile in the gastro-intestinal tract the fat metabolism was so altered that fat soluble vitamins could not be absorbed.

(84) However, Parsons reminds us that bile salts are solvents for visual purple. Thus, he explains night blindness that is associated with jaundice. (86)

Vitamin A is normally stored in the liver. Green finds that the vitamin A content of the liver to be very low in cases of degenerative conditions of the organ in spite of the intensive vitamin A therapy. A similar condition is found in the presence of cortical necrosis of the kidney. (87)

Riddell reports a case of Coeliac Disease, the only one found in the literature, associated with nyctalopia. Due to the fact that fatty foods disagreed with the patient, they had been entirely eliminated from his diet. This patient was not able to take cod liver oil, but he responded to the vegetable forms of vitamin A. (88)

Inability to absorb vitamin A, also explains the night blindness found in the cases of gastro intestinal disturbances as reported by Wilbur and Eusterman (52), Park (33), and Blackfan and Wollack. (89)

Rapid growth is an etiological factor in the production of night blindness. This is shown by the fact that when young rats

became depleted of vitamin A they cease to grow. Furthermore it is much easier to deplete a young rat than it is an adult rat. Keratomalacia was found by Blegvod to have its highest incidence in children just when the most rapid growth takes place. This author reported 434 cases in a period of eleven years, most, of which, were under one year of age. In adults he had only 19 cases over the same period of time. Thus it may be concluded that more vitamin A is needed to prevent keratomalacia during the growing period than in adulthood. (55)

Blegvod is of the opinion that during times of sickness there is an increased demand for vitamin A; illness may thus serve as a precipitating factor. He states that keratomalacia has been observed with measles, scarletina, typhus, dysentery, pulmonary tuberculosis, and meningitis due to the tubercle bacillus. (55)

Barondes has described five cases of night blindness that were due to arteriolar spasm of retinal arteries. Ophthalmoscopic examination revealed a constricted blanched appearance of the peripheral arteries with more or less venous hyperemia and congestion. The diagnosis was further confirmed by the administration of nitroglycerine which relieved the condition. There was an increase in the sensitivity to faint illumination in 5-10 minutes. (48)

Night blindness during our last great war has been described by several authors. Some of these cases were described as associated with keratitis and conjunctivitis. Thus, they were probably on a nutritional basis. (51)(90) Davis, however, explains that due to the

moral and physical strain of war, there is a disturbance of choriocapillaries, resulting in a defect in the mechanism of retinal adaptation. (91)

Pathology:

The pathological picture varies with the degree of vitamin A deficiency. In the so-called idiopathic type of night blindness there are no changes that can be demonstrated with the ophthalmoscope. (27) As the degree of deficiency increases there are certain pathological phenomena that develop. These lesions are not limited to the eye, but are to be found in the various parts of the body.

Most of the pathological studies that have been made are on experimental animals. The first of these studies was made by Goldschmidt in 1915. He found keratinization of the outer layer of the conjunctival epithelium and the infiltration of the cornea with many leucocytes and bacteria. (92) Similar studies were done by Stephenson and Clark in 1920. However, they failed to find any definite changes that they felt were due to the deficiency. They thought the breakdown of the cornea was due to infection. (93)

The first thorough pathological study on rats was made by Mori in 1922. He found cornification of the outer cells of the bulbar conjunctiva. He also found changes in the lacrimal glands and felt that the xerotic changes were the result of dryness of the tissue, because of the small amount of secretion produced by lacrimal gland. The ulceration and perforation of the cornea were due to secondary bacterial infection (94)

Wolback and Howe in 1928 demonstrated that vitamin A deficiency affects primarily epithelial tissues. They found a substitution of

keratonized stratified epithelium in various parts of the respiratory, digestive and genitourinary systems. Masses of keratinized epithelium were found at autopsy in the bladder and, in some instances, in ducts of the salivary glands. They did their work on guinea pigs, and it seems that eye symptoms are less pronounced in these animals than in rats. (95)

Very few pathological studies of avitaminosis A in humans have been reported. According to Sweet and K'ang the first report of this nature is by Leder in 1883. He found a flattening of the superficial conjunctival epithelium, and described it as having a hard pearly appearance. (96)

Collins relates that Colonel Herbert (97) was the first to describe pigmentation of the conjunctiva as a prominent symptom of xerosis in humans. (98) The reference to Herbert's work is in 1987. However, I find that Kollock described the condition ten years previously. (99) This increase in pigmentation of bulbar conjunctiva was also noted by Wright, who felt it was an early premonitory sign of keratomalacia. (100)

In 1922 Yutkin explained that the pathological changes in the rats fed a vitamin A deficient diet, are like the conditions known as xerosis conjunctiva in man. (101)

Then in 1923 we have the second report of a pathological study of an infant by Wilson and Du Bois. They described a keritinization of the epithelium of some of the visceral organs as the lungs and uterus. (102) Blackfan and Wollock have described

autopsy findings in eleven cases of vitamin A deficiency in infants. They concluded that the most common and earliest appearance of keratinizing metaplasia in infants is in the trachea and bronchi and next the pelvis of the kidney. They state that the loss of ciliary motion and diminished mucous secretion is one basis for the belief that this deficiency predisposes to infection. (89) Tilderquist finds that first there is a disappearance of the goblet cells in the conjunctiva and this is followed by a metaplasia of the epithelium, resulting in a structure similar to the epidermis. (103)

Pillot in 1933 published a very detailed report on the pigmentary changes found in vitamin A deficiency among the Chinese. He finds that the pigmentation is not often visible macroscopically. It is most marked in the lower fornix and on the inner canthus; from here it extends to the lower lid and bulbar conjunctiva. The conjunctiva of upper fornix and lid may show no pigmentation, and if it does it is always less pronounced than that of the corresponding parts of the lower conjunctival sac. The intensity of this pigmentation depends upon the duration of the deficiency, not the severity. Thus, acute deficiencies, showing keratomalacia, may fail to show any increase in pigmentation. (104)

There are two types of pigment producing cells: One, the melanoblast, being found chiefly in the basal cell layers; and

second, the ordinary epithelial cells, especially those of the middle layers. The latter produce "pigment caps" at the distal pole of the nucleus. The melanoblasts appear first in this deficiency. He asserts that the function of this pigment is one protection against light, the process being analogous to the sun tan obtained by exposing the skin to the action of the sun's rays. Ordinary light in usual doses has no adverse effect upon normal epithelial cells. But in patients suffering from vitamin A deficiency, the metabolism of these cells seems impaired, or at least endangered, by the lack of this important constituent, vitamin A. The basal cells are the most important cells of any epithelium, because by their reproduction the constantly denuded surface cells are replaced; and in order to maintain this reproductive function, in the face of vitamin A deficiency, these cells need protection from the sunlight. He observed that this pigmentation was the last to leave in response to treatment, as the cells of the conjunctiva are exfoliated slowly. Due to the long duration of this pigmentation, after the acute condition has subsided, it is possible at times to determine the etiology of adherent leucoma, or a staphyloma cornea. (104)

Having thus made this study, the question arose as to what was the normal amount of pigmentation present in the conjunctiva. Therefore, somewhat later in 1933, Pillot studied the conjunctiva of seven persons having no ocular disease or vitamin deficiency. His subjects ranged from 14 to 43 years of age. In this study he

found that the normal range of pigmentation was wide, and no definite line could be drawn between the pathological and physiological. There was a normal increase seen in the older patients, in those exposed to much sunshine, or in those having slight conjunctival irritation. (105)

The skin manifestations associated with vitamin A deficiency were first described by Frazier and Hu in 1931. They describe the pathological picture as "essentially one of hyperplasia and hyperkeratinization of the epithelium of the epidermis and hair follicles, and metaplasia of the sweat ducts tending toward the keratinizing type, degeneration of the glandular structures of the skin, and infection." (106) Loewenthal describes the coruim as showing evidence of irritation. There is some congestion, edema and cellular infiltration limited to the region of the follicles. The cellular elements are chiefly lymphocytic and fibrotic. (107) Youman relates that "the ducts of the skin are distended and plugged with masses of cornified epithelium." There is atrophy of the glands and hyperplasia of the epithelium. (108)

Symptoms

The symptomatology, like the pathology, is dependent upon the degree or severity of the deficiency of this particular vitamin.

Inability to see in diminished illumination is the earliest symptom and it may be present for many months without the appearance of any other symptoms. (54) This night blindness may be present in such a mild form that the patient may be unaware of its existence; and, vision in good illumination, such as day light, may be perfectly normal. (35) Thus far we have merely a functional disturbance, but as the deficiency becomes more severe, the evidence soon becomes gross. There may be pain, lacrimation, redness, and photophobia (54) Subsequent to the transformation of the epithelial structure of the conjunctiva, there is some conjunctival discharge and the lids may be glued fast in the mornings. The conjunctiva becomes dry and white and exhibits glistening spots, often covered with a whitish foam. This represents the xerotic stage. (103) (108) Then rather suddenly the vision may fail, usually being associated with a spreading white spot on the cornea. This lesion may progress slowly or extend to complete blindness in only a few days. (54)

Red vision is described by some authors (53) (57) and yellow vision is described by one (57). I have been unable to find any explanation for the infrequency of this disturbance in color vision.

Hoarseness, fever, and a nonproductive cough are seen in about 25% of the cases. The hoarseness and cough are the result of dryness and irritation in the trachea and larynx due to the diminished mucous secretion. The fever is thought to be due to a collapse of the heat regulating mechanism, especially by the diminished perspiration. However, there is some disagreement on this point, as the fever disappears in a few days following vitamin A therapy. It may be due to the absorption of toxic products through the altered epithelium (54). Headache, vomiting, weakness, and diarrhea have also been observed. (54) The diarrhea is thus far unexplained. However, Pillot, in studying the gastric acidity in 25 vitamin A deficient patients, has found 56% of them to have either anacidity or low acidity. (109) Scanty and dry hair, transverse furrowing of the nails has also been described. (100) (54). Anorexia and loss of weight has been found associated with this deficiency while Mori maintains that loss of weight and diarrhea may be associated with excessive appetites. (110)

There is a dryness of the skin, affecting all parts of the body except the face and scalp. Both sebaceous and sweat secretions seem deficient except on the facial region where it may be abundant. Itching of the skin is a prominent feature. (107)

Diagnosis

It is well known that vitamin A deficiency may manifest itself by pathological lesions known as xerosis or xerophthalmia, especially in children. Xerophthalmia is usually considered the classical manifestation of this deficiency. The latent forms of vitamin A deficiency are much more important in the practice of medicine than the fully developed cases. The latter are uncommon in America and easily recognized, but the mild forms are much more frequent and often escape recognition. (108)

As Jeghers points out practically all eye tests are performed in good illumination, and thus depend upon cone function. Since cone function is not dependent upon the supply of vitamin A or visual purple, one can understand why a patient's performance in an eye test may be satisfactory and still he may be night blind. Thus the condition of night blindness has readily been overlooked in the past. (35)

It is now possible to recognize a deficiency of this vitamin by a disturbance which is functional rather than organic. Thus night blindness is the most delicate of all indicators of vitamin A deficiency. (31)

As I shall attempt to show, there are numerous methods by which a diagnosis of vitamin A deficiency may be made, and probably no one method will suffice in all cases.

The following methods are outlined by Frandsen.

I Minimum light visible determination (photometer)

II Visual field examination in reduced illumination.

III Visual acuity determination in reduced illumination.

IV Examination of the power of distinction" (3)

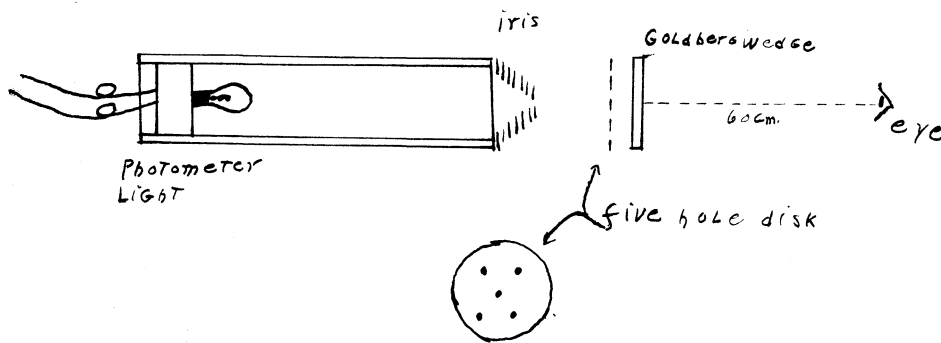
This latter method is the one employed by Frandsen, who used a set of eight Tscherning photometric glasses combined with Edmunds test charts. (3)

The Birsch Hirschfeld photometer consists essentially of a metal tube with an electric light bulb at one end. At the opposite end are an iris diaphragm, a five point disk, and a Goldberg wedge. The intensity of the illumination may be controlled by a rheostat. The iris diaphragm is opened and closed by a lever which swings along a scale marked with the diameter of the opening in millimeters. The disk is made of black metal and has punched out of it a five point quincunx. The Goldberg wedge is a glass slide treated photo-chemically so that a uniform decrease in light transmission is obtained from one end to the other. With this arrangement there is practically a complete transmission at one end and a zero transmission at the other. (75)

The subject peering through the photometer observes its light as regulated by the wedge, the iris diaphragm, and the transmission through the disk. Because of the gradations in light transmissions produced by the wedge, the light spots are unequally visible. The number of spots visible depend upon the intensity of illumination, which in turn depends upon the size of the opening in the diaphragm and the position of the wedge. (75)

In performing the test, the subject is seated in a chair

and the room is then lighted brightly by a 150 watt lamp. The bright light is then turned off and the room made completely dark. Then the first reading is made as soon as the subject can determine the end point distinctly. The end point is that point at which three constant spots of light are distinctly visible. The Goldberg wedge is usually set at a definite point and the amount of light controlled by iris diaphragm. (75)



Scheme of Birsch Hirschfeld Photometer

There is a new American made photometer now available. It is similar in principal to the Birsch Hirschfeld, except that the intensity of illumination is controlled by a rheostat and the amount of light is measured directly in milli foot candles. This

photometer reveals a higher proportion of moderately subnormal subjects than does the Birsch Hirschfeld. It also requires less manipulation and time. Workers who have used and compared the two conclude that the readings of both agree within the range of experimental error. (38)

This photometer method is only applicable to adults, but Fridericksen and Edmund have devised a reflex method that they have used on infants. They determine the "minimum reflexible" which they feel is closely akin to the minimum visible. The test consists in determining the faintest light irritant that will illicit certain reflex movements via the child's eye. The infant is dark adapted for one half hour before the test. This method, they relate, obtains information regarding the power of adaptation, and thus his vitamin A balance. A small electric lamp is the source of illumination. It is fastened to a rod, of the shape used in Simons ophthalmoscope. The lighted end is fitted with a light proof cap, into which are inserted light absorbing glasses. They absorb light in a logarithmic scale. By flashing this light off and on in various positions they are able to illicit mimic reflexes such as squeezing the eyelids together; oculomotor reflexes,--eyes turning toward the source of light, and other motor reflexes,--as child trying to catch light or turning the head toward the light. (11)

Examinations of the visual fields at lowered illumination reveals the fields of vision to be contracted for white as well as

for colors. This method gives reliable results, but, according to Frandsen, neither visual field nor visual acuity determinations are suitable for demonstration of nyctalopia in general practice.(3)

Jeghers mentions a very simple procedure which may be used to detect retarded dark adaptation. The test is performed in a dark room. Following the exposure of the eyes to bright light, one can normally read the luminous dial of a watch in three minutes.(50)

Carr and Price in 1926 discovered the antimony trichlorate test for vitamin A. (112) and Blackfan states that it is one of the best suited tests for clinical purposes of diagnosis. The average value on an average diet is "40 blue units" per 100 cc of serum, about .05 mgm/% of vitamin A. (112)

Another diagnostic method consists in making light scrapings of the bulbar conjunctiva. When properly stained this reveals cornified epithelial cells with the absence of nuclei. Sweet and K'ang believe this to be one of the best diagnostic procedures for early vitamin A deficiency. (54) Nasal scraping will show a similar change. (108)

Exposure of the cornea and conjunctiva for 3-5 minutes by retracting the lids is still another method that may lend some information. In the early cases there will be a slight haziness or loss of luster of the conjunctiva. (54)

Conjunctival pigmentation is considered of value in diagnosis, especially in oriental races. It may be detected by employing the use of a good loup. (104)

Now let us turn to the usual laboratory procedures and see if any information can be had there.

In the uncomplicated cases there is no secondary anemia and the leucocytes show no response. Urine analysis are not constant. Of 203 cases examined the urine analyses were completely negative in 125. Large numbers of epithelial cells are rare. The albumen of the blood varied from 1.07 to 3.76 mgm%, averaging 2.41 mgm%. The globulin ranged from 1.6 to 4.74 mgm%, averaging 2.65 mgm%. Calcium and phosphorus determinations on 31 cases showed the calcium to be below 9 mgm% in 8 cases; the phosphorus was below 3.5 mgm% in 7 cases. (54) Frandsen on 12 determinations found low values for both calcium and phosphorus in all cases. (3)

The cutaneous eruptions may be of aid in the diagnosis. It consists of round or polygonal, smooth topped, shiny papules about .6 cm in diameter, the edges being rather sharply demarked. Some cases also show folliculitis without pus. These papules have a characteristic distribution over the extensor surfaces of the arms and hands, the front of the legs and thighs, and across the buttocks. (107) Frazier and Hu add to this description somewhat. "In the apex of each papule is a keratotic plug projecting above the surface as a spiny process. When these plugs are expressed it leaves a gaping central crater." (106)

Treatment

There is yet much to be learned concerning the limits within which the body can adjust itself to variations in vitamin intake. Blackfan states, "It is only when the limits of safety are grossly, overstepped that the effects become detectable clinically." (112)

Therapeutic efforts, of course, are directed to the dietary. Milk, butter, eggs, green vegetables, and animal fats, except pork, should all be in the diet. This may be supplemented by 15 cc of cod liver oil or 30 drops of habit liver oil daily. (54)

Infection in the eyes may require a combination of local antiseptics and hot compresses. In other words treatment is made suitable to the needs of the complications, whatever they may be. (54)

Xerosis and night blindness may be cured without the administration of vitamin A concentrates. Riddell reported a case of coeliacs disease; this patient was unable to take cod liver oil. However, his manifestations of vitamin A deficiency disappeared in 10 days, when fresh vegetables, butter, eggs, and fish were added to his diet.

Paraenteral administration of vitamin A has been shown to be efficacious. (84) (35) This method is very valuable in some patients having gastro intestinal disturbances or diseases of the liver.(84)

Jegher (35), Sandler (78), and Park (33) report very favorable results from the administration of carotene. Park has proved definitely that it is non toxic and 11 of 12 patients showed

44

improvement in the photometer reading following carotene therapy. Carotene gave marked relief in some cases of spastic colitis and diarrhea of diabetics. Some of these cases had used other forms of vitamin A products without relief. Thus Park feels that Carotene has some additional function, either per se, or through the synthesis necessary to change carotene to vitamin A. (33). Jeghers warns that if carotene is given faster than the liver can convert it into vitamin A, the carotene is then stored in the tissues and produces a yellow color resembling jaundice. However, this carotenemia is not dangerous and promptly disappears when the dosage is curtailed. He found a dosage of 10,000 units orally daily for six weeks did not produce a carotenemia. 5,000 to 10,000 units of vitamin A in the form of cod liver oil or carotene seem about equally effective. (35) Jean and Zentmire similarly, detected no difference between cod liver oil or carotene in improving the photometer reading in deficient children. (34)

The question arises: how soon is this form of therapy effective, Edmund and Clemmesen demonstrated that one single subcutaneous injection of vitamin A (40,000 units per cc) resulted in the disappearance of the night blindness and improvement in the photometer reading in 7-10 minutes. (113). Aykroyd found that night blindness is cured by one or two injections of cod liver oil in 12-36 hours. (10)

Fridericksen and Edmund in 1937 found the "minimum reflexible" was restored to normal in infants in $\frac{1}{2}$ hour by the use of cod

liver oil, halibut liver oil, or vegetable vitamin A in the form of spinach. (111)

Jeghers in 1937 was able to produce a normal photometer reading in 2-3 weeks by the use of carotene in capsules--10,000 U. S. P. units daily. (35)

The skin lesions are much slower in clearing, requiring 4-10 weeks. (37) Loewenthal administered one ounce of cod liver oil daily and found 98% of the dermatoses cleared in 9 weeks. (107) Goodwin found the skin lesions of a ten year old child markedly improved in six weeks on cod liver oil therapy. (114)

What are the daily requirements of vitamin A for humans? There are many reasons why this question cannot be answered exactly. The vitamin A content of food varies with regard to season, storage, and dehydration. Similarly, individuals vary in regard to absorption, storage, and consumption of vitamin A. In spite of these variables a few estimates are available. Harris felt 1400 units daily to be adequate. (115) Cameron recommends 5000 units daily. (116) Jeghers found 4000 units sufficient to maintain a normal photometer reading and feels this is probably close to the minimal requirement, but suggests that a 50% increase may be optimal. (37) Jeans and associates were able to maintain a normal photometer reading for 3 months in two children eleven years of age with 3000 units daily. (38)

What is meant by the above mentioned "units" and what is the unit value of some of the staple foods that make up our general diet? The rat unit is defined as that amount of vitamin A needed to produce an increase in weight of 2-3 grams per week

for five weeks in rats that have ceased to grow after subsisting on a diet deficient in vitamin A. A quantitative estimation of the vitamin A content of a few of our common foods has been given by Coward and Morgan:

"Milk: 3 units/cc or 1700 units/pint

Jersey Milk: 5 units/cc or 2850 units/ pint

Butter: 60 units/ gm

Egg Yolk: 30 units/ gm

Carrots: 19 units/ gm

Cabbage: 9 units/ gm

Runner Beans: 6 units/ gm

Cod liver oil: 2000 units/ gm or 6400 units/teaspoon

Halibut liver oil: 160,000 units/ gm or 3200 units/drop
(20 mgm)" (117)

Jeghers reports an experiment in which he was the subject, that is both interesting and instructive. For three ^{months} prior to the experiment he ingested 10,000 units of carotene and 17,000 units of vitamin A daily. Thus he felt assured that his vitamin A stores were at a peak. He then placed himself on a diet deficient in vitamin A but adequate in every other respect. He calculated that his diet still gave him about 200 units daily. Readings on the biophometer were taken daily. On the sixth day

of the regime the first impairment of dark adaptation was seen. It progressed steadily until the thirtieth day. Definite subjective night blindness was noticed during the fourth week on entering theaters and observing fluoroscopic examinations. He also noticed some photophobia. Then at 12 o'clock on the 31st day he took 80,000 units of vitamin A orally and in 30 minutes partook of a normal meal. At 2 o'clock the photometer reading was found much improved. The reading returned to normal in three days by taking 100,000 units of vitamin A daily. (37)

Significance

A point of practical and economic importance arose while Jeghers was testing adults for vitamin A deficiency. Those patients showing a subnormal photometer reading were questioned in order to determine if their diminished dark adaptation handicapped them while driving their automobiles at night. Numerous patients then revealed that they did experience difficulty with night driving. Their difficulty was most noticeable when meeting an on-coming automobile, as the glare of the lights resulted in a temporary blindness. (50)

Night blindness is a unique experiment that will bring out nyctalopic manifestations if vitamin A deficiency exists. The light glare depletes the visual purple and, if the patients vitamin A stores are at low ebb, the regeneration is slower than normal. Thus, after meeting automobile lights repeatedly, one's visual acuity is so diminished, that the possibilities of having an accident are greatly increased. (50)

This night driving difficulty being purely subjective does not permit a comparison with a person having normal dark adaptation. Thus, many people accept this difficulty as the usual experience of all drivers. (50) Park (33), Tilderquist (103), and Wilber and Eusterman (52) have all reported cases having difficulty driving automobiles at night. Rollet (118) and Vignalous (119) of France have made similar reports.

Statistics show that automobile accidents and fatalities reach a peak at dusk and continue at a high level all during the night hours, even though there is considerably less traffic at night than in the daytime. (120)

Mason sent a questionnaire to the motor vehicle department of all states and had replies from forty-seven. He finds that only twenty states require a visual examination of the prospective licensee. Nine states require no license whatever to operate a motor vehicle. In many of the states having no visual requirements, the applicant need only state that he is free from physical defects, which would incapacitate him from driving safely. (121)

Berens and Smith in 1931 investigating the ocular standards for aeroplane pilots as set forth by the Aeronautics branch of the United States Department of Commerce finds that the "light sense" test is not employed on aviators in either the United States Army or Navy. The "light sense" test is enumerated as one of the requirements, but apparently is not considered important. (122)

If normal vision in diminished illumination is important to drivers of automobiles, it seems that it should be equally important, or more so, to those piloting aircraft. (50)

Besides automobiles and aircraft, normal dark adaptation is surely of significance in the railroad field. To this may be added: the medical profession, especially the roentgenologist. (50)

BIBLIOGRAPHY

1. Nyctalopia. The Am Encyclopedia of Opth. 11:8394-97
2. Bordley, J.: A Family of Hemeralopes. Bull. John Hopkins Hosp. 278-81, 1908
3. Frandsen, H.: Hemeralopia as an Early Criterion of A-avitaminosis. Copenhagen 1935
4. Greenhill, W. A.: In the Case of Nyctalopia and Hemeralopia. Opth. Hosp. Report 10; 283-92, 1880
5. Tweedy, H.: The Words Nyctalopia and Hemeralopia. Opth. Hosp. Report 10; 413-16, 1880
6. Pritchard, A.: Nyctalopia. Brit. Med. J. 447, 1859.
7. Tweedy, H.: Nyctalopia and Hemeralopia. Opth. Record, 5; 201-25, 1895.
8. Guthrie, L.: Hemeralopia or Nyctolopia. Brit. Med. J. 31: 198, 1915.
9. Dorland, The American Illustrated Medical Dictionary, Philad, Penn., W. B. Saunders and Co., 17th edition, 1935.
10. Aykroyd, W. R.: Food Deficiency Diseases. J. Hyg. 30: 379-85, 1930
11. Aykroyd, W. R.: Night Blindness due to Vitamin A deficiency. Tr. Opth. Soc. U. Kingdom; 50: 230-37, 1930
12. Fridericia, L. S., Holm, E. H.: Experimental Contribution to the Study of Relation Between Night Blindness and Malnutrition. Am. J. Physiol. 73: 63-78, 1925.
13. Junder, H.: On Night Blindness. Med. Times & Gaz; 2, 71, 1886.
14. Laycock, T.: Nyctalopia with Partial Deafness in five children of Same Family. Med. Time & Gaz. 1: 412, 1886.
15. Bampfield, R. W.: A Practical Essay on Hemeralopia and Nyctalopia. Med Chiv. Tr. London 5:32-66, 1814

16. Robinson, C. H.: Remarks on Night Blindness. Lancet, :683, 1868.
17. Centerwall, I. A.: A Case of Moonblindness. Boston Med. and Surg. J. 137:383, 1897
18. Zimmerman, C.: Review of the Theories of Hemeralopia. Arch. Ophth. 12: 190-200, 1883.
19. Fuchs, H. E.: Textbook of Ophthalmology, 6 ed, 586-88. Philad. and London, J. B. Lippincott and Co., 1919, Trans. by Duane, A., From 12th German ed.
20. Bitot: Gaz. Med., 1863, cited by Fredericia and Holm in 12.
21. Forbes, J.: Observations on Tropical Nyctalopia. Edinburgh Med. Surg. J. 28: 417-19, 1811
22. Carter, R. B.: Nyctalopia. Med. Times Gaz.: 509, 1866.
23. Genner, C. S.: Hemeralopia. New Orleans Med. Surg. J. 11: 200, 1854
24. Davenport, E. J.: Case of Nyctalopia-Idiopathic. Boston Med. Surg. J. 11: 31032, 1934-35.
25. Nicolls, G. A.: Scurvy and Hemeralopia. Med. Times Gaz. 2: 96, 1855
26. Walton, H.: A Lecture on Night Blindness. Med Times Gaz. 1: 169, 1866.
27. Featherstonhaugh, T.: Hemeralopia without Appriciable Lesion. Am. J. Ophth. 4: 241-44, 1887
28. Bloch, C. E.: Clinical investigation of xerophthalmia and Dystrophy in Infants and young Children. J. Hyg. 19: 28-31, 1921.
29. Smith, H. S.: Night Blindness and Malingering of Night Blindness. J.A.M.A. 77: 1001, Sept. 14, 1921.
30. Moore, T.: Vitamin A Reserves of the Human Liver in Health and Disease. Lancet 2: 669-74, 1932
31. Hess, A. F., Kirby, D. B.: The Incidence of Xerophthalmia and Night Blindness in the United States. Am. J. Pub. Health, 23: 935-38, Sept. 1933
32. Jeans, P. C.; Zentmire, Z: A clinical Method for determining Moderate Degrees of Vitamin A. Deficiency. J. A. M. A. 102: 892-95, Mar., 1934.
33. Park, I. O.: Preliminary Observations on Vitamin A Deficiency as Shown by Studies with a visualphotometer. J. Oklahoma Med. A. 28: 357-62, Oct., 1935

34. Jeans, P. C.; Zentmire, Z.: Prevalence of Vitamin A deficiency among Iowa Children, J.A.M.A. 106:996-7 March, 1936
35. Jeghers, H.: Degree and Prevalence of Vitamin A Deficiency. Ann. Int. Med. 10: 1304-34, March, 1937
36. Spence, J. C.: Clinical Study of Xerophthalmia and Night Blindness. Arch. Dis. Childhood, 6: 17-26, 1931.
37. Jeghers, H.: Vitamin A. Deficiency. J.A.M.A. 109: 965, 1937
38. Jeans, P. C.; Blanchard, E.; Zentmire, Z.: Dark adaptation and Vitamin A. J.A.M.A. 108: 451-58, 1937
39. Nettleship, E.: A Pedigree of Congenital Night Blindness with Myopia. Tr. Ophth. Soc. U. Kingdom, 32: 21-45, 1912.
40. Morton, A. S.: Two Cases of Hereditary Congenital Night Blindness without visible Fundus Changes. Tr. Ophth. Soc. U. Kingdom. 13: 147-50, 1893
41. Symonds, H.: Two Cases of Night Blindness, Brit. Med. J. 1: 212, 1898
42. Sinclair, W. W.: Hereditary Congenital Night Blindness without Visible Ophthalmoscopic changes. Ophth. Review, 24: 255-58, 1905
43. Nettleship, E.: A History of Congenital Stationary Night Blindness in Nine Consecutive Generations. Tr. Ophth. Soc. U. Kingdom, 27: 269-93, 1906
44. Tagari, R.; Kawakami, R.: Ueber Das Wesen der Oguchischen Krankheit, Klin Monatsbl Augeneheilk, 72, 349, 1924
46. Moller, H. U.: Dark Vision in Glaucoma. Acta. Ophth. 3: 170-82, 1926
47. Bedell, A. J.: Choroideremia. Arch. Ophth. 17: 444-67, 1937
48. Barondes, R. R.: Glycerol Tri-nitrate in the treatment of Hemeralopia. Brit. J. Ophth, 20: 528-31, 1936
49. Henderson, T.: Physiological Night Blindness of the One-eyed. Tr. Ophth. Soc. U. Kingdom, 42: 371-74, 1922
50. Jeghers, H.: Night Blindness Due to Vitamin A deficiency, and Importance of in Traffic Problems. New England J. Med. 216: 51-56, Jan 14, 1937

51. Bell, P. G. B.: Notes on Night Blindness at the Front.
Canada Med. A. J. 11: 325-27, 1921.
52. Wilbur, D; Eusterman, G. B.: Nutritional Night Blindness.
J.A.M.A. 102: 364-65, 1934
53. Lundsgaard, K.K.K.: Night Blindness and other Eye Complication
in Chronic Alcoholics. Acta. Opth. 2: 112-24, 1924.
54. Sweet, L.K.; K'ang, H.J.: Clinical and Anatomical Study of
Vitamin A. Defeiciency amon Chines. Am. J.
Dis. Childhood, 50: 699-734 1935
55. Blegvad, O.: Xerophthalmia. Am. J. Opth. 7: 89-117, 1924
56. Adams, D.: Dark Adaptation. Med. Research Council, London,
1929, Special report, series, 127: 1-138,
Quoted by Jeghers in 35.
57. Edmund, C.: Color Perception in Normal and Night Blind persons
at Various Illuminations. Tr.Opth. Soc. U.
Kingdom, 47:319-29, 1927
58. Funk, C.: The Vitamins. p.18, Baltimore, Williams and Wilkins
Co., 1922, Trans. by Dubin Harry.
59. da Gama Labo, M.: Brasclianische Ougenentziew durg. Monatile
f Augenh. 7:65, 1866, cited by Sweet & K'ang
in 70.
60. Von Graffe, A.: Hornhautver Schwanung bei Infantiler
Encephalitia. Arch. f Opth. 12: 250, 1866,
cited by Sweet and K'ang in 54.
61. Hopkins, F. G.: Factors in Diet. J. Physiol. 44: 425, 1912
62. Osborne. T. B.; Mendel, L.B.: Influence of Butter fat on
Growth. J. Bio. Chem. 16: 423, 1913
63. McCollum, E. V.; Davis, M.: Necessity of Certain Lipins in
the Diet During Growth. J. Bio. Chem. 15:167, 1913
64. Osborne, T. B; Mendel, L.B.: Influence of Cod Liver and Some
Other Fats on Growth. J. Bio. Chem. 17:401, 1914
65. McCollum E. V., Simmonds, N., Becker, J. E., Shipley, P. G.:
Studies on Experimental Rickets. Bull. John
Hopkins Hosp. 33:229, 1922
66. Holm, E. H.: Demonstration of Hemeralopia in Rats Nourished
on Foods Devoid of Fat Soluable Vitamin. Am.
J. Physiol. 73: 79-84, 1925

67. de Govnea, Grafe's Arch. F. Ophth. 1859,v,1,11 cited by Fridericia and Holm in 13.
68. Yudkin A.M.; Kriss, M.; Smith, A. H.: Vitamin A. Potency of of Retinal Tissue. Am. J. Physiol. 97:611-16, 1931
69. Yudkin, A. M.: The Presence of Vitamin A in Retanae. Arch Ophth. 6: 754, 1931.
70. Mendle, L.B: Vitamin A. J.A.M.A. 98: 1988-89, 1932
71. Moore, T.: Association of Vitamin A Activity with Carotene in the Carrot Root. Bio. Chem. J. 23: 803,11, 1929
72. Editorial: Conversion of Carotene ot Vitamin A, J. A. M. A. 100: 1038-39, 1933,
73. Drummond, J.C; Bell, M.E; Palmer, E.T: Absorption of Carotene and Vitamin A. Brit. Med. J. 1: 1208-10, 1935
74. Olcott, C. C.; McCann, D. C.: Transformation of Carotene to Vitamin A in Vitro. J. Bio. Chem. 94: 185-93, 1931
75. Moore, T: Distribution of Vitamin A and Carotene in the Body of Rat;Bio. Chem. J. 25: 275-86, 1931
76. Moore, T.: Conversion of Carotene to Vitamin A in Vivo. Bio. Chem. J. 24:692-702, 1930
77. Rowntree, J. I: Retention of Vitamina. J. Nutrition, 2:265-87, 1930
78. Sandler, A. S.: Carotene in Prophylactic Pediatrics. Arch. Ped. 52:391-406, 1935
79. Wolff. L. K.: On the Quantity of Vitamin A present in the Human Liver. Lancet, 2:617-20, 1932
80. Dann. W. J.: Transmission of Vitamin A from Parents to Young in Mammals. Bio. Chem. J. 26:1072-80, 1932
81. Dann, W. J.: The Vitamin and Carotenoid Content of Human Colostrum and Milk. Biochem. J. 30:1644-51, 1936
82. Tansley, K.: The Regeneration of Visual Purple: Its Relation to Dark Adaptation and Night Blindness. J. Physiol 71:442-58, 1931.
83. Wald, G.: Carotenoids in the Visual Cycle. J. Gen. Physiol. 19:351-71; 1935.
84. Blegvad, O.: Subcutaneous Injection of Vitamin A. Brit. Med. J. 1:122-23, 1934.

85. Altschule, M.D: Vitamin A Deficiency in Cases of Atresia of Bile Ducts. Arch. Path. 20:845-56, 1935
86. Parsons, J. H.; Night Blindness. Lancet, 1:555, 1908
87. Green, H. U.: Vitamin A Content of Liver in Puerperal Sepsis. Lancet, 2:723-26, 1932
88. Riddell, J.B: Coeliac Disease Associated with Night Blindness and Xerosis Conjunctiva. Tr. Ophth. Soc. U. Kingdom, 53:295-302, 1933.
89. Blackfan, K.D.; Wallock, S. B.: Vitamin A Deficiency in Infants. J. Ped. 3:679-706, 1933
90. Meyerhof, M.: Night Blindness as a War Disease. Am. J. Ophth. 33:139-43, 1916.
91. Davis. M.: War and Night Blindness. Am. J. Ophth. 1:465, 1918
92. Goldschmidt, M: Arch. f Ophth. 90:354, 1915, cited by Sweet And K'ang in 54
93. Stephenson, M.; Clark, A. B: Contributions of the Study Keratomalacia among Rats. Bio. Chem. J. 14:502,1920
94. Mori, S.:The Changes in the Para-ocular Glands which Followed Administration of Diets Low in Fat Soluable A. Bull. John Hopkins Hosp. 33:352-59, 1922
95. Wolback, S. B.; Howe. R. R.; Vitamin A Deficiency in Guinea Pigs. Arch. Path. 5:239-53, 1928
96. Leder, T.: Arch. f Ophth. 29:225, 1883, cited by Sweet & K'ang in 54.
97. Herbert, Colonel: Indian Med. Gaz. April, 1897, cited by Collins in 98.
98. Collins, E.: The Harderian Gland. Tr. Ophth. Soc. U. Kingdom, 50:223, 1930
99. Kollock C.W.: "Epidemic Hemeralopia as Seen on the Coast Country of South Carolin. Ophth. Record, 6:68-70, 1897
100. Wright, R. E.: Keratomalacia in Southern India. Brit. J. Ophth. 6:164-75, 1922

101. Yudkin, A. M.: Ocular Manifestations of the Rat, the Result from Deficiency of Vitamin in the Diet. J.A.M.A. 79:2206, 1922.
102. Wilson, J. R.; Du Bois, R.O.: Report of a Fatal Case of Keratomalacia in an Infant, with Postmortem Examination. Am. J. Dis. Childhood, 26:431-46, 1933
103. Tilderquist, D.L.: Eye Manifestations in Avitaminosis. Minnesota Med. 16:675-78, Nov, 1933
104. Pillot, A.: Production of Pigment in the Conjunctiva. Arch. Ophth. 9:25-47, 1933.
105. Pillot, A.: Physiologic Content of Pigment in the Conjunctiva of Chinese. Arch. Ophth. 9:411-45, 1933
106. Frazier, C. N.; Hu, C.K.: Cutaneous Lesions Associated with Deficiency of Vitamin A in Man. Arch. Int. Med. 48:507-514, 1931
107. Loewenthal, L.J.A.: New Cutaneous Skin Manifestations in Syndrome of Vitamin A Deficiency. Arch. Dermat. Syph. 28:700-708, 1933
108. Youman, J. B.: The Present Status of Vitamin A Deficiency in Practice. J. A. M. A. 108: 15-20, 1937
109. Pillot, A.: Gastric Secretion in Vitamin A Deficiency, J. A. M. A., 99:180, 1932
110. Mori S.: Ueber den Sogeannteu Hikan. Jahrb f Kinderh, 59:175, 1904, cited by Ross in Am. J. Dis. Childhood, 22:232-43, 1921; Nutritional Keratomalacia.
111. Fridericksen, C.; Edmund, C.: Studies of Hypovitaminosis A. Am. J. Dis. Childhood, 53:89-109, 1937
112. Blackfan, K.: Early Recognition of Vitamin Deficiency States. New England J. Med. 215: 1159-62, 1936
113. Edmund, C.; Glemmesen, S. V.: Paraenteral Vitamin A Treatment of Dysaptatio in some Pregnant Vomen. Acta. Med. Scand. 89:69-92, 1936
114. Goodwin, G.P.: Cutaneous Manifestations of Vitamin A Deficiecny. Brit. Med. J. 2:113, 1934

115. Harris, L. J.: A Program of Nutrition Surveys. Lancet, 1:966068, April 1936
116. Cameron, H. C.: Effect of Vitamin A Upon the Incidence and Severity of Colds among Students. J. Am. Dietet. A. 11:189-204, Sept. 1935
117. Coward, K. H.; Morgan, B.G. E.: Quantitative Estimation of Vitamin A. and D in Various Foods Substances Cooked and Fresh. Brit. Med. J.2:1041-44, 1935
118. Rollet, J: Accidents d'automobile et Hemeralopie. Arch. d. Ophth. 51:73, 1934; cited by Jeghers in 36.
119. Vignalow, J.: L hemeralopie et le permis de conduire. de mid de Bordeaux, 110:692, 1933; cited by Jeghers in 36.
120. The Natl. Safety Council: Accident Facts. Chicago, inc. p. 42, 1936.
121. Mason, R. E.: Minimal Visual Requirements for Safe Automobile Driving. J. Missouri State Med. A. 32:367-69; Sept. 1935
122. Berens, C.; Smith, H. T.: Present Ophthalmoscopic Standards for Commercial Aviators in U. S. Am. Acad. Ophth and oto-laryng. 36:311, 1931