

1988

## Oral Assessment Guide

June Eilers

Ann Berger

Follow this and additional works at: [https://digitalcommons.unmc.edu/con\\_guides](https://digitalcommons.unmc.edu/con_guides)
























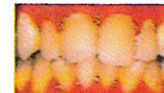


Part of the [Nursing Commons](#), and the [Oncology Commons](#)

---

# Oral Assessment Guide\*

Developed by  
the University of Nebraska  
Medical Center

Category	Voice	Swallow	Lips	Tongue	Saliva	Mucous membranes	Gingiva	Teeth, Dentures, or denture bearing area
Tools for Assessment	Auditory assessment	Observation	Visual/palpatory	Visual/palpatory	Tongue blade	Visual assessment	Tongue blade and visual assessment	Visual assessment
Methods of Measurement	Converse with patient	Ask patient to swallow. To test gag reflex, gently place blade on back of tongue and depress	Observe and feel tissue	Feel and observe appearance of tissue	Insert blade into mouth, touching the center of the tongue and the floor of the mouth	Observe appearance of tissue	Gently press tissue with tip of blade	Observe appearance of teeth or denture bearing area
<b>1</b> <small>Numerical and descriptive rating</small>	 Normal	 Normal swallow	 Smooth and pink and moist	 Pink and moist and papillae present	 Watery	 Pink and moist	 Pink and stippled and firm	 Clean and no debris
<b>2</b>	 Deeper or raspy	 Some pain on swallow	 Dry or cracked	 Coated or loss of papillae with shiny appearance with or without redness	 Thick or ropy	 Reddened or coated (increased whiteness) without ulcerations	 Edematous with or without redness	 Plaque or debris in localized areas (between teeth if present)
<b>3</b>	 Difficulty talking or painful	 Unable to swallow	 Ulcerated or bleeding	 Blistered or cracked	 Absent	 Ulcerations with or without bleeding	 Spontaneous bleeding or bleeding with pressure	 Plaque or debris generalized along gum line or denture bearing area

\* J. Eilers, RN, MSN et al 2-84 Rev 5-84, 4-85, 11-85  
Photographs courtesy of Simon W. Rosenberg, DMD,  
Memorial Sloan-Kettering Cancer Center

Special thanks to the personnel of the University of  
Nebraska Medical Center and to Simon W. Rosenberg, DMD,  
Memorial Sloan-Kettering Cancer Center

© 1983/1985 June Eilers,  
University of Nebraska Medical Center  
600 So. 42nd St., Omaha, NE 68198-2445