

Winter 2-7-2017

S4S8-RPA phosphorylation as an indicator of cancer progression in oral squamous cell carcinomas.

Jeff Rector
University of Nebraska Medical Center

Sasha Kapil
University of Nebraska Medical Center

Kelly J. Treude
University of Nebraska Medical Center

Phyllis Kumm
University of Nebraska Medical Center, pkumm@unmc.edu

Jason G. Glanzer
University of Nebraska Medical Center

See next page for additional authors

Tell us how you used this information in this [short survey](#).

Follow this and additional works at: https://digitalcommons.unmc.edu/cod_articles

 Part of the [Dentistry Commons](#)

Recommended Citation

Rector, Jeff; Kapil, Sasha; Treude, Kelly J.; Kumm, Phyllis; Glanzer, Jason G.; Byrne, Brendan M.; Liu, Shengqin; Smith, Lynette M.; DiMaio, Dominick J.; Giannini, Peter J.; Smith, Russell B.; and Oakley, Greg G., "S4S8-RPA phosphorylation as an indicator of cancer progression in oral squamous cell carcinomas." (2017). *Journal Articles: College of Dentistry*. 27.
https://digitalcommons.unmc.edu/cod_articles/27

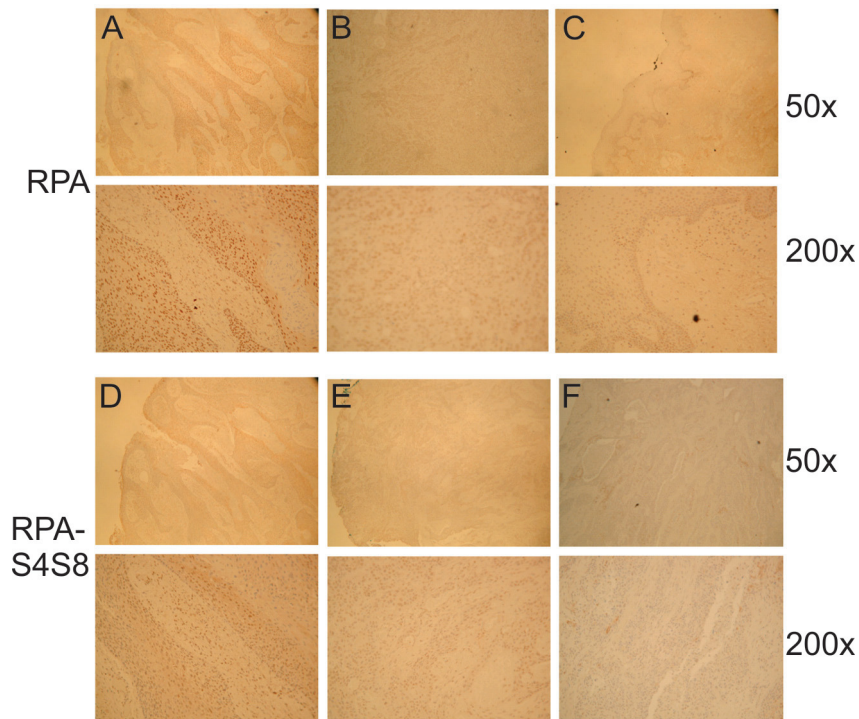
This Article is brought to you for free and open access by the College of Dentistry at DigitalCommons@UNMC. It has been accepted for inclusion in Journal Articles: College of Dentistry by an authorized administrator of DigitalCommons@UNMC. For more information, please contact digitalcommons@unmc.edu.

Authors

Jeff Rector, Sasha Kapil, Kelly J. Treude, Phyllis Kumm, Jason G. Glanzer, Brendan M. Byrne, Shengqin Liu, Lynette M. Smith, Dominick J. DiMaio, Peter J. Giannini, Russell B. Smith, and Greg G. Oakley

S4S8-RPA phosphorylation as an indicator of cancer progression in oral squamous cell carcinomas

Supplementary Materials



Supplementary Figure S1: Representative images of RPA (A, B, C) and S4S8-RPA (D, E, F) staining observed in OSCC via immunohistochemistry. Examples of representative of high (A, D), medium (B, E) and low (C, F) antibody signal at 50X and 200X.