



July 2022

## Hyperbaric Oxygen Therapy for Cerebral Radiation Necrosis Secondary to Stereotactic Radiation: A Case Series

Sruti Prathivadhi-Bhayankaram  
*University of Iowa Hospitals and Clinics*

jeffrey S. cooper  
*university of nebraska medical center*

Tell us how you used this information in this [short survey](#).

Follow this and additional works at: <https://digitalcommons.unmc.edu/gmerj>



Part of the [Higher Education Commons](#), and the [Therapeutics Commons](#)

### Recommended Citation

Prathivadhi-Bhayankaram, S., , cooper, j. S. Hyperbaric Oxygen Therapy for Cerebral Radiation Necrosis Secondary to Stereotactic Radiation: A Case Series. Graduate Medical Education Research Journal. 2022 Jul 14; 4(1).  
<https://digitalcommons.unmc.edu/gmerj/vol4/iss1/7>

This Original Report is brought to you for free and open access by DigitalCommons@UNMC. It has been accepted for inclusion in Graduate Medical Education Research Journal by an authorized editor of DigitalCommons@UNMC. For more information, please contact [digitalcommons@unmc.edu](mailto:digitalcommons@unmc.edu).

---

# Hyperbaric Oxygen Therapy for Cerebral Radiation Necrosis Secondary to Stereotactic Radiation: A Case Series

## Abstract

**Introduction:** Stereotactic radiosurgery (SRS) is an excellent option for the treatment of numerous central nervous system diseases. There exist several forms of SRS, including gamma-knife surgery (GKS) and cyber-knife surgery. The most significant complication of SRS is the delayed effects of therapeutic radiation, also known as radionecrosis. The current treatment options for radionecrosis have a significant side effect profile and posit challenges for medical management. More recently, hyperbaric oxygen therapy (HBO2) has emerged as an option for treatment with minimal side effects.

**Methods:** We present a retrospective case series examining ten patients treated with HBO2 after receiving radiotherapy. Of these cases, six were treated with GKS, two were treated with cyber-knife surgery, and two with Intensity-modulated radiation therapy (IMRT).

**Results:** In all ten cases, the patients reported significant improvement in clinical symptoms.

**Conclusions:** These cases demonstrate the efficacy of HBO2 as a treatment for cerebral radionecrosis.

## Keywords

Hyperbaric oxygen therapy, stereotactic radiation, cyber-knife surgery, gamma-knife surgery, cerebral necrosis

## Creative Commons License



This work is licensed under a [Creative Commons Attribution-Noncommercial-No Derivative Works 4.0 License](https://creativecommons.org/licenses/by-nc-nd/4.0/).

# Hyperbaric Oxygen Therapy for Cerebral Radiation Necrosis Secondary to Stereotactic Radiation: A Case Series

Sruti Prathivadhi-Bhayankaram<sup>1</sup>, Jeffrey S. Cooper<sup>2</sup>

<sup>1</sup>University of Iowa, Hospitals and Clinics, Department of Internal Medicine

<sup>2</sup>University of Nebraska Medical Center, College of Medicine, Department of Emergency Medicine

<https://doi.org/10.32873/unmc.dc.gmerj.4.1.004>

## Abstract

**Introduction:** Stereotactic radiosurgery (SRS) is an excellent option for the treatment of numerous central nervous system diseases. There exist several forms of SRS, including gamma-knife surgery (GKS) and cyber-knife surgery. The most significant complication of SRS is the delayed effect of therapeutic radiation, also known as radionecrosis. The current treatment options for radionecrosis have a significant side effect profile and posit challenges for medical management. More recently, hyperbaric oxygen therapy (HBO2) has emerged as an option for treatment with minimal side effects.

**Methods:** We present a retrospective case series examining ten patients treated with HBO2 after receiving radiotherapy. Of these cases, six were treated with GKS, two were treated with cyber-knife surgery, and two with Intensity-modulated radiation therapy (IMRT).

**Results:** In all ten cases, the patients reported significant improvement in clinical symptoms.

**Conclusions:** These cases demonstrate the efficacy of HBO2 as a treatment for cerebral radionecrosis.

## Introduction

Hyperbaric oxygen therapy (HBO2) involves breathing pressurized oxygen in a chamber to increase blood oxygen levels and improve cellular repair mechanisms. This therapy has been used for complications of radiation treatment and certain non-healing wounds. However, there are limited reports on the use of HBO2 in treating cerebral necrosis due to late radiation effects. Our study aims to demonstrate the efficacy and role of HBO2 in treating cerebral radiation necrosis by discussing several patients in a case series.

Although more known for treating infections and decompression sickness, HBO2 has previously been used for various cerebral complications. HBO2 has been used for cases of acute stroke, spinal cord injuries, meningitis, cerebral abscesses, and cerebral

edema.<sup>1</sup> HBO2 has also been used as prophylaxis and treatment for radiation myelitis.<sup>2</sup> More recently, HBO2 has also been used to treat sequelae of radiation therapy to the brain in a manner similar to its use in treating other soft tissue and bony radionecrosis.

In reviewing the current literature, there are a few reported cases of HBO2 in treating acute radiation effects after stereotactic radiation for AVMs. These reports showed resolution of cerebral edema and hemiparesis.<sup>3</sup> These reports demonstrate that HBO2 may be a minimally invasive option for treating radiation necrosis and acute post-treatment edema. However, many of these cases strictly consider gamma-knife surgery (GKS) and fail to account for other forms of radiation therapy. The outcomes are variable, with inconsistent results across cases.<sup>4</sup> Other studies describe the use of HBO2 in radiation-induced necrosis by monitoring outcomes in terms of clinical and radiological improvement. However, these reports are few, and a more extensive reservoir of data is needed to establish the role of HBO2.<sup>5</sup>

Our study adds to current data by considering central nervous system injury cases secondary to stereotactic radiation by CyberKnife, GKS, and intensity-modulated radiation therapy (IMRT). HBO2 can be an efficacious treatment for late radiation effects on the brain, and our case series aids in establishing its role in this landscape.

## Methods

This case series is a retrospective analysis of ten patients with post-radiation central nervous system injury at a tertiary care hospital's hyperbaric unit. Patients received hyperbaric oxygen with various protocols ranging from ninety minutes at 2.0-2.4 ATA and ranging from 8 to 60 treatments.

The University's Institutional Review Board approved this study (0101-21-EP). Electronic chart records from the hyperbaric unit were obtained. Patients were selected based on central nervous system injury after radiation treatment. A chart review of the ten patients

was conducted, noting their diagnosis, the type and amount of radiation, hyperbaric oxygen treatment, and clinical outcome. Pre- and post-clinical assessments were reviewed, as were radiological findings when available. A review of our results may be found in Table 1.

## Case Descriptions

### Case 1

A 19-year-old female presented with an arteriovenous malformation (AVM) affecting the left paramedian frontoparietal hemisphere. Due to the proximity of her malformation to the thalamocortical and corticospinal tracts, she underwent GKS as she was not a candidate for surgical intervention. After receiving her first dose at 1600 cGy, her AVM persisted, and she continued to have symptoms. Roughly three years after her first dose, she underwent repeat SRS, receiving another 1600 cGy dose. The patient developed seizures eight months after this dose with new right-sided weakness and worsening headaches. MRI showed substantial edema and radiation necrosis.

HBO2 was initiated two weeks after her first seizure. She received eight sessions of hyperbaric oxygen therapy at 2.4 ATA for 90 minutes before her course was complicated by worsening headaches with seizures. A CT scan at that time showed no interval change. Hyperbaric oxygen treatment was continued at decreased pressure (2.0 ATA to reduce seizure risk from oxygen toxicity) for 32 more sessions for a total of 40. She continued dexamethasone during her hyperbaric course.

MRI after treatment showed improvement and the patient reported decreased severity in her headaches and less frequent seizures.

### Case 2

A 39-year-old male with a left periventricular frontal lobe tangle of vessels. A fusiform dilated early enhancing left anterior caudate vein was identified that drained this left frontal AVM. He declined endovascular intervention, so he was treated with GKS and corticosteroids. He received 2000 cGy in one fraction. Before diagnosing the arteriovenous

**Table 1.**

A review of all cases in this series, with demographics, diagnosis, radiation therapy, time between radiation and hyperbaric treatment, and number of hyperbaric treatments listed. As noted, there was evidence of clinical improvement across all cases.

	Age/Sex	Diagnosis	Radiation Treatment	Months between radiation and HBO2	HBO2* Pressure and # of treatments	Clinical Outcome
1	19F	Paramedian frontoparietal AVM	Gamma-Knife 3200 cGy	8	2.4 ATA x 8 à 2.0 ATA x 32	Improved headaches, decreased seizures
2	39M	Left periventricular AVM	Gamma-Knife 2000 cGy	11	2.0 ATA x 37	Resolved headaches, stable vision 20/50 OU
3	54F	Craniopharyngioma	CyberKnife 2100 cGy + IMRT 5040 cGy	53	2.0 ATA x 60	Vision returned to baseline
4	8F	WHO Grade III Astrocytoma	IMRT 5940 cGy	10	2.0 ATA x 40	Weaned off steroid with stable mass
5	44M	Traumatic brain injury, trigeminal neuralgia	CyberKnife 6000 cGy	23	2.0 ATA x 40	Improved sensation and vision
6	8F	Right cerebellar AVM	Gamma-Knife 1800 cGy	5	2.0 ATA x 40	Improved speech, eating, and walking
7	58M	Metastatic non-small squamous cell cancer to the right occipital lobe	IMRT 4000 cGy	79	2.0 ATA x 40	Improved Vision
8	41F	Right parietal AVM	Gamma-Knife 1800 cGy	13	2.4 ATA x 60	Increased sensation, improved mood, numbness
9	49F	Dural L occipital AVM	Gamma-Knife 4353 cGy	117	2.0 ATA x 29, then 30+10	Improved headaches and vision
10	49M	Right posterior thalamic AVM	Gamma-Knife 2000 cGy	11	2.0 ATA x 40	Increased range of motion of extremities, improved sensation. Persistent but markedly improved hemiplegia.

Note: HBO2 = hyperbaric oxygen treatment; \*All treatments were 90 minutes plus compression/decompression time and air breaks (if indicated).

malformation, the patient had a long history of vision problems and headaches. His vision had been progressively declining despite corrective lenses.

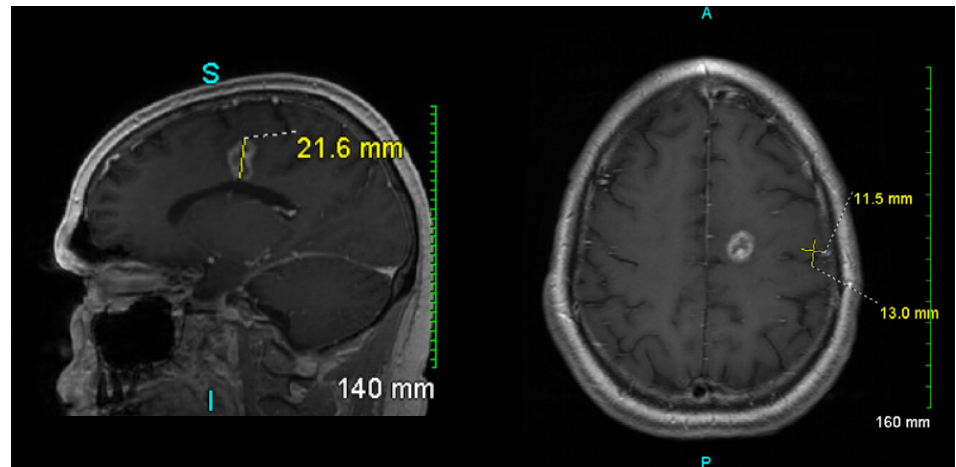
After his radiation therapy, the patient reported worsening headaches. Almost a year from GKS, imaging showed an enhancing left frontal lobe lesion, suggestive of radiation necrosis with mildly decreased surrounding edema/gliosis (Figure 1). Based on his diagnosis and imaging results, the patient was started on hyperbaric oxygen treatment at 2.0 ATA receiving 37 treatments of 90 minutes. He continued low-dose steroids throughout this course.

After therapy, follow-up MRI showed resolving necrotic changes from his radiation therapy with the lesion decreased in size (Figure 2). His headaches fully resolved, but he reported no changes in his vision.

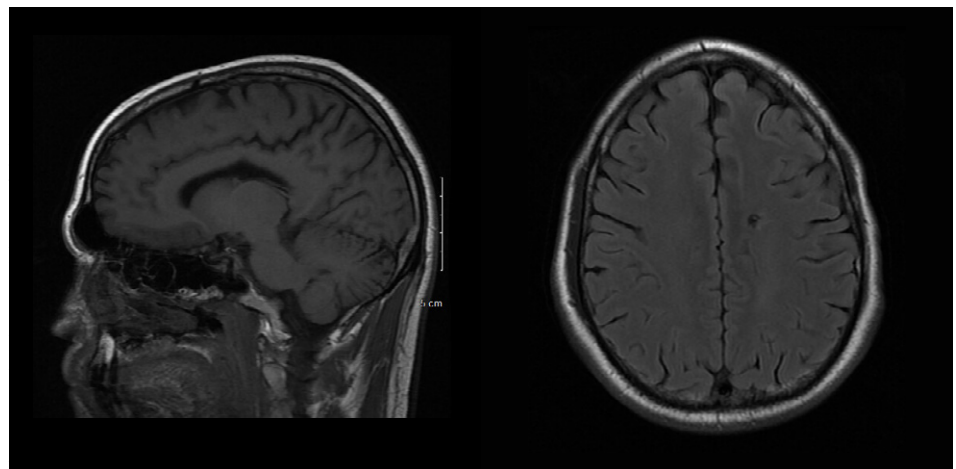
### Case 3

A 54-year-old female underwent resection of a craniopharyngioma followed by CyberKnife radiation at 700 cGy. This patient's tumor reoccurred and was again treated with stereotactic radiation treatment, three rounds

**Figure 2.** MRI roughly nine months after hyperbaric treatment. Decreased enhancing focus on the superior left frontal lobe with evidence of resolving surrounding vasogenic edema.



**Figure 1.** MRI prior to HBO2, roughly 19 months after completion of SRS. Enhancing left frontal lobe lesion with areas of restricted diffusion indicating radiation necrosis with mildly decreased surrounding edema/gliosis.



mass size on serial CT of the brain or increased symptoms. Although there was no improvement in symptoms, being able to discontinue steroids was a significant positive outcome.

#### Case 5

A 44-year-old-male sustained a traumatic brain injury with residual left-sided weakness and debilitating right-sided trigeminal neuralgia. He was treated with CyberKnife surgery at 6000 cGy in one treatment to the right trigeminal nerve. An MRI at that time was normal, with no lesions noted.

Roughly 23 months afterward, the patient developed left homonymous hemianopsia with episodes of confusion and muscle twitching. An MRI was suspicious for changes in the medial temporal lobe. Subsequent biopsies revealed only non-specific reactive gliosis. Following discussion with the neurosurgeons and neuroradiologists, the gliosis was felt to be soft tissue radionecrosis of the brain due to the delayed effects of his prior therapeutic radiation.

The patient received hyperbaric oxygen, 2.0 ATA for 40 treatments. The patient reported significant improvement in his visual fields, overall strength and denied any further periods of confusion. These were all identified as positive outcomes by the patient.

#### Case 6

An 8-year-old-female with a posterior AVM was treated with a ventriculostomy and embolization followed by resection. However, the patient presented with repeated episodes of incoordination afterward. MRI showed several left cerebral infarcts. The patient was treated with subsequent embolization followed by craniotomy and resections. Repeat MRI suggested a recurrent Martin Grade 3 AVM.

The patient then underwent Gamma Knife treatment at a single fraction of 1800 cGy (Figure 3). One-month post-radiation treatment, the patient began experiencing new cranial nerve palsies. Subsequent MRI findings demonstrated radiation-induced changes in the pons, with worsening necrosis over several months seen on serial imaging.

Hyperbaric oxygen was suggested for these radiation changes. She received 40 treatments at 2.0 ATA. Post-therapy, the patient showed improvements in speech, eating, and walking. Repeat MRI showed no significant changes but no evidence of arteriovenous malformation recurrence or progression.

#### Case 7

A 58-year-old-male with a history of non-small cell lung cancer with metastasis to the right occipital lobe was treated with craniotomy and whole-brain radiation. The patient received 20 fractions of IMRT totaling 4000 cGy. After radiation treatment, the patient developed progressive visual field defects over the years and some cognitive deficits.

The patient was treated at 2.0 ATA for 40 treatments with significant improvement in his vision.

#### Case 8

A 41-year-old-female with a history of a primary parenchymal hemorrhage likely due to cavernous or vascular malformations underwent stereotactic radiosurgery. She underwent a single fraction of stereotactic radiosurgery to a small right parietal AVM (1800 cGy). After her treatment, she developed subsequent weakness, numbness, and paresthesia in her lower extremities. MRI findings demonstrated vasogenic edema, midline shift, and signs of radiation necrosis

secondary to delayed radiation injury.

Due to her persistent symptomology and history of stereotactic radiotherapy, the patient was referred for hyperbaric oxygen treatment one year post GKS. Her progression of symptoms stopped and started to improve by 20 treatments. She received 40 treatments at 2.4 ATA, followed by an additional 20 treatments due to ongoing improvement in her clinical symptoms. The patient noted improvement in her overall mood, weakness, and numbness in her extremities, and she regained the ability to do household chores and walk long distances.

#### Case 9

A 52-year-old female with a history of a left occipital dural AVM underwent embolization and GKS therapy. She developed progressive vision loss approximately seven years after radiation therapy. Hyperbaric oxygen therapy was initiated.

Initially, the patient planned to complete 40 treatment cycles. However, the patient developed severe headaches secondary to a newly developed radiation-induced cavernous malformation of the left occipital region and only completed 29. Seven years following this, she lost more of her peripheral vision, with increased edema and radionecrosis noted on MRI. Further hyperbaric oxygen therapy was started in conjunction with craniotomy to resect the remaining cavernous malformation. The patient tolerated the treatment well and showed definitive improvement of her headaches and vision after completing 30 pre-operative and ten postoperative treatments at 2.0 ATA.

#### Case 10

A 49-year-old male was found to have a Spetzler-Martin right posterior thalamic AVM. He underwent stereotactic radiosurgery with

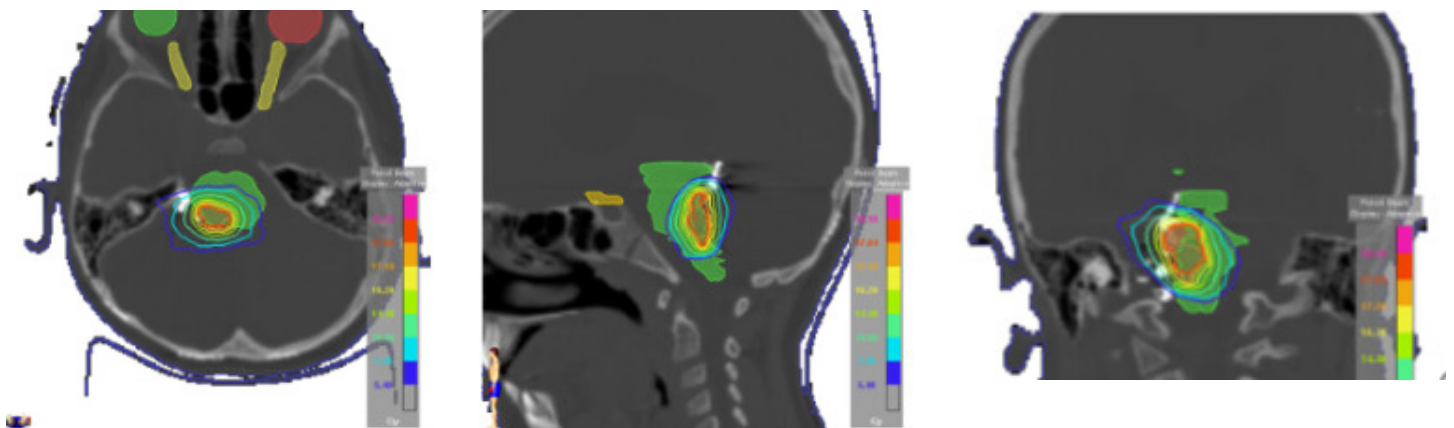


Figure 3. Dose distribution of 1800 cGy at 100% of the isodose line.



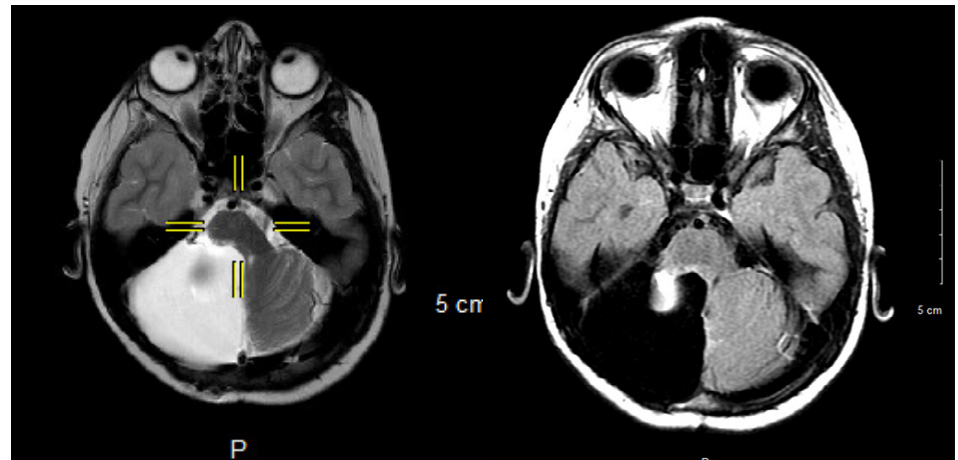
initial improvement but developed left-sided hemiplegia eleven months afterward. MRI findings were suspicious for soft tissue radionecrosis. Following neurosurgical evaluation, hyperbaric oxygen therapy was started to reverse the delayed vascular effects of radiation injury.

The patient underwent 40 HBO2 treatments at 2.0 ATA. He reported considerable improvement in his extremities with a marked increase in range of motion and strength on his left side.

## Discussion

SRS has grown into an important treatment option for various neurological diseases, including AVMs and certain central nervous system tumors. As patient survival improves, there has also been an increasing number of cases of cerebral necrosis secondary to SRS and radiation therapy.<sup>6</sup> HBO2 is a viable treatment option for treating such radiation effects. Nevertheless, there is a paucity of cases regarding the use of hyperbaric oxygen in treating this complication. Leber et al. reported two patients with radionecrosis after GKS for AVMs. Both patients showed significant radiological improvement with HBO2.<sup>7</sup> Kohshi et al. published a case report of a patient with resolved radiation necrosis after two rounds of HBO2.<sup>8</sup> Chuba et al. reviewed a case series of ten pediatric patients treated with HBO2 after biopsy-confirmed radiation necrosis for various cerebral tumors. These patients had varying degrees of improvement, showing clinical recovery in some cases, with one case requiring reoperation for mass effect after initial improvement.<sup>5</sup> Lynn et al. published a case report of with radiation-induced sequelae after SRS treatment for AVMs. The patient demonstrated significant improvement in his clinical symptoms and complete resolution of the AVM with minimal neurological deficits.<sup>2</sup> Lastly, Valado et al. published a retrospective case series examining ten patients who underwent HBO2 after post-radiation injury to the central nervous system. In patients with radiation necrosis, HBO2 led to improvement in clinical and radiologic outcomes.<sup>4</sup> While these reports are promising, it is important to continue adding data to examine the role of HBO2 as a treatment option for future patients.

Currently, the only major therapy available to patients with radiation-induced cerebral injury is steroids, often accompanied by severe side effects and disadvantages.<sup>4</sup> Steroids have a notable history of severe side effects and disadvantages, including tissue breakdown



**Figure 4.** MRI findings suggestive of radiation necrosis. (Left) A restricted focal diffusion superiorly and laterally in the pons is suggestive of ischemia. (Right) Dorsal pons and superior dorsal mainstem demonstrate T2 hyperintensity compatible with an evolving infarct. (we may have missed it- but where is this Figure 4 referenced in the text of the manuscript)

HBO2 addresses many of the underlying issues regarding radiation injury to the central nervous system. As HBO2 increases tissue oxygen levels, it can create an oxygen gradient between radiated and nonradiated tissue.<sup>3</sup> As oxygen drives angiogenesis in a gradient-dependent manner, this creates a stimulus for vascularization in areas of radiated tissue. This is critical, as radiated tissue does not spontaneously revascularize like other wound areas due to the unique physics and injury pattern caused by irradiation. The physiochemical response from oxygen therapy helps the body recognize the radiated area as a wound, promoting angiogenesis.<sup>4</sup> Moreover, HBO2 causes cerebral vasoconstriction, resulting in a decrease in cerebral blood flow (while maintaining oxygen delivery). This mechanism ameliorates cerebral edema, among other radiation sequelae.<sup>10</sup> There is evidence that HBO2 offers a neuroprotective effect to the brain by decreasing instances of ischemia and edema. Hyperbaric therapy activates anti-apoptotic factors, such as BCL02 and reduces inflammation at the site of ischemia.<sup>4</sup> There is also evidence that HBO2 leads to blood-brain barrier stability.<sup>4</sup>

Interestingly, some studies have postulated that treatment with HBO2 after radiation therapy should be delayed. Valadao et al. argue that there is insufficient data to determine whether immediate or delayed treatment is advantageous.<sup>4</sup> Ashmalla et al. have previously studied the effect of HBO2 on treating radiation-induced sequelae in children and show that the interval between radiation therapy and HBO2 was irrelevant to clinical outcomes in their cases. In our retrospective

of radiotherapy. The two most common modalities of SRS are GKS and CyberKnife. The concept behind these modalities is simple, GKS concentrates beams from different angles in a precise spot within the central nervous system, allowing for a focused radiation dose. In contrast, CyberKnife radiotherapy uses adaptive image-guided radiation to track targets in both space and time. Compared to GKS, this technology allows CyberKnife patients to undergo radiotherapy in a frameless setting.<sup>11</sup> Studies have shown fractionated CyberKnife therapy to be as effective and safe as single-fraction GKS for treating brain tumors, despite CyberKnife therapy having slightly inferior dosimetric properties.<sup>12</sup> As CyberKnife therapy is relatively new, current literature in assessing the difference between these two forms of SRS are ongoing, including the rates of developing radiation necrosis. Zhuang et al. have shown the dosimetric properties to be the most relevant factor in developing radiation necrosis in CyberKnife therapies.<sup>13</sup> Inoue et al. suggest the surrounding brain volume circumscribed within a single dose plays a more prominent role.<sup>14</sup> In contrast, studies demonstrating tumor volume, in addition to dosimetric properties, are more relevant in predicting rates of radiation necrosis in GKS.<sup>15,16</sup> As there are no established standards to diagnose radiation necrosis noninvasively, it is difficult to know when patients begin to develop this disease or if the irradiation method is relevant.<sup>17</sup> Regardless, our case series illustrates clinical improvement of radiation necrosis from IMRT in 2 cases, with fractionated CyberKnife therapy in 2 cases and GKS in 6 other cases. Most of the relevant literature focuses on the

role of HBO2 in cases of GKS.<sup>11,12,15</sup> In the few reports of HBO2 used in CyberKnife surgeries, the therapy is compounded with other treatments, and its efficacy is labeled controversial.<sup>18,19</sup> We demonstrate cases where HBO2 leads to clinical improvement regardless of radiation form.

Based on our experience, hyperbaric oxygen has the potential to be a standard protocol

for radiation-induced central nervous system injury. We discuss ten patients with various doses and types of radiation across various ages; all cases demonstrated clinical improvement after HBO2. This case series adds to the few studies in the literature reiterating the role of HBO2 as a valuable therapeutic option for treating radiation-induced cerebral necrosis. ■

## References

- Desola J. Current indications for hyperbaric oxygen therapy. *FMC Form Medica Contin en Aten Primaria*. 2009;16(8):507-523. doi:10.1016/S1134-2072(09)72308-4
- Lynn M, Friedman WA. Hyperbaric oxygen in the treatment of a radiosurgical complication: Technical case report. *Neurosurgery*. 2007;60(3):39-42. doi:10.1227/01.NEU.0000255343.41206.6F
- Wanebo JE, Kidd GA, King MC, et al. Hyperbaric oxygen therapy for treatment of adverse radiation effects after stereotactic radiosurgery of arteriovenous malformations: case report and review of literature. *Surg Neurol*. 2009;72(2):162-167. doi:10.1016/j.surneu.2008.03.037
- Valadão J, Pearl J, Verma S, et al. Hyperbaric oxygen treatment for post-radiation central nervous system injury: A retrospective case series. *Undersea Hyperb Med*. 2014;41(2):87-96.
- Chuba PJ, Aronin P, Bhambhani K, et al. Hyperbaric oxygen therapy for radiation-induced brain injury in children. *Cancer*. 1997 Nov 15;80(10):2005-12.
- Song YP, Colaco RJ. Radiation Necrosis – A Growing Problem in a Case of Brain Metastases Following Whole Brain Radiotherapy and Stereotactic Radiosurgery. *Cureus*. 2018;10(1). doi:10.7759/cureus.2037
- Leber KA, Eder HG, Kovac H, et al. Treatment of cerebral radionecrosis by hyperbaric oxygen therapy. *Stereotact Funct Neurosurg*. 1998 Oct;70 Suppl 1:229-36.
- Kohshi K, Imada H, Nomoto S, et al. Successful treatment of radiation-induced brain necrosis by hyperbaric oxygen therapy. *J Neurol Sci*. 2003;209(1-2):115-117. doi:10.1016/S0022-510X(03)00007-8
- Vellayappan B, Tan CL, Yong C, et al. Diagnosis and Management of Radiation Necrosis in Patients With Brain Metastases. *Front Oncol*. 2018;8(September):2-10. doi:10.3389/fonc.2018.00395
- Lanse SB, Lee JC, Jacobs EA, et al. Changes in the permeability of the blood-brain barrier under hyperbaric conditions. *Aviat Sp Environ Med*. 1978;49(7):890-894. doi:10.1097/00006534-197905000-00074
- Sio TT, Jang S, Lee S-W, et al. Comparing Gamma Knife and CyberKnife in patients with brain metastases. *J Appl Clin Med Phys*. 2014;15(1):14-26. doi:10.1120/jacmp.v15i1.4095
- Cho YH, Lee JM, Lee D, et al. Experiences on two different stereotactic radiosurgery modalities of Gamma Knife and Cyberknife in treating brain metastases. *Acta Neurochir (Wien)*. 2015;157(11):2003-2009. doi:10.1007/s00701-015-2585-3
- Zhuang H, Zheng Y, Wang J, et al. Analysis of risk and predictors of brain radiation necrosis after radiosurgery. *Oncotarget*. 2016;7(7):7773-7779. doi:10.18632/oncotarget.6532
- Inoue HK, Seto KI, Nozaki A, et al. Three-fraction CyberKnife radiotherapy for brain metastases in critical areas: referring to the risk evaluating radiation necrosis and the surrounding brain volumes circumscribed with a single dose equivalence of 14 Gy (V14). *J Radiat Res*. 2013;54(4):727-735. doi:10.1093/jrr/rrt006
- Chin LS, Ma L, DiBiase S. Radiation necrosis following gamma knife surgery: A case-controlled comparison of treatment parameters and long-term clinical follow up. *J Neurosurg*. 2001;94(6):899-904. doi:10.3171/jns.2001.94.6.0899
- Korytko T, Radivoyevitch T, Colussi V, et al. 12 Gy gamma knife radiosurgical volume is a predictor for radiation necrosis in non-AVM intracranial tumors. *Int J Radiat Oncol Biol Phys*. 2006;64(2):419-424. doi:10.1016/j.ijrobp.2005.07.980
- Chao ST, Ahluwalia MS, Barnett GH, et al. Challenges with the diagnosis and treatment of cerebral radiation necrosis. *Int J Radiat Oncol Biol Phys*. 2013;87(3):449-457. doi:10.1016/j.ijrobp.2013.05.015
- Jiang Z, Wang Q, Yang G, et al. Optimized treatment with RF thermotherapy and immunotherapy combined with CyberKnife for advanced high-risk tumors: A clinical trial report. *Biomed Reports*. 2014;2(2):245-249. doi:10.3892/br.2014.218
- Wang Y, Wang E, Pan L, et al. A new strategy of CyberKnife treatment system based radiosurgery followed by early use of adjuvant bevacizumab treatment for brain metastasis with extensive cerebral edema. *J Neurooncol*. 2014;119(2):369-376. doi:10.1007/s11060-014-1488-0