



June 2023

Laser-Assisted Delivery of Trichloroacetic Acid for Successful Treatment of Persistent Facial Hyperpigmentation

Katherine Plampton et. al.
University of Nebraska Medical Center

Tell us how you used this information in this [short survey](#).

Follow this and additional works at: <https://digitalcommons.unmc.edu/gmerj>



Part of the [Higher Education Commons](#), and the [Medicine and Health Sciences Commons](#)

Recommended Citation

Plampton, K. Laser-Assisted Delivery of Trichloroacetic Acid for Successful Treatment of Persistent Facial Hyperpigmentation. *Graduate Medical Education Research Journal*. 2023 Jun 30; 5(1).
<https://digitalcommons.unmc.edu/gmerj/vol5/iss1/68>

This Conference Proceeding is brought to you for free and open access by DigitalCommons@UNMC. It has been accepted for inclusion in *Graduate Medical Education Research Journal* by an authorized editor of DigitalCommons@UNMC. For more information, please contact digitalcommons@unmc.edu.

Laser-Assisted Delivery of Trichloroacetic Acid for Successful Treatment of Persistent Facial Hyperpigmentation

Creative Commons License



This work is licensed under a [Creative Commons Attribution-Noncommercial-No Derivative Works 4.0 License](https://creativecommons.org/licenses/by-nc-nd/4.0/).

Laser-Assisted Delivery of Trichloroacetic Acid for Successful Treatment of Persistent Facial Hyperpigmentation

Katherine Plampton¹, **Ritu Swali**¹, Ronald J. Sulewski¹

¹Department of Dermatology, College of Medicine, University of Nebraska Medical Center

Mentor: Ronald J. Sulewski

Program: Dermatology

Type: Case Report

Background: Hyperpigmentation is a common cosmetic dermatology concern that can be difficult to treat. Standard treatment options include various skin lightening topical and oral medications, as well as in-office options such as chemical peels and laser treatments. While laser-assisted drug delivery is an emerging treatment in the field of dermatology, there are no reports in the literature of laser-assisted delivery of trichloroacetic acid (TCA), a chemical peel commonly used for hyperpigmentation.

Case: A 35-year-old female, with previous use of injectables (botulinum toxin and dermal fillers), presented with dynamic rhytids and hyperpigmentation. The patient reported using sunscreen and antioxidant serum (SkinCeuticals CE ferulic) daily. On physical examination, there were scattered brown macules on the face and a brown patch on the left upper lip. The patient initially underwent treatment with a series of four single pass TCA 15% peels to the face in 1-month intervals, with an additional pass of TCA 25% to the upper lip and cheeks in the latter two sessions. The patient reported improved hyperpigmentation, but with a persistent brown patch on the upper lip.

Eight months later, the patient underwent laser-assisted delivery of TCA 15% during full face treatment with Fraxel Dual for the patch on the left upper lip [Settings: wavelength 1927 nm, 10 mJ, treatment level 4 (35%), 8 passes, 1.43KJ]. The treatment resulted in significant improvement of the hyperpigmented patch on the upper lip (Figure 1).

Conclusion: In this case, laser assisted delivery was successfully utilized for better penetration of TCA and resulting improvement in facial hyperpigmentation.

<https://doi.org/10.32873/unmc.dc.gmerj.5.1.067>

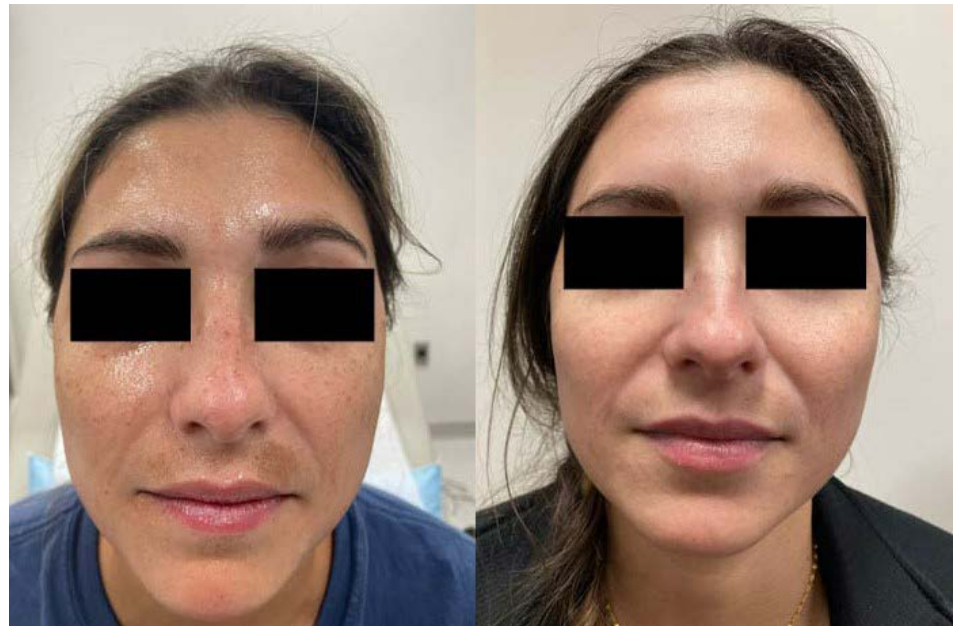

Figure 1: Before and After Laser-Assisted Delivery of TCA

Not your Typical Lateral Ankle Sprain

Rachel Sundman¹, Jason Meredith¹

¹Department of Family Medicine, College of Medicine, University of Nebraska Medical Center

Mentor: Jason Meredith

Program: Family Medicine

Type: Case Report

Background: Extensor digitorum brevis (EDB) avulsions present with anterior tenderness below the anterior talofibular ligament after inversion ankle injury. This injury can be misdiagnosed as normal anatomy, sprain, or another type of fracture. Misleading anatomy includes the os peroneum and sesamoid bone. Fractures that can be misdirecting include comminuted fracture of the cuboid, anterior process of calcaneus, and avulsion of calcaneofibular ligament (CFL).

Case: A 39-year-old male presents to sports medicine clinic for evaluation of right ankle injury. One week prior, he had been hiking in Colorado and had multiple inversion ankle injuries which led to swelling but denied limitations to activity. On his return trip he suffered another inversion injury going downstairs resulting in significant swelling and difficulty ambulating secondary to pain. Patient saw his primary care provider and Xray of right ankle revealing multiple fractures of unknown acuity. CT w/o contrast revealed acute to subacute mildly displaced avulsion fractures of the dorsal talus and anterolateral calcaneus. Given the location of his symptoms, our final diagnosis was an extensor digitorum brevis avulsion fracture. Patient utilized CAM boot for 4 weeks

followed by one-week progression out of CAM boot. Patient reported improvement in pain and ability to bear weight. He utilized an ASO ankle brace with activity and started physical therapy for proprioception retraining.

Conclusion: EBD avulsion is an atypical cause of lateral ankle pain and should be on the differential for inversion ankle injuries. Multiplanar imaging can assist in its diagnosis if plain films are nonconfirmatory.

<https://doi.org/10.32873/unmc.dc.gmerj.5.1.068>

Delayed Malignant Cerebellar Posterior Reversible Encephalopathy Syndrome secondary to CLAG-M and Venetoclax regimen

Isha Snehal¹, Subin Mathew¹

¹Department of Neurological Sciences, College of Medicine, University of Nebraska Medical Center

Mentor: Subin Mathew

Program: Neurological Sciences

Type: Case Report

Background: Isolated cerebellar malignant posterior reversible encephalopathy syndrome (PRES) is rare. We report a case of delayed malignant cerebellar PRES triggered by cladribine, cytarabine, granulocyte colony-stimulating factor, mitoxantrone (CLAG-M), and venetoclax regimen. PRES is a heterogeneous syndrome caused by multiple factors. Cerebellar PRES is commonly seen with autoimmune disease and rarely with chemotherapy.

Case: A 73-year-old male presented with a history of relapse after allogeneic stem cell

transplantation for refractory myelodysplastic syndrome on maintenance tacrolimus. He was admitted for salvage therapy with (CLAG-M) + venetoclax regimen. On day 16 post salvage therapy the patient developed acute onset altered mental status and headache followed by fever and hypotension. Brain MRI revealed posterior bilateral cerebellar, vermian edema with tiny petechial hemorrhages, ventriculomegaly, trans-ependymal edema, and mass effect on fourth ventricular effacement. Despite external ventricular drain placement, hyperosmolar therapy, and steroids, on day 19 the patient suffered a devastating neurological injury and the family opted for hospice care. Off note, maintenance tacrolimus was held prior to admission and was started 4 days prior to the onset of neurological symptoms with subtherapeutic levels.

Conclusion: The potential role of (CLAG-M) and venetoclax regimen in the pathogenesis of PRES needs to be considered. Cerebellar PRES is rare and can be complicated by early hydrocephalus and 4th ventricle compression. Although PRES is usually benign, prompt recognition of indicators of the malignant phenotype and aggressive management is crucial.

<https://doi.org/10.32873/unmc.dc.gmerj.5.1.069>

Intravenous Alteplase in CADASIL

Jennifer Shaw¹, Marco Gonzalez-Castellon¹, T. Scott Diesing¹

¹Department of Neurological Sciences, College of Medicine, University of Nebraska Medical Center

Mentor: Marco Gonzalez-Castellon

Program: Neurology

Type: Case Report

Background: Cerebral autosomal dominant arteriopathy with subcortical infarcts and leukoencephalopathy (CADASIL) is a genetic small vessel vasculopathy caused by mutations in the NOTCH3 gene that result in vasculopathic changes in cerebral small penetrating arteries, arterioles, and capillaries. Stroke is an important cause of morbidity and mortality. Theoretical concerns have been raised about the efficacy and safety of intravenous alteplase (IV tPA) in the treatment of small vessel stroke in these patients. However, there is little clinical evidence to validate or discredit these concerns.

Case: A 40-year-old female with a diagnosis of CADASIL presented to our emergency department for acute onset non-fluent aphasia and significant worsening of baseline left-sided hemiparesis. National Institutes of Health Stroke Score (NIHSS) was 12. Computed tomography (CT) did not show any signs of intracranial hemorrhage or large vessel occlusion. The patient presented within the window for IV tPA treatment, and no contraindications were identified. IV

tPA was administered with no immediate complications. Approximately 12 hours later, the patient had a brief episode of left-sided head deviation and prominent nystagmus concerning for focal seizure. Magnetic resonance imaging (MRI) showed a 3.2cm right frontal lobe intraparenchymal hemorrhage (Figure 1) and small acute infarcts in the right posterior internal capsule and left postcentral gyrus.

Conclusion: CADASIL carries a risk of bleeding, and the mechanism by which it causes small vessel stroke may be unrelated to thrombosis. Further study is necessary to determine if and/or which patients with CADASIL may benefit from IV tPA.

<https://doi.org/10.32873/unmc.dc.gmerj.5.1.070>

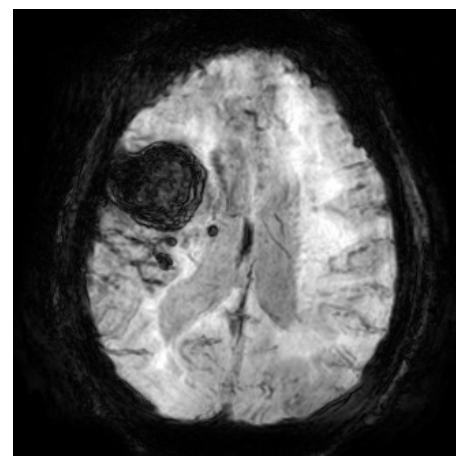


Figure 1: Axial MRI gradient echo (GRE) sequence showing right frontal lobe intraparenchymal hemorrhage and surrounding microhemorrhages

Hyperplasia Aphasia

AJ Lowe¹, Michael P. Smith¹

¹Department of Internal Medicine, College of Medicine, University of Nebraska Medical Center

Mentor: Michael P. Smith

Program: Internal Medicine

Type: Case Report

Background: A 56-year-old man presenting with one month of recurrent episodes of aphasia and seizure-like activity. He had no history of alcohol or illicit drug use, no recent fall or trauma event, and no headaches or recent infections.

Case: On presentation, he was afebrile and blood pressure was 151/85. He had proximal muscle weakness and bilateral lower extremity edema on exam. Additional examination findings were unremarkable. Initial lab work revealed blood glucose 294, potassium 2.3, and calcium 7.3 (ionized

calcium 1.07). Eight AM cortisol was 101, ACTH was 437, and DHEA-S was 180. PET scan revealed bilateral adrenal hyperplasia without any extra adrenal masses. MRI of the pituitary revealed a 1-2 mm hypodensity, and inferior petrosal sinus sampling was performed. He subsequently underwent bilateral adrenalectomy and was placed on a hydrocortisone plus fludrocortisone steroid taper.

Conclusion: The adrenal glands secrete glucocorticoids, mineralocorticoids, and sex hormones, which are regulated by the hypothalamic-pituitary-adrenal (HPA) axis. Increased plasma ACTH concentrations cause bilateral adrenocortical hyperplasia. Overactive adrenal glands resulting in hypercortisolism can lead to elevated blood glucose levels due to increased

glucocorticoid activity. Further, increased mineralocorticoid activity can cause hypokalemia and hypertension from the effects of abnormal aldosterone secretion. This patient was diagnosed with Cushing's disease secondary to a pituitary tumor. The treatment of choice for Cushing's disease (ACTH-producing pituitary tumor) is transsphenoidal microadenomectomy when a microadenoma can be identified. Pituitary irradiation can also be considered. Ultimately, bilateral total adrenalectomy with lifelong daily glucocorticoid (eg, hydrocortisone) and mineralocorticoid (eg, fludrocortisone) replacement therapy is the final definitive cure.

<https://doi.org/10.32873/unmc.dc.gmerj.5.1.071>

Atrial Flutter due to Amiodarone-Induced Thyrotoxicosis Months after Discontinuation

Ellen Horstmann¹, Dalton Nelsen¹

¹Department of Emergency Medicine, College of Medicine, University of Nebraska Medical Center

Mentor: Dalton Nelsen

Program: Emergency Medicine

Type: Case Report

Background: A 59-year-old male with one prior episode of atrial flutter postoperatively two years ago presented in acute atrial flutter with rapid ventricular response (RVR) and acute hyperthyroidism secondary to amiodarone-induced thyrotoxicosis (AIT) despite amiodarone having been discontinued months before.

Case: The patient presented to the Emergency Department for tachycardia, incidentally noted on a blood pressure machine at home. He reported fatigue and chronic bilateral

lower limb edema as his only symptoms. EKG showed atrial flutter with RVR. He had one single prior episode of atrial flutter with RVR following coronary artery bypass graft surgery two years prior. He had subsequently been started on Amiodarone and Warfarin, but Amiodarone had been discontinued six months ago. Free T4 was 5.0 ng/dL with undetectably low TSH of <0.010mIU/ml. The patient was admitted for further work-up. A thyroid ultrasound did not show any abnormalities. Thyroid stimulating immunoglobulin was not elevated. Endocrinology felt his presentation was most consistent with AIT. The patient was treated with propranolol, methimazole, prednisone and cholestyramine. After improvement in heart rate and thyroid levels he underwent successful DCCV cardioversion.

Conclusion: This is an unusual case of atrial flutter secondary to AIT. What makes it notable is amiodarone was discontinued six months prior. It has been noted AIT can develop even several months after discontinuing amiodarone and total body iodine stores can take up to nine months to decrease after drug discontinuation. This case highlights the importance of detailed medication review and targeted workup to determine underlying cause of a condition.

<https://doi.org/10.32873/unmc.dc.gmerj.5.1.072>

Rabbit Allergy and Kidney Transplant: What's the connection?

Debra Wekesa¹, Scott Westphal¹, Eric Langewisch¹

¹Department of Internal Medicine, College of Medicine, University of Nebraska Medical Center

Mentor: Scott Westphal

Program: Internal Medicine

Type: Case Report

Background: An anti-thymocyte globulin (ATG, Thymoglobulin®) is a polyclonal, anti-human thymocyte antibody derived from rabbits, used for lymphocyte depleting

induction immunosuppression in solid organ transplantation. Despite its routine use in transplantation, reports of life-threatening anaphylaxis are extremely rare.

Case: A 37-year-old woman presented for a kidney transplant. She received midazolam, propofol, lidocaine, rocuronium, fentanyl for anesthesia, preoperative cefazolin, followed by antithymocyte globulin. Shortly

thereafter she developed shock and ultimately cardiac arrest. With CPR and aggressive hemodynamic support, she achieved return of spontaneous circulation and did eventually recover, although her transplant surgery was aborted. Serum tryptase was elevated (consistent with mast cell degranulation). Subsequent allergy skin prick testing was negative, except ATG which was positive at a 1:1,000 dilution, and elevated serum antigen

specific IgE to rabbit was noted. The patient reported prior exposure to rabbits (home pets) with history of ocular pruritus, rhinorrhea, sneezing, but no prior history of anaphylaxis to rabbits or other substances.

Conclusion: While rabbit allergies or allergies to ATG is uncommon, it must be considered in the pre-operative evaluation for all transplant patients. This patient did not endorse rabbit allergies prior to this

event, but later disclosed allergy symptoms with additional prompting. As rabbits become household pets in increasing numbers, assessing patients for potential rabbit sensitization or allergies will become increasingly important in transplant candidates who may be considered for antithymocyte globulin induction.

<https://doi.org/10.32873/unmc.dc.gmerj.5.1.073>

When Your Teammate Kneeds You

Michael Hall¹, Jason Meredith¹, Ross Mathiasen²

¹Department of Family Medicine, College of Medicine, University of Nebraska Medical Center

²Department of Emergency Medicine, College of Medicine, University of Nebraska Medical Center

Mentors: Jason Meredith, Ross Mathiasen

Program: Primary Care Sports Medicine

Type: Case Report

Background: A 21-year-old male collegiate basketball athlete initially presented to the athletic training room for evaluation of left groin pain. He reported being kneed in the left thigh near the time of onset 5 days ago. He had consistent soreness since onset. Notably, he recently had surgical fixation of a Jones fracture resulting from stress injury. These new symptoms occurred during his return to play progression after surgery.

Case: Exam consisted of palpatory tenderness near the left inguinal canal and LLQ. He also experienced pain with a sit-up and straight leg. An MRI was ordered due to concern of a possible sports hernia. MRI showed a left pubic body stress fracture. A metabolic workup was pursued which demonstrated low vitamin D levels. Calcium and vitamin D were supplemented, and he stopped all pain provoking activities for 6 weeks. During his subsequent return to play progression, he developed right groin pain. Repeat pelvis MRI now showed a right pubic body stress fracture and unchanged left pubic body stress fracture. He was subsequently removed again from activity. Vitamin D and calcium

supplementation were continued during this time.

Conclusion: Fourteen weeks after the repeat MRI, he was symptom free with no tenderness to palpation. Vitamin D level was rechecked. They were adequate at 44 ng/mL. He slowly re-started his return to play progression, adding impact activities over the following 6 weeks. During this time an unremarkable gait analysis was performed. There was no return of symptoms and he has returned to full activity.

<https://doi.org/10.32873/unmc.dc.gmerj.5.1.074>

Not your TIPICal Neck Pain: Case of Transient Perivascular Inflammation of the Carotid Artery (TIPIC) Syndrome

Patricia Zick¹, Jonathan Muldermans²

¹Department of Family Medicine, College of Medicine, University of Nebraska Medical Center

²Department of Radiology, Offutt Air Force Base

Mentor: Jonathan Muldermans

Program: Family Medicine

Type: Case Report

Background: We present a case of a rare cause of neck pain called Transient Perivascular Inflammation of the Carotid artery (TIPIC) syndrome. TIPIC is an idiopathic self-resolving process identified by clinical and radiographic criteria.

Case: A 41-year-old female with history of smoking presented to clinic with acute right sided neck pain, but otherwise feeling well. Vitals were normal. On exam she had tenderness overlying the right carotid artery. CT neck revealed mild perivascular thickening around the right common carotid artery extending through the carotid bulb, without associated occlusion or high-grade

stenosis. CBC, ESR, CRP were normal. U.S. demonstrated mildly increased velocity of right carotid, without evidence of intimal thickening or plaque. These imaging findings are consistent with TIPIC syndrome. Patient's neck pain resolved over next 2 weeks. Follow-up ultrasound 6 months later demonstrated resolution of perivascular findings.

Conclusion: TIPIC is important to include in patients with acute unilateral neck pain and carotid tenderness. TIPIC was newly identified and defined in 2017 with four proposed major criteria: acute pain overlying carotid artery, perivascular inflammation on imaging, exclusion of another diagnosis, and improvement within 14 days. Mild elevations in inflammatory markers can be seen. Treatment is supportive with NSAIDs. It is self-resolving process within 14 days. It

is likely under-recognized due to its transient nature. Among various other risk factors, TIPIC has been seen in patients with tobacco use as well as recent viral illness.

<https://doi.org/10.32873/unmc.dc.gmerj.5.1.075>