



June 2024

More Than a Sore Throat; A Case of Group A Strep Meningitis

Stacie Lackner

University of Nebraska Medical Center

Tell us how you used this information in this [short survey](#).

Follow this and additional works at: <https://digitalcommons.unmc.edu/gmerj>



Part of the [Higher Education Commons](#), and the [Medicine and Health Sciences Commons](#)

Recommended Citation

Lackner, S. More Than a Sore Throat; A Case of Group A Strep Meningitis. Graduate Medical Education Research Journal. 2024 Jun 28; 6(1).

<https://digitalcommons.unmc.edu/gmerj/vol6/iss1/25>

This Conference Proceeding is brought to you for free and open access by DigitalCommons@UNMC. It has been accepted for inclusion in Graduate Medical Education Research Journal by an authorized editor of DigitalCommons@UNMC. For more information, please contact digitalcommons@unmc.edu.

More Than a Sore Throat; A Case of Group A Strep Meningitis

Abstract

NA

Creative Commons License



This work is licensed under a [Creative Commons Attribution-Noncommercial-No Derivative Works 4.0 License](https://creativecommons.org/licenses/by-nc-nd/4.0/).

#16. Suddenly Stuck: A Classic Case of Thyrotoxicosis Periodic Paralysis

Christopher Coles¹, **Kelsey Fillman¹**, Rae Witt¹

¹Department of Internal Medicine, College of Medicine, University of Nebraska Medical Center, Omaha, NE, USA

Mentor: Rae Witt

Program: Internal Medicine

Type: Case Report

Background: Thyrotoxic Periodic Paralysis is an uncommon syndrome that can present as temporary weakness or paralysis, secondary to hypokalemia predisposed by a thyrotoxic state.

Case: A 40-year-old man presented with progressively worsening, diffuse body weakness that had begun the day prior. He also noted unintended weight loss of 45 lbs over the prior 6 months, palpitations, and increased fatigue with low levels of exertion. On

presentation, he was in atrial fibrillation with rapid ventricular response. He had a diffusely enlarged thyroid that was tender to palpation. Muscle strength was 3/5 in proximal lower extremities bilaterally and 4/5 in proximal upper extremities bilaterally. Evaluation was significant for low potassium (2.3 mEq/L), undetectable thyroid stimulating hormone (TSH) (<0.01 mIU/L), and elevated Free T4 (3.5 µg/dL). Thyroid was enlarged and heterogeneous by ultrasound. Subsequent TSH receptor antibody was elevated (26 IU/L), consistent with Graves' disease. The patient was started on propylthiouracil and propranolol for the management of thyrotoxicosis, and potassium was repleted. He experienced quick resolution of his diffuse body weakness

and was stabilized for discharge with close follow-up.

Conclusion: This case represents the clinical presentation of Thyrotoxic Periodic Paralysis, a syndrome that can present as painless muscle weakness or paralysis secondary to thyrotoxicosis. Pathophysiology is suspected to be secondary to excess thyroid hormone driving the sodium-potassium pump, transporting potassium into cells, and impairing the electrical function of skeletal muscle. It can be managed by treating the underlying thyrotoxicosis while repleting potassium. Importantly, potassium needs to be repleted cautiously as patients are at risk for rebound hyperkalemia.

#17. Comparison of Injuries Sustained on Grass and Artificial Turf by USL1 Men's Soccer Team. Part 1:

Match Related Injuries

Michael Osterholt¹, Jason Meredith¹

¹Department of Family Medicine, College of Medicine, University of Nebraska Medical Center, Omaha, NE, USA

Mentor: Jason Meredith

Program: Family Medicine – Primary Care Sports Medicine

Type: Original Research

Background: Athlete health and safety on artificial turf (AT) is a topic for debate. This study aims to analyze and compare the incidence, type, and location of injuries sustained on AT and natural grass (NG) for matches of a United Soccer League, League 1 (USL1) men's soccer team.

Methods: Playing surface, player hours and injury data including anatomic location of

injury, and type of injury sustained were retrospectively reviewed for matches of three USL1 seasons (2020-2022). Injury incidence rates were reported in terms of number of injuries per 1000 player hours.

Results: Three-year cumulative match data resulted in 428 exposure hours and 69 injuries on AT versus 1085 hours and 175 injuries on NG. Overall incidence of match related injuries per 1000 player hours was 161.26 on AT compared to an identical 161.26 on NG (Incidence Ratio (IR)=1.00; P Value<1.00). Lower limb was the most common injury location on AT and NG with an incidence of 112.18 and 118.87 respectively (IR=0.94, P

Value<0.732). Muscle/tendon and contusion injuries were the most common type of injury on AT and NG. Incidence of muscle/tendon and contusion injuries on AT were 67.78 and 44.41 respectively, compared to 57.13 and 60.82 on NG (IR ratio muscle/tendon=1.16, P<0.447) (IR contusion=0.73; P<0.227).

Conclusion: There was no statistically significant difference of match related injuries sustained on AT and NG per 1000 player hours of a USL men's soccer team when comparing overall incidence, location and type of injury.

#18. Comparison of Injuries Sustained on Grass and Artificial Turf by USL1 Men's Soccer Team. Part 2:

Total Athlete Exposure

Michael Osterholt¹, Jason Meredith¹

¹Department of Family Medicine, College of Medicine, University of Nebraska Medical Center, Omaha, NE, USA

Mentor: Jason Meredith

Program: Family Medicine – Primary Care Sports Medicine

Type: Original Research

Background: Athlete safety on artificial turf (AT) is a topic for debate. This study aims to analyze and compare the incidence, type, and location of injuries sustained on AT and natural grass (NG) playing surfaces for a United Soccer League, League 1 (USL1) men's soccer team.

Methods: Playing surface, athlete exposure and injury data including anatomic location of injury, and type of injury sustained were retrospectively reviewed for three USL1 seasons (2020-2022). Injury incidence rates were reported in terms of 1000 athlete exposures. Exposure was an athlete's participation in one practice session or match.

Results: There were 3444 exposures on NG and 5550 on AT over the 3-year period. 295 injuries were registered on AT versus 259 on NG. Overall incidence of

injuries per 1000 exposures was 53.15 on AT compared to 75.20 on NG (Incidence Ratio (IR) =0.71, P Value<0.001). Subgroups for location of injury comparing incident rate on AT to NG: Head/neck (IR=0.38, P<0.002), Upper limb (IR=0.43, P<0.030), Trunk (IR=0.84, P<0.520), and Lower limb (IR=0.76, P<0.004). Subgroups for type of injury comparing incident rate on AT to NG: Fracture/Bone Stress (IR=0.47, P<0.317), Joint(non-bone)/Ligament/Cartilage (IR=1.06, P<0.771), Muscle/Tendon (IR=0.85, P<0.193), Contusion (IR=0.39, P<0.001),

Laceration/Skin Lesion (IR=1.03, P<0.936), Central/Peripheral Nervous System (IR=0.38, P<0.032), Other (IR=0.21, P<0.054).

Conclusion: Overall incidence of injuries was significantly lower on AT than NG. Injuries

subdivided into location demonstrate statistically lower rates of head/neck, upper limb, and lower limb injuries on AT. Additionally, with regards to type of injury, the rate of contusions and central/peripheral nervous system injuries were statistically lower AT.

#19. More Than a Sore Throat; A Case of Group A Strep Meningitis[§]

Stacie Lackner^{1,2}, Arthur Chang^{1,2}, Andrea Green Hines^{1,2}

¹Department of Pediatrics, College of Medicine, University of Nebraska Medical Center, Omaha, NE, USA

²Department of Pediatrics, Children's Nebraska, Omaha, NE, USA

[§]Abstract submitted but not presented

Mentors: Andrea Green Hines, Arthur Chang

Program: Pediatrics

Type: Case Report

Background: Group A Strep (e.g., *Streptococcus pyogenes*) is an aerobic gram-positive coccus that commonly causes bacterial pharyngitis and less commonly causes invasive infection of sterile sites in the body such as bacteremia, pneumonia, septic arthritis, as well as many others. Most invasive diseases are preceded by a viral infection.

Case: This case involves a 16 year old previously healthy male who was transferred from an outside hospital due to altered mental status with a reported 8 day history of vomiting and several days of sore throat. He was found to have COVID-19 and Epstein-Barr virus infections. In our ED he was noted to be febrile and disoriented with a GCS of 11; an LP was attempted but was unsuccessful. On admission to the PICU, ceftriaxone was initiated, and vancomycin was added on the following day. A sedated LP with IR and MRI were performed on hospital day #2; CSF studies were remarkable for pleocytosis of 8,000 WBCs, negative Meningitis/Encephalitis panel with a positive culture that

grew gram-positive cocci resembling Strep species. A broad range bacterial polymerase chain reaction (PCR) test of CSF sent out identified group A Strep. The patient was transitioned to penicillin. Due to complications of right lenticular striate branch middle cerebral artery infarct, the patient had a prolonged hospital stay with plans in place for inpatient rehabilitation.

Conclusion: Although majority of the time group A Strep causes minor infections, it can cause invasive disease in children with a high mortality rate and should be considered with serious infections.

#20. Hypertriglyceridemia Induced Acute Pancreatitis: A Case Report

Michael Turco¹

¹Clarkson Family Medicine, Nebraska Medicine, Omaha, NE, USA

Mentor: Dale Agner

Program: Clarkson Family Medicine

Type: Case Report

Background: Hypertriglyceridemia is the third most common cause of acute pancreatitis after alcohol and gallstones. Primary disorders are rare, with a predominance of secondary causes. A typical patient is younger, male, and likely to have a secondary cause, although pregnancy is a unique risk factor. Despite management, patients are predisposed to recurrent episodes due to underlying risk factors and challenges with therapy adherence

pancreatitis, and multiple comorbidities presented to the emergency department for concerns of severe abdominal pain, nausea, and diarrhea. Despite reported medication and dietary adherence, subsequent history revealed multiple similar episodes managed at home, with her most recent admission one year prior. Workup demonstrated triglyceride level of 3125 mg/dL, lipase of 991, and abdominal CT consistent with acute pancreatitis. Serum glucose of 19 was suggestive of serum hyperviscosity. Pain management and fluid resuscitation were initiated, and the patient transitioned to inpatient care. The patient continued statin and fibrate therapies and started cholestyramine. Insulin therapy was considered due to continued hypoglycemia, but ultimately, glucose stabilized to

low-normal levels without insulin therapy. Over four days, the patient's diet was advanced, and she was weaned off pain medications. At discharge, she required continued glucose monitoring for hypoglycemic episodes, subsequent medication adjustments due to continued hypertriglyceridemia and difficulty obtaining the recommended therapeutic agent.

Conclusion: This case is an uncommon presentation of hypertriglyceridemia-induced pancreatitis and demonstrates a successful recovery from an acute flare, and the challenges facing patients despite attempts at medical and dietary adherence.

Case: A 53-year-old female with known familial hypertriglyceridemia, recurrent

#21. Beware the Runny Nose – Could Be CSF Leak!

Rubab Ali¹, Sarah Howard¹

¹Clarkson Family Medicine, Nebraska Medicine, Omaha, NE, USA

Mentor: Sarah Howard

Program: Clarkson Family Medicine

Type: Case Report

Background: Cerebrospinal fluid (CSF) rhinorrhea is a rare condition in which cerebrospinal fluid leaks from the nasal cavity. It can be caused by trauma, surgery, congenital defects, increased intracranial pressure, or

idiopathic. Symptoms include clear/watery nasal discharge, salty/metallic taste in mouth and headache. It is a rare but serious condition that can lead to meningitis, brain herniation, or intracranial hypotension.

Case: A 46-year-old female with history of migraines, obesity and hypertension presented to PCP for left-sided rhinorrhea, headaches and nausea for several months. Patient was seen by multiple providers and conservatively managed with Zofran, nasal decongestants and cold remedies without relief. She denied any recent infections or trauma. Further questioning revealed that headache and rhinorrhea were positional and accompanied by metallic tasting PND, raising suspicion for cerebrospinal fluid rhinorrhea. CT head (**Figure 1**) was ordered showing partial empty sella and thinning/defect of the left sphenoid sinus roof. Nasal discharge tested positive for Beta-2 transferrin confirming cerebrospinal fluid leak. Patient subsequently underwent

nasoseptal flap repair via a transsphenoidal approach. Rhinorrhea resolved after surgery and symptoms improved.

Conclusion: This case highlights the importance of identifying clues in patient history leading to appropriate diagnosis. Beta2-transferrin assay is currently the single best laboratory test for identifying the presence of CSF in sinonasal fluid. Other tests may include MRI, CT, or cisternography. These tests can help to locate the source of the leak and determine the best treatment option. Conservative treatment aims to reduce intracranial pressure, while surgical treatment involves repairing the leak by using a patch, glue, graft, or flap repair.

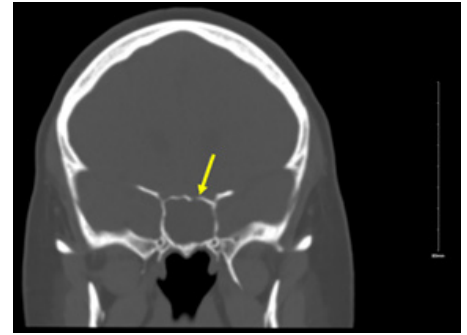


Figure 1. CT Head showing thinning/defect of Left Sphenoid Sinus Roof (arrow).

#22. Diabetes and Claudication: Reduced Pain Perception; Worse Walking Impairment and Quality of Life

Ali H. Hakim^{1,2,3}, Yuqian Tian^{1,2}, Matthew A. Fuglestad¹, Julian Kim^{1,2}, Holly K. Despiegelaere², Zhen Zhu¹, Ray Mitchell³, Iraklis I. Pipinos^{1,2,3}, Pooneh Bagher³

¹Department of Surgery, University of Nebraska Medical Center, Omaha, NE, USA

²Department of Surgery and VA Research Service, Nebraska/Western Iowa, Omaha, NE, USA

³Department of Cellular & Integrative Physiology, College of Medicine, University of Nebraska Medical Center, Omaha, NE, USA

Mentor: Pooneh Bagher

Program: General Surgery

Type: Original Research

Background: The effects of diabetes in patients with peripheral artery disease (PAD) who present with claudication is poorly defined. We hypothesized that claudicating patients with diabetes would display worse characteristics including angiographic disease distribution, physiology of oxygen delivery, walking ability, at home physical activity (HPA), and quality of life (QoL) than patients without diabetes.

Methods: We recruited claudicating PAD patients and compared diabetics (N=15, HbA1c>6.5%) to non-diabetics (N=61). We

reviewed baseline Ankle Brachial Indices (ABI), CT angiography (CTA), 6 minutes walking distance (6MWD), treadmill initial (ICD) and maximal (MCD) claudication walking distance with concurrent calf muscle oxygenation (STO2) measurements with near infrared spectroscopy, QoL questionnaires and HPA measured using pedometers.

Results: The diabetic group had higher BMI (31.1±6.8vs26.4±4.4, p<0.01), and hyperlipidemia (93%vs72%, p<0.01). There were no differences in ABI, CTA, MCD and parameters of (STO2). Diabetic patients had longer initial claudication distances (ICD) (208.2±133.7meters vs124.0±94.5, p<0.02) and shorter pain recovery times (RT) (287.4±234.8seconds vs133.9±126, p<0.005). Diabetics had shorter 6MWD

(252.3±62.3meters vs298.4±60.2, p<0.02), 50% (p<0.005) lower HPA, and worse measures of social functioning, emotional well-being, energy, and fatigue.

Conclusion: Diabetic PAD patients had unexpected longer ICDs, and shorter RTs suggesting significant alterations in the pain perception and pain pathways of the leg. They also had decreased performance on HPA and 6MWD with worse QoL measures suggesting that diabetes predisposes to worse walking outcomes and QoL in PAD. Identification and aggressive management of PAD should be given priority in diabetics as presenting symptoms may be milder despite worse outcomes and QoL.

#23. Length and Proximal Extent of Occlusion Dictates Severity of Disease in a Mini-Swine Model of Peripheral Artery Disease

Ali H. Hakim^{1,2}, Yuqian Tian^{1,2}, Al-Murtadha Al-Gahm^{1,2}, Sara Cartwright^{1,2}, Jamal Salaymeh^{1,2}, Julian Kim^{1,2}, Zhen Zhu¹, George P. Casale¹, Iraklis I. Pipinos^{1,2}, Mark A. Carlson¹

¹Department of Surgery, College of Medicine, University of Nebraska Medical Center, Omaha, NE, USA

²Department of Surgery and VA Research Service, VA Nebraska - Western Iowa, Omaha, NE, USA

Mentor: Mark Carlson

Program: General Surgery

Type: Original Research

Background: There is ongoing need for large animal models of peripheral artery disease (PAD) mimicking human disease. We present mild, moderate and severe phenotypes of PAD in an Ossabaw swine model.

Methods: After 8 weeks of a western diet, we induced right hindlimb Ischemia induction(T0) with open ligation and resection of Right Superficial Femoral Artery for mild (N=4), endovascular coil occlusion of Right External Iliac Artery, Right Superficial Femoral Artery for moderate(N=9) and coil occlusion of Right External Iliac Artery, Right Superficial Femoral Artery, and right internal iliac artery for severe(N=4). At 4 weeks (T4)

and 8 (T8), all swine underwent angiography and bilateral gastrocnemius biopsy. All swine underwent bilateral ankle brachial indices (ABI), and calf muscle tissue oximetry (STO2) measurements at T0, T4, and T8, and weekly measurement of their treadmill walking distance.

Results: At T4 and T8, there was worsening of Right ABI, Right calf STO2, and treadmill