



June 2024

Livedoid Vasculopathy-Induced Peripheral Neuropathy Treated Successfully With Aspirin, Rivaroxaban, and Pentoxifylline

Kevin Kwan

University of Nebraska Medical Center

Tell us how you used this information in this [short survey](#).

Follow this and additional works at: <https://digitalcommons.unmc.edu/gmerj>



Part of the [Higher Education Commons](#), and the [Medicine and Health Sciences Commons](#)

Recommended Citation

Kwan, K. Livedoid Vasculopathy-Induced Peripheral Neuropathy Treated Successfully With Aspirin, Rivaroxaban, and Pentoxifylline. *Graduate Medical Education Research Journal*. 2024 Jun 28; 6(1). <https://digitalcommons.unmc.edu/gmerj/vol6/iss1/83>

This Conference Proceeding is brought to you for free and open access by DigitalCommons@UNMC. It has been accepted for inclusion in *Graduate Medical Education Research Journal* by an authorized editor of DigitalCommons@UNMC. For more information, please contact digitalcommons@unmc.edu.

Livedoid Vasculopathy-Induced Peripheral Neuropathy Treated Successfully With Aspirin, Rivaroxaban, and Pentoxifylline

Abstract

NA

Creative Commons License



This work is licensed under a [Creative Commons Attribution-Noncommercial-No Derivative Works 4.0 License](https://creativecommons.org/licenses/by-nc-nd/4.0/).

#86. Hypotension and Arrhythmia Due to Cariprazine, Olanzapine and Metoprolol

Madeline Trout-Smith¹, Erin Ray¹

¹Clarkson Family Medicine, Nebraska Medicine, Omaha, NE, USA

Mentor: Sarah Howard

Program: Clarkson Family Medicine

Type: Case Report

Background: This is a case of cariprazine, olanzapine and metoprolol medication interactions leading to hypotension and arrhythmia.

Case: A 49-year-old female presented to the emergency department due to dizziness, lightheadedness, and pre-syncopal episode. Medical history included peripheral vascular disease, hypertension and bipolar disorder. Pertinent medications include cariprazine (Vraylar) 3mg and olanzapine (Zyprexa) 10mg. Metoprolol 25mg (Lopressor) twice

daily had recently been started due to frequent premature ventricular contractions (PVC) and runs of non-sustained ventricular tachycardia, seen on recent Holter monitor. On arrival, she was bradycardic and hypotensive and was initially started on a glucagon drip due to suspected beta-blocker toxicity. Telemetry showed an episode of ectopy and frequent PVCs. Intravenous fluid resuscitation was started due to hypotension. Metoprolol and lisinopril were held. The patient's cariprazine and olanzapine medication were discussed with Psychiatry and Pharmacy regarding potential interaction leading to hypotension and arrhythmia. Her cariprazine was increased to 6mg, and olanzapine was discontinued. Cardiologist believed the patient's

hypotension was due to hypovolemia, and the glucagon drip was discontinued. The patient did not need vasopressor support. Since the discontinuation of olanzapine, the patient had resolution of ectopy and PVCs.

Conclusion: Olanzapine has proarrhythmic properties that potentially could lead to PVC and ectopy. Management of patients with hypotension or arrhythmias should have thorough medication reconciliation. There is a risk of causing anticholinergic effects when utilizing two different antipsychotics. It is suspected that the use of cariprazine potentiates the effects of olanzapine, causing worsening arrhythmias in a patient established to be suffering from PVCs.

#87. Risk Factors to Consider When Working Up Shortness of Breath in the Outpatient Setting

Daniel Alekyan¹

¹Clarkson Family Medicine, Nebraska Medicine, Omaha, NE, USA

Mentor: Dale Agner

Program: Clarkson Family Medicine

Type: Case Report

Background: Shortness of breath is a common complaint in the outpatient setting. What risk factors meet threshold for Xray and further work up, if no emergent etiology present.

Case: A 38 y/o African American female with a history of asthma in childhood presented with intermittent shortness of breath and cough at night for several months. No other concerning symptoms, not on any medications. On exam, mild wheezing in bilateral lower bases. Patient was prescribed Symbicort and follow up for PFT's made. Patient later developed vision trouble, seen at ophthalmology and diagnosed with uveitis. Treated

with steroid drops which improved symptoms. They recommended obtaining chest X-ray and other work up for pulmonary sarcoidosis. Chest Xray showed bilateral hilar adenopathy (**Figure 1**). Patient referred to rheumatology, who started her on prednisone. Prednisone helped symptoms initially but had side-effects including weight gain, so treatment switched to methotrexate.

Conclusion: In a study of adults over the age 18 years, females were twice as likely to have sarcoidosis than males. The estimated lifetime risk of sarcoidosis among Black Americans is 2.4 percent, compared with an estimated lifetime risk of 0.85 percent among White Americans. Thoracic imaging is essential in the diagnosis of sarcoidosis because intrathoracic lymph node and/or lung involvement occurs in over 90 percent of patients. Spirometry pre/post bronchodilator

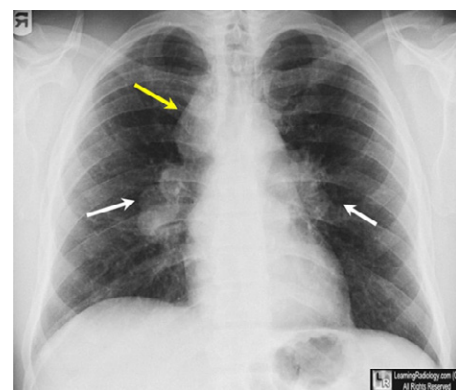


Figure 1. Shows bilateral hilar adenopathy.

may be ordered initially without full PFTs. In those over 40 with risk factors or adults with other comorbidities there is a low threshold for initial testing with H/H, BMP, chest Xray, ECG.

#89. Cholestatic Drug Induced Liver Injury From Rad-140 Successfully Treated With Corticosteroids

Bilal Niazi¹, Bill Quach¹, Thoetchai Peeraphatdit¹

¹Department of Internal Medicine, Division of Gastroenterology & Hepatology, College of Medicine, University of Nebraska Medical Center, Omaha, NE, USA

Mentor: Thoetchai Peeraphatdit

Program: Internal Medicine - Transplant Hepatology

Type: Case Report

Background: Selective Androgen Receptor Modulators (SARM) are anabolic compounds which modulate androgen activity and have

been increasingly used in supplements for enhanced performance and muscle growth. Their use has been associated with cholestatic drug induced liver injury (DILI), similar to anabolic androgens. Treatment is mainly supportive after drug cessation and can take weeks to months for normalization. We present a case of cholestatic hepatitis associated with a readily available SARM

called RAD-140 successfully managed with corticosteroids.

Case: A 42-year-old male with no past medical history presented for worsening jaundice, icterus, and pruritis over the prior 4 weeks. He had started Rad-140 8 weeks prior. He denied prescription medications, alcohol, tobacco, recreational drug use, or new supplements.

Vital signs were stable, and physical exam was remarkable for jaundice and icterus. Labs revealed: AST = 45 U/L, ALT = 80 U/L, ALP = 172 U/L, Total Bilirubin = 20.2 mg/dl, GGT = 44 U/L. Autoimmune and viral serology were unremarkable. An abdominal ultrasound demonstrated no structural biliary abnormalities. Rad-140 was discontinued. Cholestyramine and ursodiol were initiated for ongoing pruritis. However, cholestasis remained stagnant for >1 month. A liver biopsy was performed demonstrating moderate bland cholestasis. A steroid taper was initiated with Prednisone 60 mg resulting in progressive normalization of liver enzymes within 2 months, as demonstrated in **Figure 1**.

Conclusion: The SARM RAD-140 is a widely available supplement that can cause cholestatic DILI. Liver biopsy usually shows bland cholestasis. In addition to stopping RAD-140, our case demonstrates the potential use of corticosteroids to treat refractory cholestasis from RAD-140 associated cholestatic DILI.

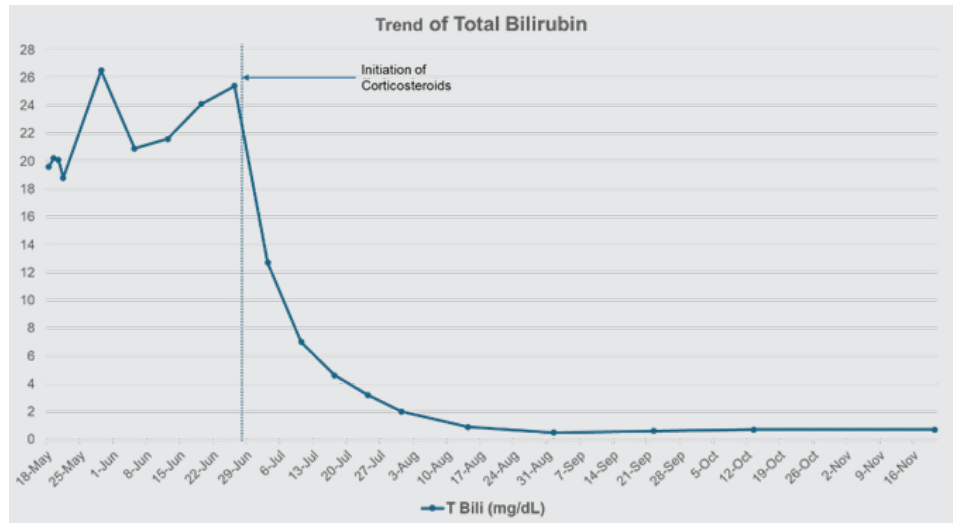


Figure 1. The trend of total bilirubin levels is described here. Total bilirubin levels remained consistently elevated despite cessation of Rad-140 for which corticosteroids were initiated, as described by the dotted line. Subsequently, his bilirubin levels consistently trended down until normalization by week 6 of steroid therapy.

#90. A Single-Center Retrospective Study to Compare Trending of Serum Lipase With Clinical Outcomes in Hospitalized Children With Acute Pancreatitis

Sandeep Puri¹, Amreen Masthan², Ruben Quiros¹

¹Department of Pediatrics, Division of Gastroenterology, College of Medicine, University of Nebraska Medical Center, Omaha, NE, USA

²Department of Pediatrics, College of Medicine, University of Nebraska Medical Center, Omaha, NE, USA

Mentor: Ruben Quiros

Program: Pediatrics – Gastroenterology

Type: Original Research

Background: The diagnostic utility of serum lipase for acute pancreatitis (AP) is established; however, no prognostic value has been demonstrated, and yet it is often trended during hospitalization. Our study primarily investigates if trending lipase is correlated to improved clinical outcomes in children.

Methods: A chart review was completed for AP admissions over a 1.5 year period at our affiliated children’s hospital (n = 61).

Data collection included initial lipase level, whether lipase was trended, type of intravenous fluid administered, type of analgesics administered, risk factors for AP, length of hospital stay, and the clinical outcome at 48, 96, and >96 hours after admission.

Results: Lipase was trended in 77% of patients. Trending did not demonstrate correlation to clinical outcome at 48, 96, and >96 hours (p = 0.35, 0.58, and 1.00, respectively). No correlation was identified with initial lipase value or analgesic type either. Lactated Ringer’s administration showed some degree of correlation with improved clinical outcomes at 48 and 96 hours with

reasonably small p-values of 0.052 and 0.029, respectively. Risk factors for AP did not demonstrate an effect on lipase trending. Finally, the median length of stay was significantly higher (4.0 days vs 2.5 days, p = 0.013) in the cohort with trended lipase.

Conclusion: There is no significant difference in clinical outcomes at 48, 96, or >96 hours with lipase trending. It is associated with increased duration of hospitalization which increases cost burden. Minimizing the unnecessary trend of serum lipase in pediatric AP hospitalizations is needed.

#92. Livedoid Vasculopathy-Induced Peripheral Neuropathy Treated Successfully With Aspirin, Rivaroxaban, and Pentoxifylline

Priscilla M. Rosa-Nieves^{1,2}, Kevin R. Kwan², Taylor Thieman¹, Megan Arthur²

¹Ponce Health Sciences University, School of Medicine, Ponce, PR, USA

²Department of Dermatology, College of Medicine, University of Nebraska Medical Center, Omaha, NE, USA

Mentor: Megan Arthur

Program: Dermatology

Type: Case Report

Background: Livedo Vasculopathy (LV) is a chronic cutaneous thrombo-occlusive disorder, presenting with purpuric patches and painful skin ulcerations due to micro-thrombosis of dermal vessels. We present an unusual case of progressive peripheral neuropathy secondary to livedo vasculopathy.

Case: A 53-year-old male patient with a history of progressive peripheral neuropathy of the lower limbs who presents to the dermatology clinic for ulcers on the feet bilaterally. Physical exam revealed widespread livedo reticularis on both legs, areas of atrophic blanche on the feet and ankles,

livedo racemosa on the lower abdomen, and lower back with mottled violaceous reticular patches plus punctate ulcerations. Skin biopsy revealed microvascular thrombi with no evidence of vasculitis. Laboratory work up was negative for hypercoagulable state. Immunofixation electrophoresis was positive for IgG kappa monoclonal protein. Neurology evaluation showed severe chronic axonal sensorimotor neuropathy on electromyography. Sural nerve biopsy was negative

for amyloid and revealed perivascular mononuclear inflammation, scarred vessels with occlusion and areas of recanalization.

The clinical and histologic findings are consistent with livedoid vasculopathy (LV). The patient noted prompt improvement of his cutaneous findings and gradual improvement of his sensorimotor axonal neuropathy, with 400mg of pentoxifylline three times a day, 325mg of aspirin daily, and 20mg of rivaroxaban daily.

Conclusion: LV is a chronic condition related to micro-thrombosis of dermal vessels, which can cause ischemia and ulcerations. In rare instances, LV can induce peripheral neuropathy with limited cases recorded in literature. Our case further supports the importance of recognizing vasculopathy, particularly LV, as a cause for peripheral neuropathy.

#94. Widespread Primary Nodular Cutaneous Amyloidosis Due to Local Plasmacytomas

Mitchell A. Taylor^{1*}, Trevor Lockard^{1,2*}, **Robert Borucki¹**, Erin X. Wei¹

¹Department of Dermatology, College of Medicine, University of Nebraska Medical Center; Omaha, NE, USA

²College of Medicine, University of Nebraska Medical Center; Omaha, NE, USA

*contributed equally

Mentor: Erin X. Wei

Program: Dermatology

Type: Case Report

Background: Primary nodular cutaneous amyloidosis (PNCA) is a rare manifestation of amyloid deposition, presenting as waxy, yellow-to-brown nodules or plaques that can be asymptomatic, painful, pruritic, and can compress surrounding structures. A diagnosis of PCNA requires careful evaluation to rule out plasma cell dyscrasias and rheumatologic conditions.

Case: A 74-year-old female presented to the clinic with >10 firm, well-defined subcutaneous “cysts” on her head and neck

for the past three years. An excisional skin biopsy revealed depositions of eosinophilic extracellular material with apple-green birefringence on Congo red stain, consistent with a diagnosis of nodular cutaneous amyloidosis. Differential diagnoses included primary nodular cutaneous amyloidosis (PNCA), primary systemic amyloidosis due to plasma cell dyscrasia, or systemic amyloidosis due to chronic inflammation or infection. Laboratory workup revealed slightly elevated IgG lambda at 1.65, ANA titer of 1:320, positive dsDNA, kappa > lambda free light chain elevations, and mass spectroscopy typed lambda AL amyloidosis. Bone marrow biopsy with immunophenotypic staining was nonrevealing, and no abnormal cells were seen on the peripheral smear to suggest dyscrasia.

Positron emission tomography-computed tomography demonstrated diffuse lymphadenopathy of the head and neck, and excisional biopsy of cervical lymph nodes demonstrated few deposits of lambda-restricted plasma cells surrounded by diffuse amyloid deposition. A diagnosis of PNCA with local plasmacytomas was made, and the patient is scheduled to begin daratumumab therapy and intralesional triamcinolone for symptomatic lesions.

Conclusion: PCNA is a rare disease that can present with elusive and nonspecific findings. The potential link to systemic amyloidosis underscores the importance of thorough evaluation in cases of cutaneous involvement.

#95. The Optimized Parameters of Red Blood Cell Exchange by Apheresis in Transfusion-Dependent Thalassemia, a Small Case Series

Kristina Sevcik¹, Claire Jackson², Shelly Williams¹, Scott Koepsell¹, Aleh Bobr¹

¹Department of Pathology, Microbiology & Immunology, College of Medicine, University of Nebraska Medical Center, Omaha, NE, USA

²Department of Pediatrics, College of Medicine, University of Nebraska Medical Center, Omaha, NE, USA

Mentor: Aleh Bobr

Program: Pathology

Type: Case Report

Background: Thalassemias are red blood cell disorders characterized by defects in globin chains, resulting in a microcytic hypochromic anemia. Severe variants require red blood cell transfusions as frequently as every 2-4 weeks. Since the body has no mechanism to intentionally eliminate iron, these patients also require chelation yet may still experience hemochromatosis. As an alternative, several centers have used red blood cell exchange (RBCX) in place of simple transfusions with various success. However, exchange parameters have yet to be defined

for transfusion-dependent thalassemia (TDT), unlike for sickle cell disease (SCD).

Cases: We had 5 patients with TDT who underwent RBCX with the primary goals to stabilize iron overload and increase transfusion intervals while satisfying the Thalassemia International Federation goal hemoglobin of 9.5 g/dL. The RBCX parameters used are in

Table 1. Overall, RBCX was well tolerated with only infrequent hypotension, citrate side effects, access issues, and rare vasovagal reactions potentially associated with elevated hematocrits. The adjusted RBCX goals allowed for an increase from an average interval of 3 weeks between transfusions to 5 weeks between RBCX. Despite an increase in

Table 1. RBCX Parameters for TDT vs. SCD

Parameter	TDT RBCX	SCD RBCX
Transfusion Interval (weeks)	5	4-7
Pre-Transfusion Hematocrit	29 (Hb 9.5 g/dL or higher)	25-27
Post-Transfusion Hematocrit Target	37-38	30 in acute patients; 32-34 in chronic exchanges
Isovolemic Hemodilution	Commonly omitted to keep FCR at 30	Performed, if pre-transfusion hematocrit allows
Fraction of Cells Remaining (FCR)	30	30