

1946

## Cerebral sinus thrombosis : pathogenesis and clinical diagnosis

John Fred Laws  
*University of Nebraska Medical Center*

This manuscript is historical in nature and may not reflect current medical research and practice. Search [PubMed](#) for current research.

Follow this and additional works at: <https://digitalcommons.unmc.edu/mdtheses>

---

### Recommended Citation

Laws, John Fred, "Cerebral sinus thrombosis : pathogenesis and clinical diagnosis" (1946). *MD Theses*. 1400.

<https://digitalcommons.unmc.edu/mdtheses/1400>

This Thesis is brought to you for free and open access by the Special Collections at DigitalCommons@UNMC. It has been accepted for inclusion in MD Theses by an authorized administrator of DigitalCommons@UNMC. For more information, please contact [digitalcommons@unmc.edu](mailto:digitalcommons@unmc.edu).

C E R E B R A L   S I N U S   T H R O M B O S I S

P A T H O G E N E S I S   A N D   C L I N I C A L   D I A G N O S I S

By

J o h n   F .   L a w s

Presented to the University of Nebraska  
College of Medicine January 28th, 1946.

## T A B L E O F C O N T E N T S

INTRODUCTION.....	Page 1
ANATOMY.....	Page 3
PATHOLOGY AND PATHOGENESIS.....	Page 16
PATHOGENESIS OF INDIVIDUAL LESIONS.....	Page 19
Lateral Sinus Thrombosis.....	Page 19
Cavernous Sinus Thrombosis.....	Page 21
Petrosal Sinus Thrombosis.....	Page 23
Superior Longitudinal Thrombosis.....	Page 24
SYMPTOMATOLOGY.....	Page 25
General Symptoms.....	Page 26
Local Symptoms.....	Page 30
Symptoms of Complications.....	Page 40
DIAGNOSIS OF SINUS THROMBOSIS.....	Page 44
Superior Longitudinal Sinus.....	Page 45
Lateral Sinus.....	Page 47
Cavernous Sinus.....	Page 51
Petrosal Sinuses.....	Page 54
CONCLUSIONS.....	Page 55
BIBLIOGRAPHY.....	Page 57
ILLUSTRATIONS AND TABLES:	
Diagram of the cerebral sinuses and their venous anastomoses.....	Page 15
Table showing relative frequency of routes of infections of the cavernous sinus.....	Page 22

Processes leading to thrombosis of the cerebral venous sinuses differ somewhat from those leading to arterial occlusion. These processes may occur at some place distant from the venous sinus that is ultimately to be attacked, and their symptoms may mark any symptoms which arise as a direct result of sinus occlusion. Thus the clinical pictures or syndromes of cerebral venous sinus occlusion are not so clear cut as those resulting from arterial occlusion. Furthermore, the cerebral veins are in such free communication with sinuses which carry their blood into channels outside the skull in the scalp, face, and neck that thrombosis may be a sequel to a disease process either outside of the skull or inside of it.

The picture may be further clouded by the fact that complications arising from sinus thrombosis may occur at rather distant places to the original thrombosis. This is due to the peculiar anatomy of the cerebral veins and the cerebral sinus system, including their intricate and complex connections. The cerebral veins and sinuses are thin-walled structures which have no muscular coat and no valves within their lumina, thus allowing the direction of blood flow to change rather easily. This fact, under proper

conditions, allows for the rather easy spread of a thrombotic process through the cerebral venous channels and, since the subarachnoid and subdural spaces are both traversed by the system, they are rather freely exposed to the thrombotic process and its sequelae.

It is the above-mentioned facts and others yet to be discussed which makes the diagnosis of cerebral sinus thrombosis at the same time both interesting and difficult.

The report of Abercrombie is the first record of cerebral sinus thrombosis I have been able to find. In his volume of diseases of the brain, Case 5, (young woman age 16) he presents the symptoms and pathological appearances of a case of thrombosis of the lateral sinus observed by him August 3rd, 1816.

Bouchut (quoted in Macewen) in 1845 called attention to the effect of marasmus in influencing the coagulation of the blood.

A most comprehensive paper on sinus thrombosis written by Von Dusch was translated into English in 1861. In it he reports and comments on many cases from the German literature.

In 1893 William Macewen's book, Pyogenic

Infective Diseases of the Brain and Spinal Cord, was published. In it he discusses the surgical anatomy of the temporal bone and its relations, brain abscess, and infectious thrombosis of the intracranial sinuses.

In later years the literature has grown with reports of cerebral sinus thrombosis. The condition has assumed more importance as a result of new developments in treatment, and more active and sustained observations have resulted from the stimulus that, with early and accurate diagnosis, help may be had for hitherto hopeless cases.

#### ANATOMY

The venous sinuses are usually described as being divided into upper and lower sets (Wilson 1940).

The upper set is composed of:

- (1) The superior longitudinal sinus
- (2) The inferior longitudinal sinus, and
- (3) The straight sinus.

The lower set is composed of:

- (1) The paired transverse
- (2) The cavernous, and
- (3) The petrosals.

The superior longitudinal sinus is the longest of the cerebral sinuses. It begins near the crista galli and passes backward in the superior margin of the falx

cerebri. It gradually increases in size, from before backward, until it ends at the torcular Herophili, being continuous in about 50 percent of the cases, with the right lateral transverse sinus (Macewen 1893, Wilson 1940, Nielsen and Courville 1937). The sinus communicates with the veins of the nasal cavity via a vein which enters the superior longitudinal sinus through the foramen cecum. Into this sinus drain the superior cerebral veins, the veins of the diploe and dura. The sinus also communicates with the veins of the scalp and pericranium by way of the parietal emissary vein (Wilson 1940).

This sinus is triangular in shape and its walls form a rigid, non-elastic tube (Macewen 1893). The lumen contains numerous trabeculae which divide it up and which also act to slow the blood current (Gowers 1898). Bell, quoted by Harris in 1942, states that in some instances the sinus may be square, its lower surface serving as a roof for a triangular sinus running parallel to and beneath the great sinus, also in the lamina of the falx.

At intervals, on either side of the sinus there are lacunae or "blood lakes", which are in the layers of the dura mater and communicate with the superior

longitudinal sinus through small openings. Into these "blood lakes" extend projections of the arachnoid membrane, the arachnoid villi, which serve as an outlet for the cerebrospinal fluid from the subarachnoid space (Wilson 1940).

In passing it should be pointed out that there are some anatomical factors which tend to slow the blood stream in the sinus and promote thrombus formation (Gowers 1898, Wilson 1940, and Macewen 1893). They are: (1) The trabeculae in the lumen of the sinus which, as already mentioned, must act to slow the blood stream; (2) The fact that the superior cerebral veins enter the sinus at an angle and against the blood stream; (3) That the superior cerebral veins are ascending veins and drain blood from areas supplied by ascending arteries, thus working against a hydrostatic pressure; and (4) That in the erect position the anterior portion of the sinus ascends against the pull of gravity.

In considering the above facts Gowers states: "The marvel is that thrombosis is not more common than it is."

The inferior longitudinal sinus is a somewhat sickle-shaped, circular venous channel which occupies



the concave, free border of the falx. It ends posteriorly by joining the straight sinus near the front edge of the tentorium (Wilson 1940). It receives blood mainly from the falx.

The straight sinus is formed by the junction of the inferior longitudinal sinus and the Great Vein of Galen. It passes back on the tentorium in the attachment of the falx to end, for the most part, in the left lateral sinus. A small branch usually connects it with the torcular (Wilson 1940).

The vein of Galen is formed by the union of the two internal cerebral veins. These latter veins are formed on each side at the medial side of the anterior tubercle of the thalamus from the union of the coronal veins and the thalamostriate vein. Thus the vein of Galen and the straight sinus receive the blood from the interior of the brain.

The superior petrosal sinuses are paired sinuses lying on the upper margin of the petrous portion of the temporal bone (Vail 1922). They are connected with and receive blood from the cavernous sinus on each side and carry the blood into the lateral sinus, joining it at the junction of the transverse and sigmoid portions (Macewen 1893). According to Wilson it

receives some of the inferior cerebral veins, the superior cerebellar veins, and some small veins from the tympanum through the petrosquamous fissure.

The inferior petrosal sinuses are also paired sinuses. They come from the posterior part of the cavernous sinus, travel down along the junction of the occipital bone with the petrous portion of the temporal, and, after passing through the anterior part of the jugular foramen, along with the meningeal branch of the ascending pharyngeal artery, end in the jugular bulb on each side (Vail 1922). They receive some of the inferior cerebellar veins and also some veins from the internal ear.

The inferior petrosal has a very close relation to the abducens nerve in the vicinity of Dorello's canal. This canal is formed by a spine of bone which arises from the end of the superior margin of the petrous bone where the groove for the superior petrosal sinus ends. This spine extends forward and inward toward the accessory clinoid process of the sphenoid bone with which at times it may be joined. Beneath this arch, completed by a fold of the dura, pass the inferior petrosal sinus, the abducens nerve, and a minute artery. A thrombus or an inflammatory affection of the inferior

petrosal sinus in the region may readily affect the trunk of the nerve directly by inflammation or by compression from the attending inflammatory swelling (Vail 1922).

The two cavernous sinuses lie between layers of the dura on the lateral side of the body of the sphenoid bone. (Turner and Reynolds 1931). Each sinus commences anteriorly at the inferior and medial end of the superior orbital fissure where it receives the superior ophthalmic vein; it terminates posteriorly in the superior and inferior petrosal of the temporal bone (Turner and Reynolds 1931). The inner wall of each sinus is lined with endothelium which is continuous with that of the veins entering and leaving it (Turner and Reynolds 1931). The lumen of each sinus is traversed by fibrous threads which divide it into compartments (Wilson 1940) and produce a reticulated arrangement. Through these meshes the flow of blood is somewhat reduced (Turner and Reynolds 1931). In this respect it is somewhat similar to the superior longitudinal but differs from the rest of the cerebral venous sinuses.

In the dura forming the outer wall of the sinus are the oculomotor, trochlear, and the ophthalmic and maxillary divisions of the trigeminal nerve. The

abducens nerve and the internal carotid artery occupy a somewhat more medial position in the sinus, but are separated from the blood stream by the endothelial lining (Turner and Reynolds 1931).

The vessels carrying blood to and from the cavernous sinus may be visualized and understood somewhat better by following the plan of Turner and Reynolds.

A. Afferent Vessels of the Cavernous Sinus

1. Intracranial Tributaries (Afferent)

a. Spheno-parietal Sinus - lying in the dura on the under surface of the lesser wing of the sphenoid. It terminates in the anterior part of the cavernous sinus, and through it the sinus receives blood from the diploë of the sphenoid wing and the dura mater. It also has a communication with the middle meningeal veins.

b. Superficial Inferior Cerebral Veins - These veins in the anterior cranial fossa carry blood from the inferior surface of the frontal lobe. The superficial middle cerebral vein travels down the Sylvian fissure and empties into the cavernous sinus. This vein is often connected to the superior

longitudinal sinus by way of the anastomatic vein of Trolard and to the lateral sinus by the inferior anastomatic vein.

2. The Extracranial Tributaries (Afferent)

a. The Ophthalmic Veins - Superior and Inferior

- These veins are formed from the veins of the orbit. The superior has connections with the supraorbital and the angular veins, thus linking the ophthalmic venous system with the circulation on the forehead, the external nose, the tear sac, the cheek, and the upper and lower lids. The inferior ophthalmic veins send a branch to the pterygoid plexus through the inferior orbital fissure and at times this is the principal connection of this vein. Ordinarily, these veins may be considered as tributaries of the cavernous sinus, as they are devoid of valves and blood can flow either way in them (Turner and Reynolds 1931).

b. Veins From the Sphenoid Air Cavity - These veins enter the cavernous sinus directly on its medial and inferior aspect (Turner and Reynolds 1931).

B. Efferent Veins of the Cavernous Sinus.

1. The Vein of Vesalius. This vein goes from the posterior inferior part of the cavernous sinus through the foramen of Vesalius to the pterygoid plexus.
2. Veins of the Foramena Ovale and Lacertum. These veins connect the cavernous sinus with the pterygoid plexus.
3. The Carotid Venous Plexus. This plexus of veins surrounds the carotid arteries and has many openings into the cavernous sinus. This plexus commonly ends in the internal jugular vein. In their passage through the carotid canal this plexus receives several branches from the lining of the tympanic cavity. Through this connection it would be possible for the cavernous sinus to become involved from the ear without affecting the petrosal sinuses (Turner and Reynolds 1931).
4. The Superior and Inferior Petrosal Sinuses. These have already been described.

The lateral sinuses are the last group of paired sinuses and are the main efferent vessels draining venous blood from the brain and cranial cavity.

Each sinus may be described as consisting of two parts (Nielsen and Courville 1937). The horizontal part, coming from the torcular Herophili, makes a groove on the inner surface of the occipital bone. This part of the sinus makes a slight convexity upward in its path. The sigmoid portion begins on the mastoid portion of the temporal bone where the lateral part turns downward. This portion travels down a ways and then makes a slight curve forward and upward to the jugular foramen where it enters the internal jugular vein (Wilson 1940). The descending part of the sinus lies in close relation to the mastoid air cells throughout its course, separated from the cells only by the thin sinus plate (Nielsen and Courville 1937). It is at this point that the sinus is most often attacked by infections from the antrum or middle ear (Macewen 1893).

The lateral sinuses receive blood from: (1) the posterior part of the cerebrum; (2) the cerebellum and diploe; (3) the occipital sinus, usually paired (Wilson 1940) running from the torcular Herophili around the jugular foramen and entering the lateral sinus just before the latter joins the jugular bulb.

By way of the inferior anastomatic vein,

connection is made with the superficial cerebral vein and its afferents. Through this route the entire dorsolateral half of the cerebral hemisphere is exposed to infection by retrograde extension once the lateral sinus is infected. The cerebral and cerebellar veins which empty into these rigid sinuses are thin-walled and without a muscular coat or valves (Nielsen and Courville 1937). In reaching the lateral sinuses they must traverse the subarachnoid and subdural spaces, exposing these to infection after the sinus has become thrombosed (Nielsen and Courville 1937).

Another connection which the lateral sinus makes is with the occipital or posterior auricular by way of the mastoid emissary vein. The mastoid vein may also empty directly into the internal or external jugular vein (Ziegelman 1933). The mastoid emissary vein at times may carry the main volume of blood from the lateral sinus. This occurs in cases where there is a small, contracted jugular foramen with a small internal jugular vein (Furstenberg 1930). The mastoid vein may be the seat directly of septic thrombosis resulting from infected mastoid cells. Such a case is reported by Friedman and Greenfield.



Variations of the lateral sinus have been reported and a knowledge of their existence should be kept in mind in analyzing symptoms presented in each individual case of sinus thrombosis:

- (1) The lateral sinus may be duplicated and sometimes the two channels are separated by a bony ridge (Waltner 1944).
- (2) The transverse portion of the sinus may at times be absent, the sigmoid portion taking origin from an enlarged superior petrosal sinus (Furstenberg 1930).
- (3) The lower portion of the sigmoid sinus may be absent, the latter structure ending in a blind pouch and having no connection with the internal jugular vein (Furstenberg 1930).
- (4) A small transverse sinus leaving the interior of the skull through the mastoid foramen has been reported (Waltner 1944) and a normal lateral sinus leaving the skull through an enlarged mastoid foramen also is reported in the same article.

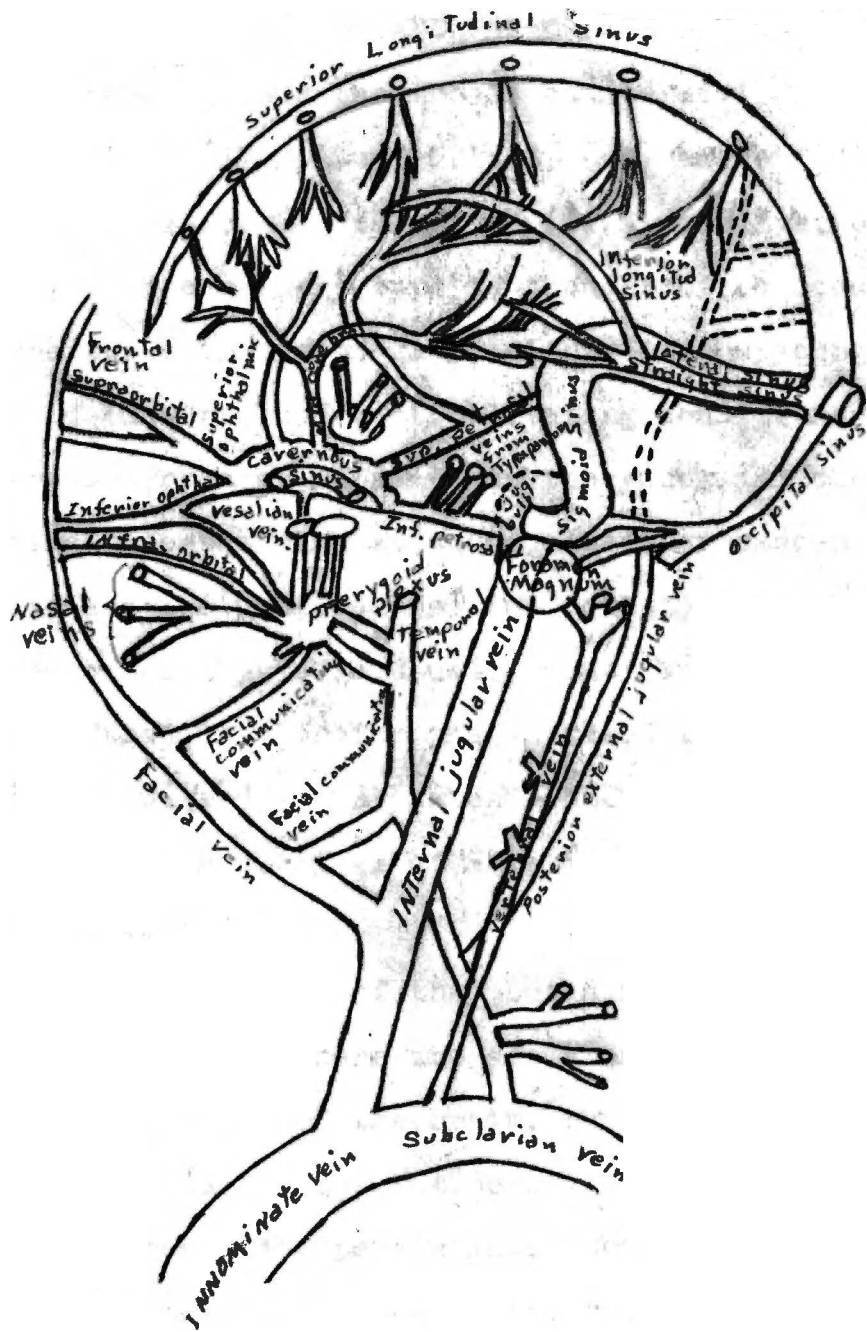


Diagram: The Cerebral Venous Sinuses, Showing Their Intra- and Extra-Cranial Connections.

### PATHOLOGY AND PATHOGENESIS

Cerebral sinus thrombosis can be divided into two types (Wilson 1940, Gowers 1898, and Macewen 1893); (1) marasmic or "primary" and (2) infective, or "secondary". The primary type is thought of as occurring at the two extremes of life, either in the young or the old (Gowers 1898). Debilitating conditions such as severe diarrhea or marasmus in the young and chronic wasting diseases such as tuberculosis or cancer in adults are the usual causes for this type of thrombosis. Marasmic thrombosis is usually considered to have a special predilection for the unpaired sinus (Gowers 1898). However, it may extend into the paired sinuses, and when it does, it is of more serious consequences (Macewen 1893).

While this type of thrombosis remains in the lumen of the sinus, there are edema and congestion of the surrounding areas of the brain, but hemorrhage and softening usually does not occur, due to adequate collateral circulation persisting. However, if the thrombus extends into one of the tributary veins of the sinus, collateral circulation from the area drained by that vein is far more greatly hampered; the capillaries break down under the pressure; and

minute hemorrhages occur scattered throughout the brain substance, especially in the gray matter (Macewen 1893).

In the primary type of thrombus the clots are dense, resistant, stratified, and non-adherent to the walls of the vein. They seldom occupy the entire lumen and tend to become organized (Gowers 1898).

The secondary or infective type of thrombus affects more often the paired sinuses and takes origin from some purulent foci of infection, usually the middle ear or mastoid (Wilson 1940). This type of thrombus occurs chiefly in adults, and is often associated in its later stages with meningitis, cerebral or cerebellar abscess (Macewen 1893).

Infective thrombosis may occur from trauma which introduces infective inflammation, or from infective scalp wounds without fracture or trauma (Gowers 1898). Erysipelas anywhere about the face or scalp, cellulitis of the orbital cavity, ulceration in the nose or pharynx, or tonsillitis may all be a cause (Macewen 1893).

The infective thrombosis may be derived from local disease in one of two ways (Macewen 1893).

The inflammatory action and infection may extend

by way of contiguous tissue from the local focus to the sinus, attacking the walls first and the interior secondly, or a small tributary vein in the diseased area may first become thrombosed, this thrombosis extending secondarily into the sinus (Macewen 1893). These two ways are designated extravenous and intravenous. (Coates, Ersner, and Persky 1934).

When the infective process attacks the sinus its walls become soft and thickened, and its endothelium desquamated (Macewen 1893). A thrombus originates at this spot and extends into the lumen of the vessel. Fibrin and blood cells tend to collect and increase the size of the thrombus until it obliterates the entire lumen of the sinus. A plastic exudate is thrown out into the surrounding tissues and if this could be organized strength would be added to the weakened sinus wall. However, degeneration tends to occur in the thrombus due to the infective process and the same occurs in the plastic exudate (Macewen 1893).

The infective type of thrombosis results, therefore, in a thrombus which is adherent to the damaged wall of the sinus, tends toward degeneration, and may result in meningitis or brain abscess.

PATHOGENESIS OF INDIVIDUAL SINUS LESIONS

I. Lateral Sinus Thrombosis.

Thrombosis of this sinus occurs more frequently than that of any other sinus and is most frequently of the infective type (Macewen (1893)). By far the most common source of infection of the sinus is local purulent disease of the ear (Wilson 1940). The close anatomical relationship of the sigmoid portion of the lateral sinus and the middle ear, mastoid antrum, and cells explains this. Both the extravenuous and intravenous method of thrombus formation described above may occur in thrombosis of this sinus, although the most common pathway of extension is by continuity of tissue (Furstenberg 1930). In mastoid disease, when the cells undergo dissolution, the sinus plate, which is quite thin (Macewen 1893), is destroyed with the direct exposure of the sigmoid portion of the sinus and the formation of a perisinus abscess. From this lesion there follows injury to the sinus wall and the pathological changes responsible for thrombus formation (Furstenberg 1930). Kopetzky believes that pressure on the sinus, once the inner table of bone is eroded, may cause slowing of the blood stream and the formation of a sterile thrombus. With the occur-

rence of an acute infection superimposed upon the chronic, the thrombus may become infected. However, the presence and extent of the previously formed sterile clot prevent the immediate spread of infection into the systemic circulation.

The small veins of the diploe may become the seat of a septic thrombus, which by antegrade extension may involve the sigmoid sinus.

Another method by which the sinus may become thrombosed is by the formation of a septic exudate in the potential space between the dura and this sinus plate. This spread of infection occurs through the pathway of the efferent diploic veins. Such an exudate may remain beneath the osseous sigmoid for days or weeks without destroying it (Furstenburg 1930) but at the same time causing thrombosis. Thus a perplexing problem may be presented to the surgeon at operation, who, suspecting sinus thrombosis, observes the normal sigmoid plate.

A thrombus may advance into the lateral sinus from the internal jugular vein via the jugular bulb, the phlebitic process originating in the internal jugular from some local inflammatory process (Wilson 1940). Though unusual, it is therefore not absolutely

necessary to have osseous erosion in order to have sinus thrombosis.

## II. The Cavernous Sinus

This sinus is usually affected by the infective type of thrombus and almost never by the marasmic type (Macewen 1893). The routes of infection of the sinus are conveniently divided into three main classes (Eagleton 1926, Turner and Reynolds 1931): (1) The anterior - from the lip, eyelid, nasal orifice, tear sac, frontal air cavity, teeth, or the anterior part of the mouth; (2) The middle - sometimes designated the anterior inferior - from the throat, the sphenoidal air cavity, or from the pterygoid plexus as it ascends in the pterygoid fossa with its numerous anastomoses from the pharyngeal plexus, through the foramen ovale, the deep facial and inferior ophthalmic veins. These infections usually originate from foci in the posterior teeth, the jaw, or maxillary antrum, and less frequently in the pharynx or tonsil (Eagleton 1926). When the thrombosis originates from the tonsil, the path of invasion is generally indirect, involving first the internal jugular and going from there, by retrograde extension, through the inferior petrosal sinus to reach the cavernous sinus (Irish 1943); (3) The posterior -



from the middle ear. The infection in this case enters the posterior portion of the sinus from thrombosis of the inferior petrosal sinus, or from caries of the deep cells at the apex of the petrous portion of the temporal bone (Irish 1943). Eagleton states that a microscopic pathway occurs in the direct infection into the cavernous sinus from the carotid venous plexus. Here a jugular bulb infection from either the ear or throat extends through the internal carotid canal in the skull and thus reaches the anterior portion of the cavernous sinus.

An idea of the relative frequency with which each route is used may be gained from the following table comparing cases presented by Turner and Reynolds, and Eagleton:

Author	Number Of Cases	Anterior	Middle	Posterior
Turner & Reynolds	21	6	10	5
Eagleton	24	13	7	4

Of the ten cases reported by Turner and Reynolds as developing by way of the middle route, nine were from the sphenoidal air cavity and one from the thrombosis (peritonsillar abscess).

### III. The Petrosal Sinuses.

The superior petrosal sinus is rarely occluded alone (Wilson 1940). However, there are a number of pathways of infecting the superior petrosal sinus (Foster 1932). Some of them are: (1) By means of veins emptying into the superior petrosal sinus from the middle ear and antrum, passing through the petrosquamous fissure; (2) Extension, by retrograde infection of a thrombophlebitis from the lateral sinus; (3) By contiguity to caries of the deep mastoid cells or the cells of the petrous pyramid; and (4) By extension posteriorly from the cavernous sinus. According to Wilson, thrombosis of the superior petrosal sinus may be expected to spread back to the lateral sinus or forward to the cavernous sinus.

Thrombosis of the inferior petrosal sinus is more frequent (Wilson 1940, Turner and Reynolds 1931) and results from (1) infections of the labyrinth, having direct venous connections with this structure; (2) infections of the petrous portion of the temporal bone; and (3) extension of a thrombus posteriorly from the cavernous sinus or extension anteriorly from the lateral sinus. Turner and Reynolds reported that the inferior petrosal sinus was involved more

frequently than the superior, secondary to cavernous sinus involvement.

#### IV. The Superior Longitudinal Sinus.

As already stated above, the usual type of thrombosis affecting the sinus is the marasmic type, although the position of this sinus exposes it to occlusion from direct injury as well (Wilson 1940). Upon referring to the previously described connections of the superior longitudinal sinus, it will be noted that infections of the scalp in the parietal or occipital region may extend into this sinus through the emissary veins and nasal infections may extend into it from the nasal cavity by way of the connecting vein through the foramen cecum. Occlusion usually begins in the middle third or fifth (Wilson 1940) and it may extend into the cerebral veins. It may also extend backward into the lateral and straight sinuses, or to the cavernous sinus by the anastomatic vein of Trolard.

Hirsch in 1938 stated that the effects of thrombosis of a dural sinus are due to the lesions in the brain caused by the coincident thrombosis of the tributary cerebral veins. According to Ehlers and Courville (1939), the initial lesion in the brain is

hyperemia. Edema, hemorrhage, and softening of the brain tissues follow rapidly.

Hirsch (1938) mentions two views advanced as to the pathogenesis of a thrombus forming in the superior longitudinal sinus: (1) Here small hemorrhages of the brain and pia are considered to be the initial lesions. Because of these, thrombosis of the pial veins develops, spreading into the dural sinus; and (2) This second view on the pathogenesis of superior longitudinal sinus thrombosis considers the thrombosis to be the initial lesion.

Vorpahl (cited by Hirsch 1938) believes that the small septa and cords extending into the lumen of the sinus and also the pacchionian corpuscles, which reach far into the lumen, impede the circulation and cause eddies in the circulating blood, thus favoring thrombus formation.

#### SYMPTOMATOLOGY

Symptomatology in cerebral disease may be conveniently divided into general and local symptoms. However, in cerebral sinus thrombosis it may be wise to point out that these symptoms are likely to be marked by symptoms of the initial disorder and/or

symptoms arising from complications of the sinus thrombosis. Therefore, in considering a suspected case of cerebral sinus thrombosis it is well to have firmly in mind the symptoms resulting from the thrombosis and separate them from the symptoms of the initial disorder and the subsequent complications. A discussion of the symptoms of the former (sinusitis, orbital cellulitis, mastoiditis, etc.) is beyond the scope of this paper. Brief mention will be made of the symptomatology of the latter.

#### General Symptoms of Sinus Thrombosis

Headache is common to practically every case of sinus thrombosis and is one of the earliest symptoms (Macewen 1893). In the cases of cerebral sinus thrombosis - all types - that I have looked up and compared pain about the head was present in all but three. These were cases of superior longitudinal sinus thrombosis in which the patients were unconscious from almost the onset. The pain is usually unilateral and is often referred by the patient to the primary seat of the disease (Tobey 1927, Macewen 1893).

Giddiness, vomiting, and nausea are frequently present and are classed under the heading of general

cerebral symptoms by Coates, Ersner, and Persky (1934).

Convulsions, varying from twitchings of isolated groups of muscles (Macewen 1893) to those of Jacksonian type may occur (Irish 1938). These do not necessarily indicate a localized lesion and are apparently due to passive congestion of the cerebral cortex as discussed in the excellent report of Nielsen and Courville (1937).

Some sort of mental change often enters into the clinical picture. The change may merely be one of lack of interest in surroundings (Souper 1933) or stupor and definite mental confusion (Lillie 1930, Alden 1929) may develop. The change may be one of the personality (McDougall 1938) and, according to Nielsen and Courville, may extend in severity to a frank psychosis. Swift (1927) is in disagreement with the above and states in his differential diagnosis that the mentality is normal in sinus thrombosis. Macewen says that in infective sinus thrombosis the "intelligence" may be acute until quite late.

External signs of sinus thrombosis occur and naturally vary with the sinus involved. Edema, swelling of soft parts, ecchymosis, and prominence of the superficial veins constitute the important signs which

may be seen and palpated.

Added to the above general symptoms of sinus thrombosis should be those symptoms and signs which are present in the infective variety. These are:

(1) Rises in temperature. This is usually reported as being high, of sudden onset, and remittant in character (Swift 1927, Woodward 1930, Muecke 1920, Ersner and Meyers 1936, McDougall 1938, Potts 1932). It is said by some authors (Macewen 1893, Woodward 1930, Ersner and Meyers 1936) to be the most characteristic symptom, but cases have been reported in which there was little or no temperature (Souper 1933 Woodward 1930). (2) Chills or rigors. The objective and subjective description of this symptom may vary from that of coldness in the extremities and a feeling of chilliness to that of actual rigors with profound prostration and even cyanosis (Ersner and Meyers 1936). Ersner and Meyers state that rigors occur when the bacteria or their toxins are thrown into the blood stream and Tobey (1927) agrees with this by stating that rigors are unusual in the early stages of infective thrombosis before bacterial invasion of the sinus has occurred. (3) Increase in pulse rate and sweats. These indicate the presence

of infection (Wilson 1940). The pulse rate, high at the onset, tends to decrease with the development of increased intracranial pressure, and after this has occurred, later in the disease process, the temperature and pulse findings are quite similar to those of brain abscess (Lillie 1930). The pulse rate may also be slowed as a result of the development of meningitis (Ersner and Myers 1936). (4) Blood picture. To the presence of infection in the body, the blood forming organs will, of course, respond. In infective thrombosis a progressive reduction in the hemoglobin and red blood cells indicates a hemolytic infection and a depression of the hematopoietic system (Ersner and Myers 1936). Tobey (1927) believes that the white cell count is seldom above 12,000 to 15,000, and Woodward (1930) states that the average is 13,000. Swift (1927), however, reports the count as most often being between 15,000 and 25,000. Stauffer (1928) states that the leukocyte count is high, although he gives no figures. McDougall (1938) says that a decreasing red cell count and hemoglobin with increasing white cells, ranging from 15,000 to 22,000, and a Schilling hemogram shifting to the right, usually indicates the presence of a hemolytic streptococcus.



Concerning blood cultures, there is disagreement as to their value. Woodward (1930) states that the majority are negative and should be disregarded, while McDougall (1938) says that cultures should be taken each day. Ersner and Myers (1936) state that they are of value only if they are positive, but Rosenwasser (1928) says, in considering the differential diagnosis between infective lateral sinus thrombosis and acute bacterial endocarditis, that if blood cultures give negative results and symptoms persist, acute endocarditis can be excluded as a consideration.

#### Local Symptoms of Sinus Thrombosis

The Superior Longitudinal Sinus. As early as 1888 Gowers stated that convulsions shifting from the first to the second side were characteristic of occlusions of the superior longitudinal sinus. However, Macewen (1893) states that there are no pathognomonic symptoms of thrombosis of the longitudinal sinus.

Edema over the scalp occurs as a sign of thrombosis of this sinus in a great many cases. Irish (1943) states that the scalp is edematous and the veins are engorged. Spiegel and Sommer (1944) state that the edema usually occurs over the vertex and that the frontal and parietal veins are dilated. In

one of Doyle's cases the patient had developed edema of the eyelids and dilated frontal veins. In a case reported by Bailey and Hass in 1927 there was dilatation of the scalp veins on the right. Edema might be looked upon as an expected finding where thrombosis of this sinus occurs if one considers the anatomic connections which the sinus has with the scalp veins through the route of the parietal emissary vein.

Typical convulsions, as stated above, were said by Gowers to occur in superior sinus thrombosis. In 1938 Irish stated that convulsions are frequent and may be of the Jacksonian type. In two of the three cases reported by Lillie in 1927 convulsions occurred, but only when the patient was in extremis. In two of Doyle's cases there were convulsions, but only one of the typical Jacksonian type.

Nielsen and Courville in 1938 reported on six cases of superior longitudinal sinus thrombosis, four of them involving one of the lateral sinuses. One case showed generalized convulsions. Three showed the typical described syndrome of alternating Jacksonian convulsions, and two cases showed no evidence of any convulsions, local or generalized.

The inconsistency of convulsions in thrombosis

of the superior longitudinal sinus is explained by Martin (1941). He states that convulsions are associated with thrombosis or obstruction of the cerebral veins draining into the sinus and that thrombosis of the superior sinus can and does occur without affecting the superior cerebral veins which drain into it. However, if a thrombus occludes the whole cross-section of the sinus opposite the entrance of a vein, or if it is situated in the trough of the sinus or extends down into the trough, it may obstruct one or more of these veins. Thrombosis of the affected vein is then more likely to occur, giving rise to irritation or paralysis of the corresponding area of the cortex, which, if the veins of the precentral cortex are involved, may be ushered in with convulsions. Irish (1938) states that spastic paraplegias with bladder symptoms, due to softenings in both paracentral or leg motor areas, are rare in involvement of the superior longitudinal sinus.

Eye changes may occur in thrombosis of the superior longitudinal sinus, but according to Benedict (1930) and Lillie (1930) they are not characteristic nor of diagnostic importance, although Fremming and Wenthner (1938) state that choked disc is frequently

observed and may be the only symptom present in primary venous thrombosis.

The Lateral Sinus. Pain about the ear is an almost constant finding in thrombosis of this sinus, according to Mueske (1930).

Tenderness and swelling over the mastoid are reported as fairly outstanding symptoms of lateral sinus thrombosis. Macewen (1893) states edema in that area occurs in about one-half of the cases of sinus thrombosis, but may occur in its absence, being due then to inflammation of the mastoid process, especially its superficial parts. He states that the edema, even in presence of lateral sinus thrombosis, is due to the osteitis in the mastoid process and the blocking of veins, although occlusion of the sinus itself may augment it.

There may be pain in the neck, tenderness along the course of the internal jugular vein, and even neck rigidity (Spiegel and Sommer 1944, Peters 1933, McDougall 1938, Yoskin 1939, Potts 1932, Ersner and Myers 1936). Peters states that pain in the back of the neck was one of the earliest symptoms noted. The internal jugular vein may be replaced by a tough band along the anterior border of the sternocleido mastoid

muscle. McDougall believes that the presence of adenitis or tenderness on palpation along the course of the internal jugular vein from the bulb downward is of confirmatory value. Careful evaluations must be made of cervical rigidity if it is present. It may be due to traumatism of the sternocleidomastoid muscle, or cervical adenitis, especially if there has been sinusitis, tonsillitis, or pharyngitis. Muecke, reviewing 100 cases of infective lateral sinus thrombosis, discovered that the finding of redness or edema of the posterior part of the meatal wall, near the drum, was present in 70 percent of the cases and was a valuable sign of mastoid disease.

Ocular symptoms of lateral sinus thrombosis include tortuosity of the retinal veins and papilledema of varying degrees (Potts 1932; Coates, Ersner and Persky 1939; Lillie 1930; McDougall 1938; Swift 1937; Tobey 1927; Friesner 1941; Benedict 1930; Muecke 1930). In addition, Aring and Merritt (1935) reported dilatation of the pupil on the opposite side as the thrombosis in 7.4 percent of the cases reviewed by them. They also reported the loss of pupillary reaction to light in 9.3 percent in which the reaction of light was recorded. Choked disc was present in 10 percent

muscle. McDougall believes that the presence of adenitis or tenderness on palpation along the course of the internal jugular vein from the bulb downward is of confirmatory value. Careful evaluations must be made of cervical rigidity if it is present. It may be due to traumatism of the sternocleidomastoid muscle, or cervical adenitis, especially if there has been sinusitis, tonsillitis, or pharyngitis. Muecke, reviewing 100 cases of infective lateral sinus thrombosis, discovered that the finding of redness or edema of the posterior part of the meatal wall, near the drum, was present in 70 percent of the cases and was a valuable sign of mastoid disease.

Ocular symptoms of lateral sinus thrombosis include tortuosity of the retinal veins and papilledema of varying degrees (Potts 1932; Coates, Ersner and Persky 1939; Lillie 1930; McDougall 1938; Swift 1937; Tobey 1927; Friesner 1941; Benedict 1930; Muecke 1930). In addition, Aring and Merritt (1935) reported dilatation of the pupil on the opposite side as the thrombosis in 7.4 percent of the cases reviewed by them. They also reported the loss of pupillary reaction to light in 9.3 percent in which the reaction of light was recorded. Choked disc was present in 10 percent

of Tobey's patients, and Lillie (1930) estimated that this was a finding in about one-third of the cases. Friesner (1941) concludes that there has been no firm basis as to the cause of papilledema in sinus thrombosis and offers three causes for consideration: (1) Stasis; (2) Increased intracranial pressure; and (3) Toxic state. He does not believe that the toxic state of the patient is the cause, for in some cases he reviewed the papilledema receded when the patient was quite ill. He believes that inflammation with its attendant edema and infiltration may be an important factor in the development of papilledema. Lillie (1930) states that in his experience in sinus thrombosis choked disc is more common after his operative procedure on the sigmoid sinus or jugular vein. He explains this as being due to the presence of back pressure occurring before the compensatory mechanism has been established. Benedict states that choked disc may occur in diseases of the mastoid without sinus involvement. With this knowledge he states that the only conclusion that can be reached regarding the finding of papilledema is that some intracranial involvement has taken place, the nature of which is not manifest. Hyperemia of the nerve head

and dilatation of the veins of the fundus are a more common finding than choking of the disc (Lillie 1930).

Paralysis of the abducens nerve is frequently found (Stone and Berger 1936). Greenfield (1934) give an extensive review of the anatomy of the sixth nerve and reports a case of bilateral paralysis consequent to thrombosis in the lateral sinus. He believes the paralysis is secondary to the spread of the thrombotic process into the petrosal sinus, causing possible congestion, edema, and swelling of the dura along the course of the sixth nerve. He further states that whether one or both nerves will be involved depends on the extent of the thrombotic process in the petrosal sinuses. Lillie believes that choking of other nerves than the optic may result from lateral sinus thrombophlebitis. He states that he has seen what he believe to have been a choked eighth nerve, with loss of function of the vestibular and the auditory branch.

The Cavernous Sinus. While it is probably true that the local symptoms of cavernous sinus thrombosis center for the most part about the eye, it must be remembered that involvement of this sinus may occur from any of the three main routes discussed above under Pathogenesis. If the middle or posterior route



nerve.

- (b) Some degree of inhibition of the motility of the eye, ranging from strabismus to complete ophthalmoplegia (Turner and Reynolds 1931).

According to Roth (1904) swelling of the eyelids, ecchymosis, and edema of the skin and conjunctiva on the affected side are the first symptoms to make their appearance. Benedict (1930) says that swelling of the eyelids and proptosis in a septic case are among the first symptoms presenting themselves, but that paralysis of the ocular muscles is also an early sign. According to Turner and Reynolds (1931) involvement of the oculomotor nerve is most evident clinically because of the pupillary changes consequent to its involvement. They state that the longer intraorbital course of the branch of this nerve to the iris exposes it readily to the effect of orbital edema. Eagleton (1926), quoted by Turner and Reynolds (1931), has stated that involvement of the ocular nerves is often the first clinical sign in sinus thrombosis which has been infected from behind. In this case the pathological process extends from the interior of the sinus to its dural wall, involving the nerves before the thrombotic process has extended forward into the

ophthalmic system.

The Petrosal Sinuses. Thrombosis of the petrosal sinuses is seldom involved alone so that local symptoms pointing to involvement of this sinus are marked by the symptoms of thrombosis of the lateral or cavernous sinus (Wilson 1940).

However, as related above, Greenfield (1934) has stated that involvement of the petrosal sinuses in thrombotic processes leads to paralysis of the sixth nerve. Shemeley (1922) reported a case in which he believed that the superior petrosal sinus was initially thrombosed, the most frequently observed symptoms being:

- (1) Swelling of the veins in the temporal region
- (2) Thrombosis of the retinal veins,
- (3) Attacks of epistaxis, and
- (4) Epileptiform seizures.

Brown and Bowman (1933) state that pain over the course of the fifth nerve would lead them to suspect inferior sinus thrombosis. Foster (1932) pointed out the close relation of the gasserian ganglion to the superior petrosal sinus and discussed the pathways of infection to the sinus. He agrees with the symptoms presented by Shemeley as indicating thrombosis of the

superior petrosal sinus.

Symptoms Secondary to Sinus Thrombosis

The character of the local venous lesion is of importance from the standpoint of the changes resulting in the meninges and brain. Many of the temporary lesions causing symptoms, but not found at autopsy are undoubtedly of the character of a localized edema which clears up in the course of a few days (Nielsen and Courville 1937). If the thrombus becomes infected, meningitis may result if the infection extends into the subarachnoid space. If venous occlusion results in infarction or red softening, the infarction may become infected to yield an abscess. These abscesses may be single or multiple and occur in almost any part of the brain (Nielsen and Courville 1937). The most common sequelae of cerebral sinus thrombosis are:

- (1) meningitis,
- (2) brain abscess, and
- (3) cerebral hemorrhage.

These conditions may produce symptoms which can cloud those produced by sinus thrombosis. Therefore, a brief consideration of the symptoms which are caused by these three complications seems to be in order here. A close consideration of these symptoms, when occurring

in a case of sinus thrombosis, may serve to aid in detecting their presence.

Symptoms of Meningitis. Apart from the intense headaches and high, more or less continuous fever, the meningitis presents multiple symptoms (Swift 1927). According to Spiegel and Sommer (1944), the infiltration about the nerve fibers as they cross the subarachnoid space leads to hyperirritability of the sensory nerves and their reflex arcs. Results of this are stiffness of the neck, positive Kernig, increased reflexes, and hypersensitiveness to noise and pain. The pupils may be unequal in size (Spiegel and Sommer 1944) but are usually equally dilated (Swift 1927). There is usually no change in the optic disc until late, after the development of increased intracranial pressure (Swift 1927).

The pulse may be slow early (Spiegel and Sommer 1944) from increased intracranial pressure, but later becomes rapid due to paralysis of the Vagus nerve (Swift 1927; Spiegel and Sommer 1944). The spinal fluid shows most commonly increased pressure with clear to purulent appearance. The cell count is increased usually by the polynuclear cells, the protein is increased, and the sugar decreased (Spurling 1944).

Symptoms of Abscess Formation. According to Nielsen and Courville (1937), when a brain abscess develops in the presence of sinus thrombosis, it is extremely difficult, if not impossible, for any one to absolutely determine the fact without the operative findings of a surgeon. However, Macewen (1893) says that when infective sinus thrombosis is present, together with brain abscess, symptoms of the former mask those of the latter. Spiegel and Sommer (1944) divide symptoms of cerebral abscess into four stages:

- (1) The Initial Stage - lasting from two to four weeks and characterized by headache, projectile vomiting, and leukocytosis in the blood. There may be convulsions.
- (2) The Latent Stage - corresponding to incapsulation of the abscess and characterized by regression of all symptoms.
- (3) The Manifest Stage - in which focal symptoms and eventually symptoms of meningitis appear.
- (4) The Terminal Stage - in which there is further increase in the intracranial pressure, associated with encephalitis and meningeal symptoms.

Symptoms indicating the different parts of the brain which are involved by the abscess, i.e., localizing symptoms, are a subject in themselves and cannot be discussed here.

Symptoms of Hemorrhage. The onset of cerebral hemorrhage may occur with convulsions and/or unconsciousness (Aring and Merritt 1935). Vomiting and a severe headache are also reported by them as symptoms common to cerebral hemorrhage. They report that stiffness of the neck was an important sign in 55.1 percent of the cases which they reviewed. The presence and appearance of the spinal fluid are the two most significant findings. Pressure greater than 400 mm. and a frankly bloody fluid is indicative of cerebral hemorrhage (Aring and Merritt 1935). Leadingham (1931) lists the symptoms of subarachnoid hemorrhage as follows:

- (1) Meningeal irritation.
- (2) Choked disc.
- (3) Leukocytosis.
- (4) Evenly distributed red cells in the spinal fluid.

#### DIAGNOSIS OF CEREBRAL SINUS THROMBOSIS

From the preceding discussion of the symptoms (both general and local) of sinus thrombosis, it can be ascertained that the general symptoms of this disease can be of little value in making a positive diagnosis, inasmuch as they may serve to indicate meningitis, abscess of the brain, or hemorrhage, as well as the presence of a thrombosed sinus. In cases of infection about the face or neck it will be hard to distinguish sinus thrombophlebitis from meningitis unless there is a breaking down of the clot, giving rise to a septecemia and metastatic abscess formation (Wilson 1940). While it is true that the sudden development of general cerebral symptoms in a condition in which a sinus thrombosis is likely to occur may lead one to suspect the sinus involvement, there is likely to be considerable confusion attending the diagnosis. Local signs and symptoms of sinus thrombosis may aid in organizing the confusion, but unless there is complete blocking of the sinus, these valuable local signs and symptoms may be minimal. Therefore, it must be agreed that a diagnosis of cerebral sinus thrombosis, in most cases, can only be made after a careful consideration of the symptoms, especially the local

ones, in relation to the circumstances surrounding the patient's illness, and that in some cases positive diagnosis cannot be determined.

#### The Superior Longitudinal Sinus

The diagnosis of thrombosis in this sinus may be extremely difficult, as illustrated by the four cases presented by Doyle (1927). The onset of apathy and convulsions of the alternating Jacksonian type are usually stated as being pathognomonic of superior sinus thrombosis. However, Nielsen and Courville (1937) state that the symptom of alternating Jacksonian convulsions may occur in either lateral or superior sinus thrombosis or may be absent in both of them. They state that in cases of otogenous thrombosis the symptoms of involvement of the superior sagittal sinus are indistinguishable from those of lateral sinus thrombosis.

How, then, can one logically diagnose this condition? Martin (1941) says that the principles for the diagnosis of a clot in the superior longitudinal sinus are the coexistence of signs and symptoms of increased intracranial pressure with local signs of cerebral venous thrombosis. If the two above-mentioned requirements are fulfilled, if there is



no severe heart disease to provide a source for emboli, and if the blood pressure is normal, the presence of venous thrombosis may be assumed. If the patient has experienced some disease condition with which thrombosis in this sinus is known to be a likely condition, then the diagnosis is all the more plausible. Martin (1941) says that cerebral tumor is the most likely condition to cause confusion and that it may be hard to exclude it at the beginning. A little blood in the cerebrospinal fluid is strongly in favor of thrombosis, while an increase in protein of the fluid favors tumor. Furthermore, Martin states that if the symptoms merely indicate thrombosis of a single cerebral vein, the diagnosis can be carried no further; but if there is evidence of two or more veins being obstructed, especially if they are on opposite sides, there is a strong presumption that the obstructions are being caused by a thrombus in the sinus.

Following a study of longitudinal sinus thrombosis from all causes, Doyle (1927), of the Mayo Clinic, has drawn the following conclusions on diagnosis:

- (1) In the absence of meningitis, the early onset of apathy or stupor in a patient

with evidence of thrombosis of the transverse sinus secondary to suppurative otitis media generally indicates infectious thrombosis of the superior longitudinal sinus by retrograde extension, especially if associated with choked disc and convulsions.

- (2) When the probable presence of tumor or of inflammatory disease can be excluded, Jacksonian seizures, showing progression from one foot to the other, or beginning in the foot and extending to involve the homolateral upper extremity, suggest impairment of the circulation of the cerebral veins and probably thrombosis as well.

Thus, from the above, it seems feasible to reach the same conclusion as Martin: that by no means are all cases of superior sinus thrombosis recognizable in the present state of our knowledge, and that it is possible for a large thrombus to exist in the sinus without giving rise to any clinical symptoms.

#### The Lateral Sinus

As has already been stated, thrombosis of this sinus occurs most often as a complication of middle ear disease. Muecke (1930) says that when an otitis

media patient is found to be abnormally ill with nothing to account for it, lateral sinus infection should be suspected. If, on examination, a red edematous spot is found in the meatus, he advises immediate operation. He states that the accompaniment of deep mastoid tenderness, herpes and sordes, a swinging temperature and auditory pain should complete the early diagnosis. He considers herpes and sordes about the lips and gums to be a very early indication of sinus involvement. Macewen (1893) divided the diagnosis of lateral sinus thrombosis into three stages, depending upon the pathogenesis of the clot formation:

- (1) When the thrombosis was partial or complete.
- (2) When disintegration and absorption of the clot had commenced.
- (3) Where there was excessive absorption of the clot.

In stage one there were slight rigors, low fever, headache limited to the affected side, and edema and slight tenderness below the tip of the mastoid process. In stage two the signs of sepsis increased, with the temperature showing distinct fluctuation, and the rigors becoming more frequent. In stage three there were marked fluctuations of the temperature,

going as high as 104 degrees, with severe headaches and marked tenderness over the posterior triangle of the neck and along the jugular vein. Macewen (1893) places great importance on the temperature curve as an aid to diagnosis. Sullivan (1930) states that the temperature can be a useful guide as to the extent of middle ear disease, and that when it is between 101° and 102° the infection has advanced beyond the middle ear. The extreme variations in temperature may be illustrated by the cases of Kopetzky (1942) and Souper (1933). In Kopetzky's case the temperature showed eleven sharp rises in 67 days with normal temperature between, while in Souper's case the temperature never rose above 100.7°. Chase (1931) says that in any patient with acute suppurative otitis media and mastoiditis, that either before or after operation, while pursuing a fairly average course, the patient suddenly has a rigor followed immediately by an abrupt and marked rise in temperature with a positive blood culture, tenderness about the mastoid and along the anterior border of the sternocleidomastoid muscle, and a metastatic inflammation, the diagnosis of lateral sinus thrombosis should offer no difficulty Hamrick (1929) agrees that the typical cases are

rather easy to diagnose, but that the clinical picture in a typical case may be of no use. He relies on the presence of a positive blood culture (although he says that a negative one does not rule it out), a leukocyte count of over 20,000 and a step-like rise in the pulse rate to aid in making his diagnosis. In 1925 Tobey and Ayer published an article on a technique by which it could be determined on which side thrombosis of the lateral sinus existed. In this procedure, called the Tobey-Ayer test, a needle is introduced into the spinal canal and connected with a manometer. The jugular veins are then compressed alternately and the effect noted by the raising of the fluid in the manometer. In a typical case of lateral sinus thrombosis there is a prompt and rapid rise in fluid pressure to twice or three times the initial reading when the internal jugular vein draining the normal sinus is compressed. Pressure over the vein draining the thrombosed sinus causes either no rise or, more commonly, a slow rise of only 10 mm. to 20 mm. in the manometer. The value of this test is related by Johnson (1929), Lindsay (1942), Tobey (1927), McDougall (1938), and Kopetzky (1928). It was positive in every case in which

it was tried in Lindsay's series, and in Johnson's case, which had mild ear symptoms and no frank chill at any time, it established the diagnosis. However, Stauffer (1928), Woodward (1930), Wilder (1929), and K&opetzký (1928) all report cases in which the test gave confusing results. Wilder says that in most cases the test is absolutely diagnostic, but should be considered and fitted into the other clinical findings.

#### The Cavernous Sinus

The clinical picture of cavernous sinus thrombosis is most often considered to consist of exophthalmus, papilledema, septic temperature, and ocular muscle paralysis. Eagleton, quoted by Schall (1941), proposed the following diagnostic criteria:

- (1) A known site of infection.
- (2) A blood stream infection.
- (3) Early but slight signs of obstruction such as temporary fullness of the veins of the retina, the Crowe-Beck sign of filling of the retinal veins on compression of the carotid artery and jugular veins on the affected side, and temporary ocular edema from continued pressure on the neck.

- (4) Neighborhood symptoms from involvement of the nerves in the sinus, by inflammatory edema or direct pressure, causing paralysis or paresis of the third, fourth, and sixth nerves, or paresthesia or anesthesia in the first branch of the fifth nerve, manifested by transient or permanent diplopia, herpes of the face and lips and in the teeth or supra, or intra-orbital regions or behind the eye.
- (5) Neighborhood abscess in the adjacent soft parts secondary to a retrograde septic thrombophlebitis, extending from the cavernous sinus into the smaller venous radicles which normally empty their blood into the cavernous sinus or its immediate accessories.
- (6) Symptoms of complicating disease, i.e., headache and papilledema from serous meningitis of the basal cisterna.

The clinical picture in these cases is uniformly terrifying (Roth 1904). There appears evidence of an overwhelming systemic infection and proptosis of first one eye and then the other, accompanied by immobility

of the eyeball, and followed by evidence of meningitis. However, according to Connell and Trowbridge (1941), where this full-blown picture occurs the patient is beyond medical or surgical aid. Therefore, the importance of early detection should be strongly emphasized. What things should one look for as early signs of thrombosis involving this sinus? Unilateral periorbital swelling or conjunctival edema is usually the first warning in the early stage of the infection, according to Connell and Trowbridge (1941) and Roth (1904). The disease may then follow one of two courses: The septic form, characterized by a fulminating course and usually ending in an early death; or the pyemic form, which is characterized by remittant temperature, chills, lassitude, headaches, and often metastatic involvement. Benedict (1930) states that paralysis of the ocular muscles is an early sign. Connell and Trowbridge (1941) state that the dilatation of the retinal veins is probably the most important single early finding, and that papilledema is rare, only occurring late in the course of the disease. At any rate, one concludes that in close extra- and intra-ocular examination of the eyes lies the hope for early diagnosis.



The importance of the middle route of infection of this sinus is brought out in the case presented by Keegan and Ash (1934). In their case the ophthalmic vein was not involved at all. However, there was paralysis of the third, fourth, and sixth cranial nerves, and the first ophthalmoscopic examination recorded stated that the retinal veins were engorged. Later on the muscular paralysis disappeared, but the engorgement of the veins was supplemented by beginning papilledema.

#### The Petrosal Sinuses

Diagnosis of thrombosis occurring in these sinuses is rarely made (Brown and Bowman 1933). However, Shemeley (1922) says that, given a case presenting the three cardinal symptoms, (1) trifacial neuralgia, (2) pyemic temperature, and (3) the presence of a chronic purulent otitis media, with a discharge having the odor of dead bone, the diagnosis of primary thrombosis of the superior petrosal sinus of otitic origin is justified. Brown and Bowman (1933) state that in the course of a suspected sinus phlebitis after the jugular vein has been ligated and you have satisfied yourself that there is no pathology in the sigmoid or beyond, and the septic symptoms

continue, then one is justified in considering petrosal involvement.

#### CONCLUSIONS

(1) Local signs of sinus thrombosis are more important in diagnosis than general cerebral signs.

(2) Thrombosis of the superior longitudinal sinus may exist without presenting any clinical diagnostic symptoms.

(3) The classical symptoms of alternating Jacksonian convulsions, beginning in one foot and extending to involve the homolateral extremity, then involving the opposite extremity, are not pathognomonic of superior longitudinal sinus thrombosis.

(4) Accurate diagnosis of superior longitudinal sinus thrombosis is most often impossible, but the condition may be suspected when a patient in the proper age group develops cerebral symptoms in the course of a disease known to predispose to sinus thrombosis.

(5) Lateral sinus thrombosis most often is a complication of middle ear disease.

(6) The swinging, remittant type of temperature and the occurrence of rigors in a case of otitis media should lead one to suspect thrombosis of the

lateral sinus.

(7) The Tobey-Ayer test is a most valuable and accurate test to determine the presence of a complete thrombus in the lateral sinus.

(8) The examination of the eye constitutes a valuable aid to diagnosis of lateral and cavernous sinus thrombosis, and the early indication of thrombosis involving the latter may be arrived at from its examination.

(9) Cavernous sinus thrombosis may occur without involvement of the ophthalmic vein.

(10) There are no definite clinical diagnostic criteria for thrombosis of the petrosal sinuses.

(11) A thorough knowledge of the anatomy and relationships of the intracranial structures is necessary for an intelligent consideration and understanding of the pathogenesis and diagnosis of cerebral sinus thrombosis.

- Abercrombie, John: Pathological and Practical Researches on Diseases of the Brain and the Spinal Cord.  
Lee and Blanchard, Philadelphia, 1843.
- Alden, A. M.: Unusual Cases of Lat. Sinus Throm.  
Ann. of Otol., Rhin. and Laryng.  
38:455-564, 1929
- Aring, D. C. and Merritt, H. H.: Diff. Diag. of Cerebral Hemorrhage; Clinical and Pathologic Study of 245 Cases.  
Arch. Int. Med.  
56:435-456, 1935
- Babbitt, J. A.: Lat. Sinus Thrombosis Presenting Unusual Variations: Streptococcemia, Transfusion Recovery.  
Ann. Otol., Rhin., Laryng.  
34:505, 1926
- Baer, L.: Case of Lat. Sinus Thrombosis Representing Some Interesting Features.  
Laryngoscope  
41:169-173, 1931
- Bailey, Orville T. and Hass, George M.: Superior Longitudinal Sinus Thrombosis  
Brain  
60:293, 1937
- Ballance, Charles A., and Hobhouse, Neil: A Case of Septic Thrombosis of the Left Sigmoid, Left Cavernous, and Left Inferior Petrosal Sinuses With a Suggestion for Treatment in Future Cases.  
Ann. of Otol., Rhin., and Laryng.  
Dec. 1912: 942-952, 1912
- Benedict, W. L.: Cranial Sinus Thrombosis; Ophthalmologic Aspects.  
Surg., Gyne., and Obstet.  
52: 464-470, 1930
- Brown, J. M., and Bowman, R. J.: Case Report of Phlebitis of the Lateral Sinus, Inferior Petrosal

- Sinus and Opposite Lateral Sinus With Post-Mortem Examination.  
Proc. West. Sect. Am. Laryng, Rhin, and Otol Soc, 1933.
- Brunner, Hans: Postoperative Sinus Thrombosis  
Archives of Otolaryngology  
33:509, 1941.
- Chase, S. B.: Unusual Series of Lateral Sinus Cases.  
Ann. Otol. Rhin., and Laryng.  
40:274-288, 1931
- Cheatle, Arthur: Article on Mastoid Vein  
J. Lary., and Otol.  
40:633, 1927
- Coates, G. M., Ersner, M. S., and Persky, A. H.: Lat. Sinus Thrombosis with Review of Literature.  
Ann. Otol., Rhin., and Laryng.  
43:419-440, 1934
- Connell, Evan S., and Trowbridge, Barnard C.: Cavernous Sinus Thrombophlebitis. The Use of Serum and Chemotherapy in its Management.  
J. of the Mo. State Medical Ass'n.  
38:320, 1941
- Doyle, J. B.: Obstruction of Long. Sinus.  
Neurol and Psychiat.  
18:374-382, 1927
- Eagleton, Wells P.: Cavernous Sinus Thrombophlebitis.  
New York, 1926.
- Ehlers, Hertha, and Courville, Cyril: Thrombosis of Int. Cerebral Veins in Infancy and Childhood  
Review of Literature and Report of Five Case  
Jrl. of Pediatrics  
8:600, 1939
- Ersner, M. S., and Myers, D.: Outstanding Signs and Symp; Merits and Demerits of Int. Jugular Ligation in Treatment of Lateral Sinus Thrombosis.  
Penn. M.J.  
39:579-585, 1936

- Dusch, Th. von: Thrombosis of the Cerebral Sinuses.  
Translated by George Whitley in Selected  
Monographs  
The New Sydenham Society, London, 1861.
- Fenton, R. A.: Lateral Sinus Thrombosis With Delayed  
Metastasis; Case.  
Ann. Otol., Rhin., and Laryng.  
36:675-677-1927
- Foster, H.: Occurrence of Superior Petrosal Sinus  
Thrombophlebitis.  
J. Am. Inst. Homeop.  
25:841-844, 1932.
- Fremming, Kurt H., and Winther, K.: Intracranial Ven-  
ous Sinus Thrombosis.  
Acta psychiatrica et neurologica  
13:271, 1938.
- Friesner, I.: Analysis of Ocular Fundus Changes in  
Otitic Thrombosis.  
Ann. Otol., Rhin., and Laryng.  
50:32-37, 1941.
- Furstenberg, A. C.: Panel Discussion: Septic Throm-  
bosis of Sigmoid Sinus; Routes of Infection;  
Anatomic Variations of Sinus and Effects of  
These Variations on Diagnosis.  
Tr. Am. Acad. Ophth.  
42: 424-431, 1930.
- Garlichs, R. W., and Griffith, J. Q.: Lymphatic Ab-  
sorption from Auditory Bulla of Rat., with  
Special Reference to Lateral Sinus.  
Arch. Otolaryng.  
36: 226-231, 1942.
- Greenfield, S. D.: Etiology and Pathology of Paraly-  
sis of Abducens Nerve Associated with Sinus  
Thrombosis; Case of Lateral Sinus Thrombosis  
and Bilateral Paralysis of Abducens Nerve;  
Operation and Recovery.  
Arch. Otolaryng.  
19:336-341, 1934.
- Gowers, W. R.: A Manual of Diseases of the Nervous

System.

P. Blakiston, Son and Co.  
1012 Walnut St., Philadelphia, 1898.

- Hamrick, D. W.: Lateral Sinus Thrombosis; Review of Literature and Report of Four Cases.  
New Orleans Med. and Surg. J.  
82:130-135, 1929.
- Harris, H. A.: Clinical Anatomy of Veins, with Special Reference to Spinal Veins  
Brain  
64:291-300, 1942.
- Hassin, G. B.: Abscess and Thrombosis of Superior Longitudinal Sinus; Clinicopathologic report of Case.  
Arch Neurol. and Psychiat.  
29:359-367, 1933.
- Hemmeon, J, A. M.: Inferior Petrosal Sinus Thrombosis.  
Jour. Laryng., and Otol.  
June 1922:281-284, 1922.
- Hirsch, E. F.: Symmetric Hemorrhagic Necrosis of Cerebrum Following Primary Thrombosis of Superior Longitudinal Sinus.  
Arch. Path.  
26:210-215, 1938.
- Irish, Cullen Ward: Cavernous Sinus Thrombosis  
Annals of Otol., Rhin., and Laryng.  
47:411-35, 1943.
- Irish, Cullen Ward: Longitudinal Sinus Thrombosis  
Ann. Otol., Rhin., and Laryng.  
47:402-410, 1938.
- Johnson, G. E.: Unusual Case of Lateral Sinus Thrombosis.  
Laryngoscope  
39:640-647, 1929.
- Keegan, J. J., and Ash, W. E.: Bilateral Cavernous Sinus Thrombophlebitis Without Involvement of the Ophthalmic Vein. Report of a Case.  
Arch. of Ophthalmology  
12:72-80, 1934.

- Kopetzky, S. J.: Observation on Diagnosis of Lateral Sinus Thrombosis Contradictory to Results of Tobey and Ayer.  
Arch. Otolaryng.  
7:532-533, 1928.
- Kopetzky, S. J.: Purulent Otitis Media, Mastoiditis, Sinus Thrombosis and Suppuration of Petrous Pyramid; Summaries of Bibliographic Material Available in the Field of Otolaryngology.  
Arch. Otolaryng.  
35:115-131, 1942.
- Leadingham, R. S.: Superior Longitudinal Sinus Thrombosis and Subarachnoid Hemorrhage.  
Ann. Int. Med.  
4:1584-1588, 1931.
- Lillie, H. L.: Thrombosis of Superior Longitudinal or Straight Sinus by Extension from Lateral Sinus; Report of 3 Cases.  
Tr. Am. Laryng. Rhin. and Otol. Soc.  
33:381-386, 1927.
- Lillie, H. L.: Panel Discussion: Septic Thrombophlebitis of Sigmoid Sinus; Papilledema, Brain Abscess and Meningitis Complicating Thrombophlebitis.  
Tr. Am. Acad. Ophthalmology.  
42:438-442, 1930.
- Lindsay, J. R.: Thrombosis of Intracranial Venous Sinuses in Middle Ear Suppuration.  
Ill. M. J.  
81:467-474, 1942.
- MacDonald, P.: Spontaneous Rupture of Thrombosed Lateral Sinus.  
Brit. M. J.  
2:866, 1933.
- Macewen, William: Pyogenic Infective Diseases of the Brain and Spinal Cord.  
MacMillan and Company, New York, 1893.
- MacGregor, A. R., and Smith, A. B.: Sagittal Sinus Thrombosis and Subdural Abscess Following



- Nasal Sinusitis; Case.  
J. Laryng., and Otol.  
50:600-603, 1935.
- Martin, J. P.: Thrombosis of Superior Longitudinal Sinus Following Childbirth.  
Brit. M. J.  
2:5370540, 1941.
- McDougall, J. C.: Diagnosis and Treatment of Lateral Sinus Thrombosis.  
South Surgeon  
7:333-337, 1938.
- Moorhead, Robert L.: Suppuration of the Petrous Pyramid.  
Arch. Otolaryng.  
32:845, 1932.
- Muecke, F.: Early Diagnosis of Infective Lateral Sinus Thrombosis.  
Brit. M. J.  
2:465-466, 1930.
- Nielsen, J. M., and Courville, C. B.: Intracranial Complications of Otogenous Thrombosis of Lateral Sinus.  
Ann. Otol., Rhin., and Laryng.  
46:13-38, 1937.
- Peters, E. A.: Treatment of Lateral Sinus Thrombosis.  
J. Laryng. and Otol.  
48:200-203, 1933.
- Potts, J. B.: Lateral Sinus Thrombosis.  
J. A. M. A.  
98:379-384, 1932.
- Richards, John D.: Inferior Petrosal Sinus Thrombosis  
Am. Jour. of Med. Sc.  
1905. 129:261-266.
- Rosenwasser, Harry: Differential Diagnosis Between Thrombosis of the Lateral Sinus and Acute Bact. Endocarditis.  
Arch. Otolaryng.  
26:668-686, 1928.

- Roth: Cavernous Sinus Thrombosis Involvement of Nerves  
New York Med. Jourl.  
79:394-396, 1904.
- Rott, O. M.: Why Ligate Jugular Vein in Cases of Lateral Sinus Thrombosis?  
Arch. Otolaryng.  
14:272-281.
- Schall, LeRoy A.: Treatment of Septic Thrombophlebitis of the Cavernous Sinus.  
Journal of the American Medical Assoc.  
117:581, 1941.
- Shemeley, W. G., Jr.: Inferior Petrosal Sinus Thrombosis. Primary.  
Ann. of Otol., Rhin., and Laryng.  
Sept. 1922; 869-877.
- Souper, H. R.: Lateral Sinus Thrombosis With Unusual Termination.  
J. Laryng. and Otol.  
48:338-340, 1933.
- Spiegel, E. A., and Sommer, I.: Neurology of the Eye, Ear, Nose, and Throat.  
Grune and Stratton, New York, 1944.
- Spurling, Glen L.: Practical Neurological Diagnosis.  
Chas. C. Thomas, Balt., Md., 1944.
- Stauffer, N. P.: Difficulties in Diagnosis of Lateral Sinus Thrombosis.  
Ann. of Otol. Rhin., and Laryng.  
37:890-895, 1928.
- Stone, F. E., and Berger, M. D.: Retrograde Sinus Thrombosis Complicating Primary Thrombosis of the Jugular Vein.  
Arch. of Otolaryngology  
24:141, 1936.
- Sullivan, J. J., Jr.: Thrombosis of the Lateral and Cavernous Sinuses.  
Penn. M.J.  
33:373-378, 1930.

- Swift, G. W.: Differential Diagnosis Between Septic Meningitis, Brain, and Lateral Sinus Complicating Mastoiditis.  
Ann. Otol., Rhin., and Laryng.  
36:669-674, 1927.
- Tobey, G. L., and Ayer, James B.: Dynamic Studies in Lateral Sinus Thrombosis.  
Arch. Otolaryng.  
2:50, 1925.
- Tobey, G. L., Jr.: Diagnosis of Lateral Sinus Infection.  
Atlantic M. J.  
30:759-762, 1927.
- Turner, A. Logan, and Reynolds, F. Esmond: Intracranial Pyogenic Diseases.  
Oliver and Boyd  
Edinburgh: Tweeddale Court  
London: 33 Paternoster Row, E.C., 1931.
- Vail, H. H.: Anatomic Studies of Dorello's Canal.  
Laryngoscope  
32:569, 1922.
- Waltner, J. G.: Anatomic Variations of Lateral and Sigmoid Sinuses.  
Arch. Otolaryng.  
39:307-312, 1944.
- Wieder, H. S.: Interesting Case of Lateral Sinus Thrombosis.  
Laryngoscope.  
39:808-812, 1929.
- Wilson, Kinnier S. A.: Neurology.  
Edited by A. Ninian Bruce.  
Williams and Wilkins Company, Baltimore, 1940
- Wilson, W. F.: Treatment of Lateral Sinus Thrombosis.  
J. Laryng. and Otol.  
48:145-155, 1933.
- Wolf, Jonas W.: Thrombosis of the Cavernous Sinus With Hemolytic Streptococcic Bacteremia: Treatment by Intravenous Injection of Sulfadiazine and

Penicillin, with Recovery.  
Arch. of Otolaryngology.  
4 :33, 1942.

Woodward, F. D.: Lateral Sinus Phlebitis and Throm-  
bosis. Diagnosis and Treatment.  
Tr. Am. Laryng. Rhin., and Otol. Soc.  
36: 480-483, 1930.

Yoskin, J. C.: lications of Infections  
of Temporal Bone and Paranasal Sinuses Sum-  
mar of 20 Years (1919-1938) Experience.  
Arch. Otolaryng.  
30:360-388, 1939.

Ziegelman, E. F.: Surgical Importance of the Mastoid  
Vein in Infected Lateral Sinus Thrombosis.  
Arch. of Otolaryng.  
18:298-309, 1933.