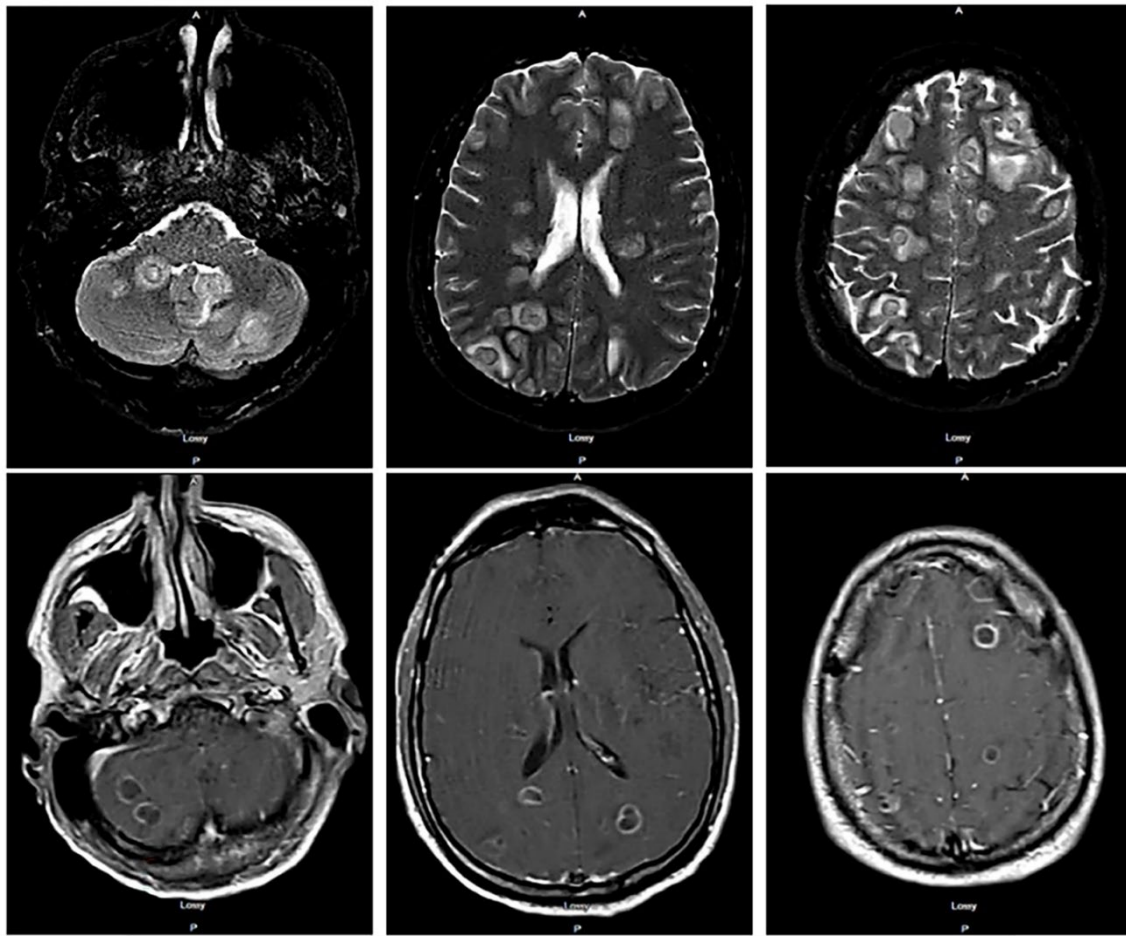


T2



T1 with Contrast

Figure 1: MRI of a 34-year-old patient with diffuse ring-enhancing lesions of the brain. T2 weighted (top) and T1 with contrast (bottom) MRI images of septic emboli